




3 1761 06705412 2

Ex  Libris  
Oskar Klotz

Wm O'Keefe  
Univ. of Toronto  
Medical Faculty  
Jan 9/90

O'Keefe



THE STUDENT'S HANDBOOK  
OF  
SURGICAL OPERATIONS.



MS  
T

THE  
STUDENT'S HANDBOOK  
OF  
SURGICAL OPERATIONS.

BY

(*Sir*) FREDERICK TREVES, F.R.C.S.,  
SURGEON TO AND LECTURER ON ANATOMY AT THE LONDON HOSPITAL,  
MEMBER OF THE BOARD OF EXAMINERS OF THE ROYAL COLLEGE OF SURGEONS,  
EXAMINER IN SURGERY AT THE UNIVERSITY OF CAMBRIDGE.

WITH 94 ILLUSTRATIONS.

(Abridged from the Author's "Manual of Operative Surgery.")

FOURTH THOUSAND.

353911 / 23. 8. 38.

CASSELL & COMPANY, LIMITED:

LONDON, PARIS & MELBOURNE.

1892.

[ALL RIGHTS RESERVED]

J. W. CARVETH & CO.  
PUBLISHERS.  
TORONTO, - ONT.





## P R E F A C E .

---

THE present work is intended for the use of students who are preparing for the final examinations, or who need a hand-book to assist them in carrying out operations upon the dead body. The book is abridged from the author's large "Manual of Operative Surgery." That work aims at dealing in an exhaustive manner with the whole subject of operative surgery, or of treatment by operation. This hand-book concerns itself only with the most essential and most commonly performed operations. All matters save such as deal with the actual technical details of operative surgery have been omitted. I have not discussed the general principles of operative surgery, nor have I entered into a critical consideration of the value of various methods. I have assumed that the reader is familiar with the anatomy of the district concerned in each section, and I have omitted all accounts of the after-treatment. I have given no description of instruments and have left untouched the subjects of mortality and results.

The numerous intricate but rarely performed operations belonging to plastic surgery find no place

in the present volume, save in so far as they concern the common deformities of the lip and palate. Certain operations, such as circumcision and the tapping of hydrocele, are not included, as I consider they come rather under the heading of minor surgery.

Those who need fuller information upon these and other matters that are involved in treatment by operation are referred to the larger and more comprehensive work.

The engravings in this book are selected from among the four hundred and twenty woodcuts that illustrate the "Manual of Operative Surgery."

FREDERICK TREVES.

6, *Wimpole Street,*  
*London, W.*  
*May, 1892.*

---

# CONTENTS.

---

## PART I.—LIGATURE OF ARTERIES.

CHAP.	PAGE
I.—GENERAL CONSIDERATIONS . . . . .	1
II.—LIGATURE OF THE ARTERIES OF THE UPPER LIMB . . . . .	7
III.—LIGATURE OF THE ARTERIES OF THE HEAD AND NECK . . . . .	21
IV.—LIGATURE OF THE ARTERIES OF THE LOWER LIMB . . . . .	38

---

## PART II.—OPERATIONS UPON NERVES.

I.—INTRODUCTORY . . . . .	67
II.—OPERATIONS UPON THE NERVES OF THE HEAD AND NECK . . . . .	70
III.—OPERATIONS UPON THE NERVES OF THE EXTREMITIES . . . . .	79

---

## PART III.—AMPUTATIONS.

I.—METHODS OF PERFORMING AMPUTATION . . . . .	84
II.—AMPUTATION OF THE FINGERS AND THUMB . . . . .	91
III.—AMPUTATIONS OF THE FINGERS AND THUMB, TOGETHER WITH PORTIONS OF THE METACARPUS . . . . .	104
IV.—DISARTICULATION AT THE WRIST-JOINT . . . . .	110
V.—AMPUTATION OF THE FORE-ARM . . . . .	116
VI.—DISARTICULATION AT THE ELBOW-JOINT . . . . .	121
VII.—AMPUTATION OF THE ARM . . . . .	126
VIII.—DISARTICULATION AT THE SHOULDER-JOINT . . . . .	131
IX.—AMPUTATION OF THE UPPER LIMB, TOGETHER WITH THE CLAVICLE AND SCAPULA . . . . .	139
X.—AMPUTATION OF THE TOES . . . . .	144
XI.—PARTIAL AMPUTATION OF THE FOOT—AMPUTATION THROUGH THE TARSO-METATARSAL JOINTS . . . . .	155

CHAP.	PAGE
XII.—PARTIAL AMPUTATION OF THE FOOT—AMPUTATION THROUGH THE MEDIO-TARSAL JOINT . . . . .	163
XIII.—PARTIAL AMPUTATION OF THE FOOT—SUBASTRAGALOID DIS-ARTICULATION . . . . .	165
XIV.—AMPUTATION OF THE FOOT . . . . .	169
XV.—AMPUTATION OF THE LEG . . . . .	178
XVI.—DISARTICULATION AT THE KNEE-JOINT . . . . .	196
XVII.—AMPUTATION OF THE THIGH THROUGH THE CONDYLES . . . . .	202
XVIII.—AMPUTATION OF THE THIGH . . . . .	208
XIX.—DISARTICULATION AT THE HIP-JOINT . . . . .	217

---

PART IV.—OPERATIONS ON THE BONES AND JOINTS.

I.—OSTEOTOMY . . . . .	228
II.—OSTEOTOMY FOR FAULTY ANCHYLOSIS OF THE HIP-JOINT . . . . .	234
III.—OSTEOTOMY FOR GENU VALGUM . . . . .	237
IV.—CUNEIFORM OSTEOTOMY FOR INVETERATE CLUB-FOOT . . . . .	242
V.—EXCISION OF JOINTS AND BONES . . . . .	245
VI.—EXCISION OF THE FINGERS, THUMB, AND METACARPUS . . . . .	248
VII.—EXCISION OF THE WRIST . . . . .	251
VIII.—EXCISION OF THE ELBOW . . . . .	259
IX.—EXCISION OF THE SHOULDER . . . . .	267
X.—EXCISION OF THE CLAVICLE AND SCAPULA . . . . .	272
XI.—EXCISIONS OF THE TOES, METATARSUS, AND TARSUS . . . . .	275
XII.—EXCISION OF THE ANKLE . . . . .	278
XIII.—EXCISION OF THE KNEE . . . . .	281
XIV.—EXCISION OF THE HIP . . . . .	286
XV.—ARTHRECTOMY OR ERASION OF A JOINT. . . . .	291
XVI.—EXCISION OF THE MAXILLÆ . . . . .	294

---

PART V.—TENOTOMY.

INCLUDING OPERATIONS FOR THE DIVISION OF CONTRACTED MUSCLES, LIGAMENTS, AND FASCLE . . . . .	304
--	-----

## PART VI.—PLASTIC OPERATIONS.

CHAP.	PAGE
I.—OPERATIONS FOR HARE-LIP . . . . .	316
II.—OPERATIONS FOR CLEFT PALATE . . . . .	322
III.—OPERATIONS FOR RUPTURED PERINEUM . . . . .	328

---

## PART VII.—OPERATIONS ON THE NECK.

I.—TRACHEOTOMY . . . . .	334
II.—EXCISION OF THE LARYNX . . . . .	343
III.—EXCISION OF THE THYROID BODY . . . . .	347
IV.—EXCISION OF THE TONGUE . . . . .	350
V.—CESOPHAGOTOMY . . . . .	357

---

## PART VIII.—OPERATIONS UPON THE ABDOMEN.

I.—ABDOMINAL SECTION . . . . .	359
II.—OVARIOTOMY . . . . .	365
III.—REMOVAL OF THE UTERINE APPENDAGES . . . . .	369
IV.—HYSTERECTOMY . . . . .	371
V.—SUTURE AND RESECTION OF INTESTINE . . . . .	379
VI.—INTESTINAL ANASTOMOSIS . . . . .	387
VII.—ENTEROTOMY . . . . .	392
VIII.—COLOTOMY . . . . .	395
IX.—OPERATIONS ON THE STOMACH . . . . .	401
X.—OPERATIONS ON THE LIVER . . . . .	412
XI.—SPLENECTOMY . . . . .	416
XII.—OPERATIONS ON THE KIDNEY . . . . .	418

---

## PART IX.—OPERATIONS ON HERNIA.

I.—OPERATIONS FOR STRANGULATED HERNIA . . . . .	429
II.—OPERATIONS FOR THE RADICAL CURE OF HERNIA . . . . .	437

---

## PART X.—OPERATIONS UPON THE BLADDER.

I.—LATERAL LITHOTOMY . . . . .	440
II.—MEDIAN LITHOTOMY . . . . .	444

CHAP.	PAGE
III.—SUPRAPUBIC CYSTOTOMY . . . . .	445
IV.—URETHROTOMY . . . . .	450

---

## PART XI.—OPERATIONS UPON THE SCROTUM AND PENIS.

I.—OPERATIVE TREATMENT OF VARICOCELE . . . . .	455
II.—CASTRATION . . . . .	457
III.—AMPUTATION OF THE PENIS . . . . .	459

---

## PART XII.—OPERATIONS UPON THE RECTUM.

I.—OPERATIVE TREATMENT OF HÆMORRHOIDS . . . . .	461
II.—OPERATIVE TREATMENT OF FISTULA . . . . .	465
III.—EXCISION OF THE RECTUM . . . . .	467

---

## PART XIII.—OPERATIONS ON THE HEAD AND SPINE.

I.—TREPHINING IN FRACTURE OF THE SKULL . . . . .	470
II.—EXCISION OF THE EYE-BALL . . . . .	475
III.—OPERATIONS UPON THE SPINE AND SPINAL CORD . . . . .	477

---

## PART XIV.—OPERATIONS ON THE THORAX AND BREAST.

I.—OPERATIONS ON THE THORAX . . . . .	481
II.—REMOVAL OF THE BREAST . . . . .	455

## LIST OF ILLUSTRATIONS.

	PAGE
“Reef” and “Granny” Knots . . . . .	6
Ligature of the Radial and Ulnar Arteries, and of the Brachial at the Bend of the Elbow . . . . .	8
Ligature of the Right Radial about the Middle Third of the Fore-arm . . . . .	9
Ligature of Right Ulnar at the Middle Third of the Fore-arm	12
Ligature of the Right Brachial at the Bend of the Elbow .	15
Ligature of the Right Brachial at the Middle of the Arm .	16
Ligature of the Brachial about the Middle of the Arm, and of the Third Part of the Axillary . . . . .	18
Ligature of the First Part of the Axillary Artery, the Third Part of the Subclavian, the Common Carotid, and the Lingual . . . . .	22
Ligature of the Right Subclavian (Third Part) . . . . .	23
Ligature of the Right Common Carotid above the Omo-hyoid	27
Ligature of Right External Carotid . . . . .	30
Ligature of Right Lingual Artery . . . . .	35
Ligature of the Anterior Tibial Artery, and of the Dorsalis Pedis . . . . .	39
Ligature of Right Anterior Tibial Artery (Upper Third) .	40
Ligature of Right Anterior Tibial Artery (Lower Third) .	42
Ligature of Right Posterior Tibial Artery (Lower Third) .	45
Ligature of Right Popliteal (Lower Part) . . . . .	49
Ligature of the Right Common Femoral at the base of Scarpa's Triangle; of the Femoral at the apex of Scarpa's Triangle and in Hunter's Canal, and of the Upper Part of the Popliteal . . . . .	52
Ligature of Right Femoral Artery in Hunter's Canal . . .	53
Ligature of Right Femoral Artery at apex of Scarpa's Triangle . . . . .	55

	PAGE
Ligature of Right Common Femoral at base of Scarpa's Triangle . . . . .	56
Ligature of External Iliac Artery . . . . .	58
A, Neurotomy of Third Division of Fifth Nerve; B, Removal of Meckel's Ganglion; C, Exposure of Brachial Plexus; D, Exposure of Spinal Accessory Nerve . . . . .	73
Amputation of Fingers . . . . .	94
A, Disarticulation by Single External Flap; B, Amputation by Lateral Flaps; C, Disarticulation by Oval or Racket Incision; D, Modified Racket Incision for Index Finger; E, Circular Method, with Vertical Dorsal Cut; F, Incision <i>en croupière</i> ; G, Interno-palmar Flap Method for Little Finger; H, Disarticulation by Single Palmar Flap; I, Disarticulation by Racket Incision; K, Amputation of the Fingers with their Metacarpal Bones; L, Circular Disarticulation at the Wrist. . . . .	98
A, Disarticulation by Special Externo-palmar Flap; B, Disarticulation by Lateral Flaps; C, Amputation by unequal Dorso-palmar Flaps; D, Disarticulation by Oblique Palmar Flap; E, Disarticulation of the Ring-finger with its Metacarpal Bone by Racket Incision; F, same Operation upon the Little Finger; G, Dubrueil's Disarticulation at the Wrist . . . . .	102
A, Disarticulation of the Thumb with its Metacarpal Bone by Palmar Flap; B, Amputation of the three Inner Fingers with their Metacarpal Bones . . . . .	108
A, Palmar Incision in the Circular Disarticulation at the Wrist; B B, Incisions in the Elliptical Disarticulation at the Wrist . . . . .	111
Disarticulation at the Elbow-joint by the Anterior Ellipse Method . . . . .	123
Disarticulation at the Elbow-joint by the Posterior Ellipse Method . . . . .	124
Disarticulation at the Elbow-joint by Anterior Flap . . . . .	125
A, Circular (inclined) Amputation of the Arm; B, Amputation of the Arm by Antero-posterior Flaps; C, Amputation at the Shoulder-joint by Deltoid Flap . . . . .	128
Disarticulation at the Shoulder by Racket Incision (Spence's Operation) . . . . .	133




	PAGE
Disarticulation at the Shoulder-joint (Larrey's Operation) . . . . .	136
Interscapulo-thoracic Amputation . . . . .	141
Disarticulation of the last Phalanx of the Great Toe by a large Plantar Flap . . . . .	145
Disarticulation of the Great Toe by Internal Plantar Flap . . . . .	148
Lisfranc's Amputation . . . . .	160
Chopart's Amputation . . . . .	164
A, Disarticulation of the Little Toe, together with its Meta- tarsal Bone, by the Oval or Racket Incision; B, Maurice Perrin's Subastragaloid Amputation. . . . .	166
A, Disarticulation of the Great Toe, together with its Meta- tarsal Bone, by the Oval or Racket Incision; B, Subas- tragaloid Amputation by Heel Flap . . . . .	167
Syme's Amputation of the Foot . . . . .	172
c c, Saw-cuts in Pirogoff's Operation; D D, Saw-cuts in Pas- quier and Le Fort's Operations; D shows also the Saw- cut made in the Os Calcis in Tripiet's Operation . . . . .	173
Pasquier and Le Fort's Operation . . . . .	174
Tripiet's Operation . . . . .	176
A, Guyon's Supramalleolar Amputation; B, Duval's Supra- malleolar Amputation . . . . .	179
Teale's Amputation of the Leg . . . . .	183
A, Modified Circular Supramalleolar Amputation; B, Hey's Amputation; c, Circular Amputation at "the place of election;" D, Gritti's Operation . . . . .	186
A, Amputation of Lower Part of Leg by long Posterior Flap; B, Amputation at "the place of election" by large External Flap (Farabeuf's Operation); c, Carden's Am- putation; D, Lister's Modification of the same . . . . .	189
Method of Sawing the Tibia . . . . .	191
Method of Sawing the Bones of the Leg. . . . .	191
Method of Sawing the Bones of the Leg. . . . .	191
A, Amputation at "the place of election" by Lateral Flaps; B, Disarticulation at the Knee by long Anterior Flap . . . . .	197
A, Stephen Smith's Disarticulation at the Knee; B, Amputa- tion of the Thigh by Lateral Flaps . . . . .	198
Farabeuf's Amputation through the Condyles of the Femur . . . . .	205

	PAGE
A, Circular Amputation of Thigh ; B, Amputation of Thigh by equal Antero-posterior Flaps ; c, Disarticulation at the Hip by External Racket Incision . . . . .	209
A, Amputation of the Thigh by long Anterior and short Posterior Flaps ; B, Disarticulation at the Hip by Antero-posterior Flaps . . . . .	213
Disarticulation at the Hip-joint by an Anterior Racket Incision . . . . .	223
Diagram to show the lines of the Chisel Cuts in Cuneiform Osteotomy for Angular Deformity after Fracture, etc. . . . .	231
Osteotomy for Faulty Anchylosis of the Hip . . . . .	235
Vertical Section of the Lower End of a Deformed Femur, from an extreme case of Genu Valgum . . . . .	237
Macewen's Operation for Genu Valgum . . . . .	239
A, Excision of Metacarpo-phalangeal Joint of Index ; B B, Excision of Interphalangeal Joint of Thumb ; c, Excision of Metacarpo-phalangeal Joint of Thumb ; D, Excision of First Metacarpal Bone . . . . .	249
Excision of the Wrist . . . . .	254
Excision of the Wrist (Lister's Incision). . . . .	257
Excision of the Elbow . . . . .	260
Excision of the Elbow . . . . .	265
Excision of the Shoulder. . . . .	269
A, Excision of Astragalus (Outer Incision) ; B, Excision of Ankle (Outer Incision) ; c, Excision of Os Calcis . . . . .	275
A, Excision of Astragalus (Inner Incision) ; B, Excision of Ankle (Inner Incision) . . . . .	279
Excision of the Hip : Langenbeck's External Incision . . . . .	287
Excision of the Hip : Anterior Incision . . . . .	289
Excision of the Upper Jaw . . . . .	297
Sole of the Foot in Talipes Varus, to show the Creases on the Skin . . . . .	307
Operation for Single Hare-lip . . . . .	317
Mirault's Operation . . . . .	319
Giraldès' Operation . . . . .	319
Operation for Double Hare-lip . . . . .	320
Operation for Double Hare-lip . . . . .	321
Repair of Ruptured Perineum (Galabin) . . . . .	329
Repair of Ruptured Perineum (Galabin) . . . . .	330

*LIST OF ILLUSTRATIONS.*

XV

	PAGE
Operations on the Larynx and Trachea . . . . .	339
Removal of the Tongue . . . . .	353
Dupuytren's Suture . . . . .	379
Lembert's Suture . . . . .	380
Lembert's Suture . . . . .	381
Czerny-Lembert's Suture . . . . .	381
Senn's Bone Plate with the Sutures in position . . . . .	388
Intestinal Anastomosis with Bone Plates . . . . .	389
Incision in Lumbar Colotomy . . . . .	396
Incision for Gastrostomy . . . . .	402
Pylorotomy . . . . .	408
Incision for Inguinal Hernia . . . . .	434
Excision of the Breast . . . . .	486



Jan 21 1895  
Mar 26 1896

THE  
STUDENT'S MANUAL  
OF  
SURGICAL OPERATIONS.

---

---

Part I.

LIGATURE OF ARTERIES.

---

CHAPTER I.

GENERAL CONSIDERATIONS.

**Instruments required.**—The following is the list:—1, Scalpel; 2, two pairs of dissecting forceps; 3, wound hooks; 4, retractors; 5, long toothed-forceps; 6, pressure forceps; 7, aneurysm needle; 8, ligature.

The tissues are often very conveniently divided between two pairs of dissecting forceps, one pair being held by an assistant.

Small blunt hooks, with long shafts, are most useful as retractors, especially to draw nerves and tendons out of the way. Their use is well illustrated in the operation for securing the lingual artery.

Good retractors are needed when deeply-seated vessels are concerned.

The sheath may be in most cases quite conveniently picked up by ordinary dissecting forceps. In the case of deep-seated arteries, however, longer, finer, and

neater instruments are required, and of these the finely-toothed forceps are the most handy.

The best ligature material on the whole is chromicised catgut. It must be of reliable make, be strong, round, quite lissome, of uniform thickness, and perfectly smooth. The size must be regulated by the dimensions of the vessel to be tied.

**Position of the patient.**—The position of the patient will vary a little according to the artery to be tied. In general terms, it may be said that the surgeon should stand upon the side to be operated on, and that the incision on the right side is more conveniently made from above downwards, and on the left side from below upwards. The chief assistant stands opposite to the surgeon, and has for his principal duty the sponging and the retraction of the parts of the wound.

#### **The steps of the operation.**

1. The incision.
2. The exposure of the artery.
3. The opening of the sheath.
4. The passing of the ligature.

1. *The incision.*—The incision should, when possible, be so placed upon the line of the artery as to avoid superficial veins. It is most desirable that there should be little bleeding during the operation, that the wound should be “dry,” and the view of the depths not embarrassed by pressure forceps.

The scalpel should be held in what is termed the dinner-knife position. The cut should be freely made and cleanly cut.

The knife should be entered at right angles to the surface, and should be in the same position when withdrawn. The surface wound should be of equal depth throughout. There should be no “tails” to the cut.

The skin should be steadied with the left hand while the integuments are being divided.

After the surface cut has been made, the next step is to divide the deep fascia, or aponeurosis. This is done by a clean cut made in the line of the original incision, and carried the whole length of the wound.

A director is not required either at this or any other stage of the operation.

When the deep fascia has been exposed in a limb, the outlines of the underlying muscles and tendons are rendered more or less distinct. A gap between two adjacent muscles has usually to be followed in the operation. This gap is very commonly said to be indicated by a white or a yellow line. The "yellow line" is due to the fat occupying the hollow between the muscles, and is not seen in wasted subjects; nor is it clear in the cadaver, nor in a limb which has been deprived of blood by Esmarch's band.

The "white line" is almost equally deceptive; it depends upon a thickening of the fascia itself, due to the attachment of an intermuscular septum.

The interval is best sought by the sense of touch and by the left index finger, and is best opened with the handle of the scalpel or with the finger. No attempt should be made to demonstrate it by the edge of the scalpel.

The deep part of the wound should follow the line of the superficial incision, and should equal it in extent. The wound should not be funnel-shaped.

Retractors must be freely used.

2. *The exposure of the artery.*—The artery should be sought for with the finger.

To the touch the nerves feel firm, resisting, round, and cord-like. They cannot be flattened by the pressure of the finger. The veins greatly exceed the corresponding arteries in size. They often overlap these vessels. They feel soft and yielding, and thin-walled.

They are easily compressed, and when so treated swell out upon the distal side. When the finger touches the compressed vein the vessel as a tube can scarcely be appreciated. In this respect it is very different from the artery. The artery feels firmer and more elastic. It is not unlike a thin india-rubber tube to the touch. It is movable, and often slips about under the finger in a characteristic manner. It can be compressed, but not so readily as the vein. When flattened out by the finger, an artery of moderate dimensions feels like a flat band or thong, thick and elastic, and hollowed out a little in the centre, so that the margins feel thicker than the median part. Above all, it pulsates.

In the matter of the appearance of the tissues, the depth of the wound—which is often great—and the even tinting of the parts with blood, render an inspection of less value than an examination with the finger. When the wound is well opened up the nerves stand out as clear, rounded, white cords; the veins are of a purple colour, and of somewhat uneven and wavy contour; the artery is regular in outline, and is of a pale pink or pinkish-yellow tint, the large vessels being of lighter colour than the small.

There may be one companion vein or two—the *venæ comites*.

3. *The opening of the sheath.*—The sheath must be opened with the scalpel with infinite care and precision.

It is picked up over the *centre*, or median part, of the artery, in the form of a fold which is *transverse* to the long axis of the vessel.

This transverse fold of the sheath is then incised. The cut should be clean, should be made in the *long axis* of the artery, and over the *centre* of the vessel. In length it should be from 5 to 10 mm.

When the sheath has been well divided, the



serous-like space between it and the artery becomes at once evident.

4. *The passing of the ligature.*—The original hold of the forceps upon the sheath should not be relaxed. The surgeon now takes the aneurysm needle in his right hand, and introduces its unthreaded point between the artery and the sheath, for the purpose of clearing the former. The needle should be held with its concavity towards the vessel, and it should be gently insinuated about half-way round the artery, being passed under that part of the sheath held up by the forceps.

The sheath upon the opposite side of the incision should now be taken up with the forceps, and the needle be passed beneath the vessel so as to clear the remaining portion—the deep part—of its surface. The needle will soon emerge in the wound upon the opposite side of the artery, when it should be threaded, and be then withdrawn, carrying the ligature with it.

About one centimètre of the artery, more or less, is cleared. The needle should be kept throughout at right angles to the line of the vessel. It should never be passed threaded.

It is the usual practice to pass the needle from the vein. A more important rule is to pass the needle from the forceps.

The ligature should be passed and be tied exactly at right angles to the line of the artery. The knot should be tied quietly and slowly.

It should be sufficiently tight to rupture the inner coats. Care should be taken that the vessel is not dragged out of place in the tying.

The points of the two forefingers should meet upon the artery as the knot is being tied, and the final strain upon the ligature should be given by placing the terminal knuckles of these two fingers in contact, and using them as the fulcrum of a lever.

The *knot* should be a reef-knot (Fig. 1), not a "granny." The double-hitch, or surgical knot, is not suitable, more especially when catgut is employed.

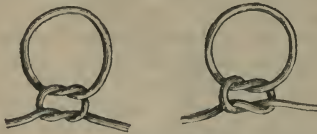


Fig. 1.—The figure to the right shows a Reef Knot, that to the left a "Granny."

The practice of applying a *double ligature* to the artery, and of dividing the vessel between them, has been revived of late years.

The superficial wound is closed by sutures, and dressed in the usual way. No drainage-tube is required.

## CHAPTER II.

## LIGATURE OF THE ARTERIES OF THE UPPER LIMB.

## THE RADIAL ARTERY.

*Line of the artery.*—A line from the centre of the bend of the elbow to the gap between the scaphoid bone and the tendons of the extensor ossis and extensor primi internodii pollicis.

*Position.*—The surgeon stands upon the side to be operated on. The limb is in the position of supination. The incision on the right side should be made from above downwards; on the left side it is conveniently made in the opposite direction.

**1. Ligature in the lower third of the forearm.**

*Operation.*—An incision about one inch and a quarter in length is made over the line of the pulse, midway between and parallel with the tendons of the supinator longus and flexor carpi radialis muscles. The cut must not reach below the level of the tuberosity of the scaphoid (Fig. 2).

The commencement of the superficial radial vein usually lies over the artery in this situation, and immediately under the skin. It should be avoided.

The fascia, which is here quite thin, is divided in the line of the original wound. The gap between the two tendons is now made manifest. Over, or in close relation to, the artery may be observed the terminal part of the anterior division of the external cutaneous nerve.

It may be impossible to separate the venæ comites from the artery to a sufficient extent to allow the needle to pass. In such case the ligature must include the veins as well as the artery.

*Comment.*—The operation is extremely easy. Some confusion may arise in cases where the superficialis volæ artery has a high origin, and lies upon or by the side of the radial. This is especially the case when the branch is of unusual size.

## 2. Ligature in the middle third of the fore-arm.

*Operation.*—An incision two inches in length is made in the line of the artery, the limb being in the position indicated. The centre of the incision corresponds to the centre of the fore-arm (Fig. 2). In cutting through the subcutaneous tissues, care must be taken to avoid any superficial vein belonging to the radial or median veins.

The anterior division of the musculo-cutaneous nerve lies usually in the line of the artery, outside the deep fascia and just beneath the superficial veins.

The deep fascia is laid bare, and is divided in the length of the original wound. The fibres are transverse.

The supinator longus muscle is now exposed about the point where it is beginning to




Fig. 2.—Ligature of the Radial and Ulnar Arteries, and of the Brachial at the bend of the Elbow.

become tendinous. The inner or ulnar border of the

muscle is defined, and the muscle itself is drawn outwards. The elbow may be a little flexed to allow of this being done more easily.

The vessel is now found lying upon the insertion of the pronator radii teres, with which it is connected by much connective tissue. The nerve may or may not be seen (Fig. 3).

The venæ comites should be separated as well as is

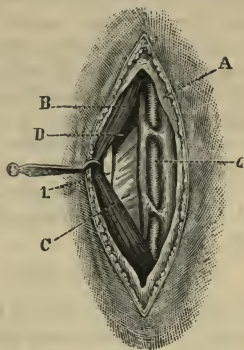


Fig. 3.—Ligature of the Right Radial, about the Middle Third of the Fore-arm.

A, Fascia; B, sup. long.; C, insertion of pron. teres; D, sup. brevis; a, artery  
l, radial nerve.

possible, and the needle passed from whichever side is the more convenient.

*Comment.*—As the supinator longus is not very wide at this part (especially if the artery be sought for at the lower end of the middle third), it is easy to expose the outer instead of the inner border of the muscle, in which case the muscle is apt to be drawn inwards, and when the depths of the radial wound are opened up the radial nerve is reached. This is the common error of beginners.

### 3. Ligature in the upper third of the fore-arm.

*Operation.*—This operation differs very little from the last. The incision is two and a half inches in length, and is made in the line of the artery. The centre of the skin-cut corresponds to the part of the vessel to be tied. The radial or other surface vein may be encountered in the superficial part of the wound. After the deep fascia has been divided, the interval between the supinator longus and pronator teres muscles is opened up. There is no difficulty in identifying these two structures—the fibres of the supinator are vertical; those of the pronator are oblique. In muscular subjects the supinator is so wide that its inner border cannot be readily exposed.

Under cover of the supinator the radial artery will be found. The nerve is not in relation with it. The needle should be passed from whichever side is the more convenient.

#### THE ULNAR ARTERY.

*Line of the artery.*—The ulnar in the lower two-thirds of its course in the fore-arm is represented by a line drawn from the tip of the internal condyle of the humerus to the radial side of the pisiform bone.

The curve of the vessel in the upper third of its course is such that a line drawn from the commencement of the artery—at the middle of the bend of the elbow—to the radial side of the pisiform bone, will scarcely touch the vessel in any part of its course.

The upper third of the artery is too deeply placed to be exposed for ligature, unless it be actually laid bare in a wound.

*Position.*—As for ligature of the radial artery in the fore-arm.

### 1. Ligature in the lower third of the fore-arm.

*Operation.*—An incision, two inches in length, is made along the line of the artery, just to the radial side of the flexor carpi ulnaris tendon. The incision terminates an inch or less above the pisiform bone (Fig. 2). Care must be taken to avoid any tributary to the superficial ulnar vein which may be over the line of the artery. The deep fascia—which is here very slender—is exposed and divided.

The tendon of the flexor carpi ulnaris muscle is now displayed. The wrist is a little flexed to relax the tendon, which is gently drawn inwards by a blunt hook. The vessels are now exposed. The artery in this situation is bound down to the flexor profundus by a definite layer of fascia. This must be carefully divided. The nerve is close to the artery, and upon its inner side. It may be impossible to isolate the artery from the companion veins. The needle is passed from within outwards. The palmar cutaneous branch of the ulnar nerve lies upon the artery in this situation, and must be avoided.

*Comment.*—It is possible that the operator may expose the inner side of the flexor carpi ulnaris tendon by mistake. On this (the wrong) side of the tendon, muscular fibres will be found entering the tendon almost down to the wrist. On the radial side the tendon is quite clear. Care must be taken not to wound the synovial sac, which accompanies the flexor sublimis digitorum tendons beneath the annular ligament.

## 2. Ligature in the middle third of the fore-arm.

*Operation.*—An incision, from two and a half to three inches in length, according to the muscular condition of the limb, is made precisely in the line of the artery (Fig. 2). Beneath the integuments the anterior ulnar vein and branches of the anterior division of the internal cutaneous nerve are apt to be encountered. The deep fascia is thin, and is divided in a

line parallel with, but a little to the outer side of the line of, the skin incision.

The surgeon now seeks for the gap between the flexor carpi ulnaris muscle and the flexor sublimis digitorum. The position of this interval is sometimes indicated by a white line. The gap is, however, best

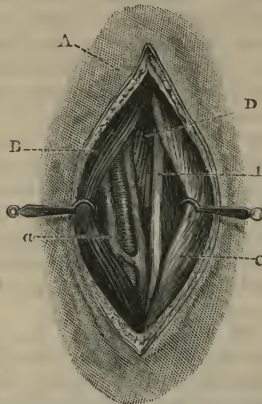


Fig. 4.—Ligature of Right Ulnar at the Middle Third of the Fore-arm.  
A, Fascia; B flex. sublimis; C, flex. carp. ulnaris; D, flex. profundus; a, artery;  
I, ulnar nerve.

demonstrated by the touch, the left forefinger being used for the purpose. As soon as the intermuscular space has been made evident, the wrist is a little flexed to relax the muscles. The flexor carpi ulnaris is now drawn inwards by means of a broad-bladed retractor. The flexor sublimis is in like manner drawn a little outwards. The surgeon opens up the vertical intermuscular space thus demonstrated, and at the bottom of it will probably first be found the ulnar nerve. To the outer side of the nerve is the artery (Fig. 4). The



fascia binding down the vessels in this situation is slender. There is usually no difficulty in separating the artery from its venæ comites.

The needle should be passed from within outwards, so as to avoid the nerve.

*Comment.*—This operation is associated with considerable difficulty if carelessly performed.

The chief difficulty is to demonstrate the gap between the flexor carpi ulnaris and flexor sublimis muscles.

The “white line” which is said to mark this gap is not to be relied upon. There may be no trace of such a line: it may be very faintly indicated, or the position of the interspace may be marked by a yellow fatty line. The white line is best seen in young muscular subjects.

The white line, when it does exist, indicates the tendinous margin of the flexor carpi ulnaris.

The interspace between the two muscles in question is not quite straight: *i.e.* is not quite vertical when the limb is in position for the operation. The flexor carpi ulnaris overlaps the flexor sublimis a little, and the line of the interspace is directed obliquely.

When the proper interval has been found between the flexor sublimis and the flexor carpi ulnaris, it is not uncommon for the beginner—impressed with erroneous views as to the depths of the artery—to proceed too deeply and too far to the inner side, and to actually pass by the ulnar nerve and open up the interspace between the flexor carpi ulnaris and the flexor profundus digitorum.

This may readily happen if the former muscle be dragged too much to the inner side.

## THE BRACHIAL ARTERY.

*Line of the artery.*—When the arm is extended and abducted with the hand supine, the brachial artery corresponds to a line drawn from the outlet of the axilla (at the junction of its middle and anterior thirds) to the middle of the bend of the elbow.

*Position.*—In securing the artery at the bend of the elbow, the limb, extended and abducted, may be allowed to rest upon the olecranon. It should not be over-extended.

In dealing with the vessel in the arm, the limb should be extended and abducted with the hand supine, and should be held away from the body. The arm itself should not be supported in any way, but the limb should be held by the fore-arm by an assistant.

The surgeon may make the incision from above downwards on both sides of the body, standing to the outer side of the limb on the right side, and between the trunk and the limb on the left side. Or on the left side the operator may place himself to the outer side of the limb, and, bending over it, may make the incision from below upwards.

### 1. **Ligature at the bend of the elbow.**

*Operation.*—The arm having been placed in the position indicated, the surgeon, by flexing and extending the limb, makes out the exact position of the biceps tendon, and by compressing the veins of the upper arm renders evident the median basilic vein.

An incision, two inches in length, is made through the skin, along the inner edge of the biceps, and parallel with its margin. The wound will therefore be oblique, and it should be so placed that its centre corresponds to the mark on the skin called the “fold of the elbow” (Fig. 2). The upper end of the

incision will correspond to the level of the tip of the internal condyle. If the veins be normally disposed, the skin wound will lie to the outer side of the median basilic vein, and nearly parallel to it.

As soon as the vein is exposed, it should be drawn inwards. The bicipital fascia is now demonstrated, and divided in the line of the original

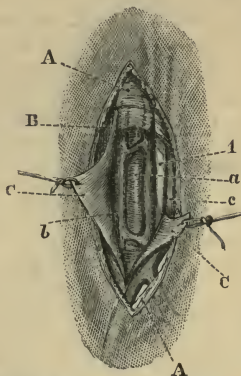


Fig. 5.—Ligature of the Right Brachial at the Bend of the Elbow.  
 A, Fascia; B, biceps tendon; c, bicipital fascia; a, artery; b, venæ comites;  
 c, basilic vein; l, median nerve.

incision. The artery, with its venæ comites, will now be exposed (Fig. 5).

The venæ comites having been separated, the needle is passed from within outwards. The median nerve does not come conspicuously into the field of the operation. It is nearest to the artery (on its inner side) at the upper part of the wound.

The median basilic vein is closely attached to the thin integument, and, unless made quite evident, may easily be wounded.

## 2. Ligature at the middle of the arm.

*Operation.*—The limb having been placed in the position indicated, an incision about two and a half inches in length is made along the inner edge of the biceps muscle, in the line of the artery (Fig. 7).

The fascia, which is here thin, is exposed and

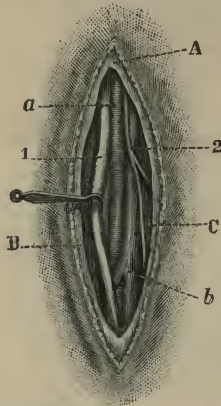


Fig. 6.—Ligature of the Right Brachial at the Middle of the Arm.

A, Fascia; B, biceps; C, triceps; a, artery; b, vena comes; 1, median nerve; 2, internal cutaneous nerve.

divided, and the muscular layer is reached. It is extremely important that the inner margin of the biceps be clearly exposed and surely identified. The muscle is displaced a little outwards, and the pulsation of the vessel is sought for. A little dissection exposes the median nerve—if it be not already in view (Fig. 6). In the middle of the arm the nerve usually lies in front of the artery. In applying a ligature to any part of the brachial, at or above the middle of its course, the nerve should be drawn

outwards. If the brachial be exposed below the middle section, the nerve is more conveniently displaced inwards.

The sheath of the artery having been opened, and the venæ comites separated as well as possible, the needle is passed from the nerve. The inner of the two companion veins is usually much larger.

In the upper part of its course the inner margin of the coraco-brachialis muscle is exposed in the place of the biceps, and the ulnar nerve is lying to the inner side of the vessel.

*Comment.*—This artery is by no means so easy to ligature as may appear.

In the first place, the arm should be unsupported, and be at right angles to the trunk. If the arm be allowed to rest upon a table, the triceps may be pushed forwards, and may be then mistaken for the biceps; while the ulnar nerve has been mistaken for the median. This observation especially applies to the middle third of the limb.

The vessel is mobile, and is easily displaced, and in drawing the biceps aside roughly with a retractor, the vessels and the median nerve have been withdrawn from the field of the operation, and possibly the ulnar nerve brought into view. The clear identification of the biceps margin is essential.

The pulse in the brachial may be so clearly transmitted to the median nerve that that cord has been mistaken for the artery.

It is asserted that the basilic vein has been mistaken for the artery, and that a large inferior profunda artery has been taken for the brachial.

#### THE AXILLARY ARTERY.

*Line of the artery.*—A line from about the centre of the clavicle to the humerus, close to the inner border of the coraco-brachialis, will represent the

artery when the arm is so abducted as to be at right angles to the body.

1. **Ligature of the third part.**

*Operation.*—The patient is placed upon the back, close to the edge of the table, and has the shoulders raised. The arm is at right angles to the body, and is held horizontally.

The surgeon may place himself between the arm

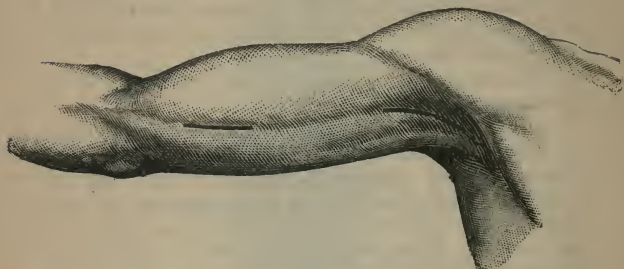

Fig. 7.—Ligature of the Brachial about the Middle of the Arm, and of the Third Part of the Axillary.

and the thorax when about to secure either artery. It is the practice of some to stand to the outer side of the limb, near the patient's head, and to bend over the extremity, when operating upon the right axillary. The axilla should be shaved.

An incision, about three inches in length, is made along the line of the artery. It commences at the middle of the outlet of the axilla, at the junction of its anterior and middle thirds, and is continued down along the inner margin of the coraco-brachialis muscle (Fig. 7). After the integuments and fascia have been divided, the inner margin of the coraco-brachialis should be thoroughly exposed. This muscle, with the musculo-cutaneous nerve, is then drawn gently outwards. The position of the artery may now be

determined with the finger. In exposing it the median nerve is at once made evident, and should be drawn outwards by means of a small blunt hook. The internal cutaneous nerve should be gently displaced inwards. The venæ comites need to be well demonstrated. The artery having been cleared, the needle is passed from within outwards.

*Comment.*—The numerous nerves in relation with this part of the vessel somewhat confuse the operation. The veins are apt to obscure the vessel. Abnormalities in the artery must be anticipated. A muscular slip passing from the latissimus dorsi to join the pectoralis major, biceps, or coraco-brachialis, may cross over the vessels. Such a slip may readily be mistaken, when large, for the coraco-brachialis muscle.

## 2. Ligature of the first part.

*Operation.*—The patient lies upon the back, close to the margin of the table, with the upper part of the body raised. The point of the shoulder should be carried well back, and to effect this a hard cushion may be placed between the scapulæ. The arm is allowed to lie by the patient's side. It must not be dragged upon so as to depress the point of the shoulder.

The operator should stand upon the outer side of the limb, near the patient's trunk, when dealing with the left side, and near the head when dealing with the right.

A slightly curved incision, with the convexity downwards, is made across the (supraclavicular fossa. *infra* The cut commences just outside the sterno-clavicular joint, and ends just outside the coracoid process. It passes about half an inch below the clavicle, and the centre of the incision is about opposite to the centre of that bone (Fig. 8).

The skin, platysma, supraclavicular nerves, and fascia are divided in the first incision.

The cephalic vein should be exposed, and forms a useful guide to the artery.

The pectoralis major is divided through its entire thickness close to the clavicle, and to the full extent of the original wound. The upper edge of the lesser pectoral should be defined and drawn down.

The costo-coracoid membrane must now be dealt with. It should be divided vertically near to the coracoid process. The cephalic vein, if well brought out, will indicate the position of the axillary vein.

The artery is now exposed, and the needle should be passed from the vein. The vein should be held aside with the finger while the needle is being passed.

It must be remembered that the vein is least in the way when the arm is by the side.

*Comment.*—There is great danger of tearing the axillary vein, and also of air being drawn into some of the smaller veins. If the pectoralis minor receive a slip from the second rib, the area of the operation is much curtailed. The cord of the brachial plexus nearest to the artery may be mistaken for that vessel.



## CHAPTER III.

## LIGATURE OF THE ARTERIES OF THE HEAD AND NECK.

## THE SUBCLAVIAN ARTERY.

A LIGATURE has been applied to each of the three parts of the subclavian artery. So far as surgical experience at present extends, it may be said that the operation is only justifiable when the third part of the artery is concerned.

*Position* (to ligature the third part).—The patient lies upon the back close to the edge of the table, with the thorax raised and the head extended and turned to the opposite side.

The arm should be pulled well down and fixed. This latter object is best effected by passing the arm behind the back whenever that is possible, and allowing it to remain fixed in that posture. The operator stands in front of the shoulder.

**Ligature of the third part of the subclavian artery.**

*Operation.*—The skin over the posterior triangle having been drawn down with the fingers of the left hand, an incision is made through it down to the clavicle. By adopting this plan a risk of wounding the external jugular vein is avoided. The incision, which is transverse, should be about three inches in length, and when the traction upon the skin is withdrawn should lie about half an inch above the clavicle (Fig. 8). It should extend across the base of the posterior triangle from the trapezius to the sternomastoid, and should be so planned that the centre of the wound shall correspond to a point about one inch to the inner side of the centre of the clavicle. This

first incision divides the integuments, the platysma and the supraclavicular nerves, with possibly a vein which passes over the clavicle to connect the cephalic vein with the external jugular. The amount of trapezius and sterno-mastoid exposed will depend upon

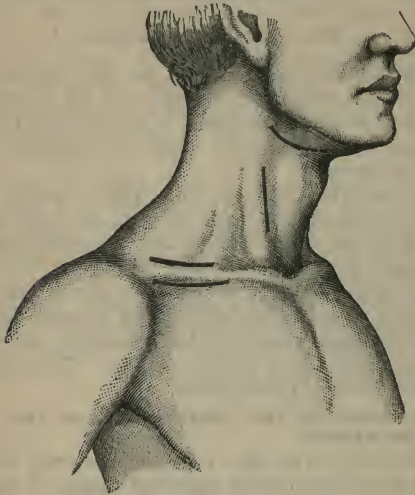


Fig. 8.—Ligature of the First Part of the Axillary Artery, the Third Part of the Subclavian, the Common Carotid, and the Lingual.

the extent to which those muscles are attached to the clavicle.

The deep cervical fascia is now reached, and is divided in the length of the original wound. No director should be employed. The external jugular vein must now be dealt with. Very probably it can be drawn aside and may be held by a small blunt hook towards the outer angle of the wound. If it

obstruct the area of the operation in a more determined manner, it may have to be divided between two ligatures.

The outer margin of the anterior scalene muscle should next be defined, and the position of the omohyoid made out. The latter muscle, if at all in the way, must be drawn upwards. When the edge of the scalene muscle has been made plainly evident, the finger should be passed along it until the tubercle on the

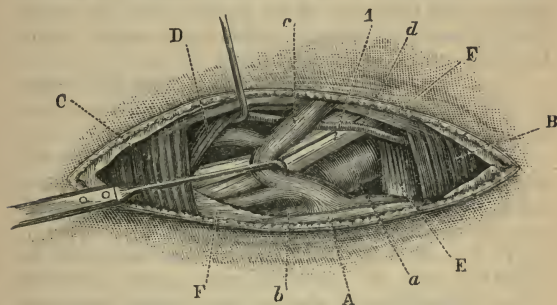


Fig. 9.—Ligature of the Right Subclavian (third part).

A, Clavicle; B, sternomastoid; C, trapezius; D, omohyoid; E, anterior scalene; F, cervical fascia; a, subclavian artery; b, subclavian vein; c, ext. jugular vein; d, transverse cervical artery; 1, brachial plexus.

first rib is encountered. The finger will now be in contact with the artery, and its pulsations can be felt (Fig. 9).

The vessel will be found actually resting upon the bone. A little careful dissection will clear the artery and bring into view the lowest cord of the brachial plexus.

This nerve cord should be systematically exposed by a slight and careful dissection. It may be at once said that it has been the source of some of the more serious mistakes which may be made in this operation.

The subclavian vein will be seen and felt, but it seldom encroaches much upon the field of the operation.

The needle (unthreaded) may now be very carefully passed from above downwards and from behind forwards. Its course must be directed by the forefinger of the left hand. By this finger the vein is protected and held out of the way. If the needle be passed from below—*i.e.* from the vein—it is easy to pick up the last cord of the plexus with the artery. The pleura has been wounded by a needle which has been carelessly passed.

*Comment.*—In order to obtain sufficient room, portions of the trapezius or of the sterno-mastoid may have to be cut.

The transverse cervical or suprascapular arteries may be in the way. They should be drawn aside, but in no case divided, as they play a most important part in the collateral circulation.

If the neck be short and the patient stout, the difficulties of the operation are much increased. Great difficulty will also be experienced when the veins have a plexiform arrangement or are engorged, and when the tissues are found to be œdematous and matted together.

The pleura has been several times wounded in passing the needle, and in many of the fatal cases where this accident is not noted the patient succumbed to intrathoracic inflammation. The ligature has been passed around the last cord of the brachial plexus by accident. The posterior scapular artery has been picked up and mistaken for the subclavian.

In very few instances does the subclavian vein appear to have been wounded.

Difficulties may be caused by the presence of a cervical rib or by an abnormality in the artery.

## THE VERTEBRAL ARTERY.

**Operation.**—The position of the patient and of the surgeon is the same as in the operation upon the third part of the subclavian (page 21).

An incision, three inches in length, is commenced at the clavicle, and is carried upwards along the outer or posterior edge of the sterno-mastoid muscle. The skin and superficial tissues are divided, and especial care is taken to avoid wounding the external jugular vein. The deep fascia having been severed, the sterno-mastoid is exposed, and with the jugular vein is drawn inwards.

It will probably be necessary to divide some part of the clavicular attachment of the sterno-mastoid close to the bone. The operator now defines the scalenus anticus, and makes evident the interval between that muscle and the longus colli. With the finger he should make out the position of the common carotid artery and internal jugular vein, and define the transverse processes of the seventh and sixth cervical vertebræ. The process of the latter vertebra forms a good guide, and below it the pulse of the artery should be felt. The various structures encountered must be carefully displaced to one or other side.

The vertebral vein lies in front of the artery, and should be pushed aside. Care must be taken not to damage the inferior thyroid vessels, the pleura, or, on the left side, the thoracic duct. The phrenic nerve need not be exposed. The needle is passed from without inwards.

*Comment.*—The ligature of this artery is a matter of no little difficulty. The greatest care must be taken to avoid injury to the various important structures which lie adjacent to the vessel. Both the inferior thyroid and the ascending cervical arteries have been mistaken for the vertebral,

## THE INFERIOR THYROID ARTERY.

The inferior thyroid may arise direct from the subclavian, or have origin from the common carotid or vertebral. It may be double, or entirely absent.

The size, course, and situation of the vessel vary very greatly in cases of bronchocele.

**Operation.**—An incision, three inches in length, is made along the inner edge of the lower part of the sterno-mastoid muscle, just as in ligature of the common carotid low down. The wound reaches to the clavicle. The sterno-mastoid is exposed and drawn outwards, the carotid artery and its vein are reached and are drawn carefully *outwards*. The surgeon now seeks for the transverse process of the sixth cervical vertebra, and a little below that the artery may be discovered, passing inwards from behind the carotid. It is ligatured close to the carotid, and in this way the immediate neighbourhood of the recurrent laryngeal nerve is avoided.

## THE COMMON CAROTID ARTERY.

*Line of the artery.*—The course of the common carotid is represented by a line drawn from the sterno-clavicular articulation to a point midway between the angle of the jaw and the tip of the mastoid process.

A valuable guide to the artery, at about the point of crossing of the omo-hyoid muscle, is afforded by Chassaignac's "carotid tubercle." This is the costal process of the sixth cervical vertebra, and the artery lies directly over it. It is to be found about two and a half inches above the clavicle.

*Position.*—The patient lies upon the back, close to the edge of the table, with the shoulders raised and the hand of the affected side placed behind the back. The chin should be drawn up and the head turned a

little to the opposite side. The surgeon stands upon the side exposed for operation.

**1. Ligature at the place of election (above the omo-hyoid muscle).**

*Operation.*—The position of the cricoid cartilage having been defined, and the situation of the

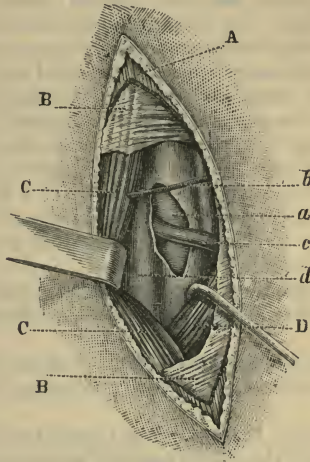


Fig. 10.—Ligature of the Right Common Carotid above the Omo-hyoid.

A, Platysma; B, cervical fascia; C, sterno-mastoid; D, omo-hyoid; a, common carotid; b, sterno-mastoid artery; c, sup. thyroid vein; d, internal jugular vein.

superficial veins made evident, an incision, about three inches in length, is made in the line of the artery, and is so placed that its centre is on a level with the cricoid cartilage (Fig. 8).

The skin and platysma having been incised (together with branches of the superficial cervical nerve), the surgeon divides the deep fascia along the anterior

border of the sterno-mastoid muscle. Along this border a communicating vein between the facial and the anterior jugular may be met with. The edge of the muscle is defined, and is followed until the omo-hyoid muscle is made out. The superior border of this structure must then be well exposed, and the angle at which the two muscles meet be clearly demonstrated. The sterno-mastoid may be drawn a little outwards, and the omo-hyoid downwards (Fig. 10).

The pulsations of the artery should now be sought for, and the vessel can usually be easily detected, as it crosses the conspicuous "carotid tubercle."

The artery is very mobile, and slips readily to and fro under the finger. If the pulse be feeble it may present the physical characters of a flat cord.

In exposing the sheath of the artery, care must be taken to avoid the sterno-mastoid vessel and the superior or middle thyroid veins.

The sheath should be opened upon the inner side, and precaution taken not to damage the descendens noni nerve.

The needle is passed from without inwards, is then threaded and withdrawn, bringing the ligature with it.

*Comment.*—If the head be turned too much to the opposite side, the sterno-mastoid is carried unduly far over the artery, and the border of the muscle may be missed.

The operation may be much complicated by the presence of large or distended veins. The internal jugular vein is of considerable size, is very thin, and is readily wounded.

The needle must be passed with great care. The artery has been transfixed by a needle. The descendens noni, the pneumo-gastric, and even the sympathetic cord, have been accidentally included in the ligature.



## 2. Ligature below the omo-hyoid muscle.

*Operation.*—The position of the patient is the same as in the previous operation. The incision is three inches in length, is in the line of the artery, and is so disposed as to commence a little below the level of the cricoid cartilage, and end a little above the sterno-clavicular joint. It follows the inner border of the sterno-mastoid muscle. Care must be taken to avoid the communicating vein from the facial, already described, and also the anterior jugular vein.

The sterno-mastoid is exposed and drawn outwards. The sterno-hyoid and sterno-thyroid muscles are likewise made evident, and are drawn inwards. The omo-hyoid, if seen, is relegated to the upper part of the wound.

It may be necessary to divide the sternal part of the sterno-mastoid, and the whole or parts of the sterno-hyoid and sterno-thyroid muscles, especially if the ligature has to be applied as low down as possible.

The inferior thyroid veins may prove very troublesome.

The sheath is opened on its inner side, as already described, and the needle is passed from without inwards.

### THE EXTERNAL CAROTID ARTERY.

*Line of the artery.*—The external carotid is represented by the upper part of the common carotid line.

Others have proposed a line drawn from the tip of the lobule of the ear to the tip of the greater cornu of the hyoid bone.

**Operation.**—The position of the patient and of the operator should be the same as is observed in the previous operation.

The "place of election" is represented by the portion of the vessel between the superior thyroid and lingual arteries. An incision, two and a half to three

inches in length, is made in the line of the artery from a point about on a level with the middle of the thyroid cartilage to near the angle of the jaw. The

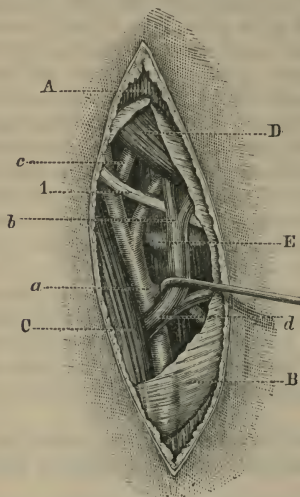


Fig. 11.—Ligature of Right External Carotid.

A, Platysma; B, cervical fascia; C, sterno-mastoid; D, digastric; E, great cornu of hyoid bone; a, external carotid at origin of superior thyroid; b, crossing lingual artery points to lingual vein; c, facial artery; d, facial and superior thyroid veins; 1, hypo-glossal nerve.

greater cornu of the hyoid bone will be about the centre of the incision.

The integuments and platysma having been divided, and any superficial vein secured, the fascia is cut through, and the anterior border of the sterno-mastoid is exposed in the lower part of the wound. This muscle must be drawn outwards. The posterior belly of the digastric should next be sought for at the upper angle of the wound, and below it the

hypo-glossal nerve should be made evident. The surgeon now seeks with the finger for the tip of the great cornu of the hyoid bone, and when this is discovered all the "points" leading to the artery are in evidence (Fig. 11).

The artery should now be exposed opposite to the level of the tip of the great cornu, and between the origins of the superior thyroid and lingual arteries. In this part of the operation care must be taken to avoid the facial and superior thyroid veins. The artery having been cleared, the needle is passed from without inwards. In effecting this, great care must be taken to avoid the superior laryngeal nerve, which courses behind the artery in this situation.

*Comment.*—This operation is somewhat difficult, on account of the complicated relations of the artery, and the fact that the branches are not always readily identified.

The artery has been ligatured above the digastric ; but the procedure is still more difficult, and is attended with several special risks.

#### THE INTERNAL CAROTID ARTERY.

The *line of the artery* is practically identical with that for the external carotid.

**Operation.**—The position of the patient and the surgeon is the same as is observed in the operations upon the common or external carotid.

The internal carotid is secured only at its commencement, close to the bifurcation, and the operation is, in all essential features, identical with that employed in ligaturing the external carotid at the place of election.

The incision is of the same length, and occupies the same position in the neck, so far as the vertical line is concerned. It is placed over the anterior edge of the sterno-mastoid (with which it is parallel), and

is, therefore, a little external to the incision required for the external carotid.

The muscle is drawn outwards. The external carotid is sought for and exposed, and then the operator brings into view the internal trunk. The former vessel is drawn inwards with a small blunt hook, the latter outwards. The digastric muscle is drawn upwards.

The sheath of the vessels is opened with care, and directly over the artery. The needle is passed from without inwards, with the same precautions as are observed in ligaturing the common carotid. Care must be taken to avoid injury to the internal jugular vein, the vagus nerve, the sympathetic ganglion, and the ascending pharyngeal artery, all of which are very close to the vessel at the seat of ligature.

#### THE SUPERIOR THYROID ARTERY.

**Operation.**—The operation is in all essential particulars identical with that employed in exposing the external carotid at the place of election (Fig. 11).

The incision is about two inches in length, and is so placed along the carotid line that the centre of the cut is on a level with the upper margin of the thyroid cartilage. The external carotid should be made evident, and the superior thyroid traced from it. The ligature may be applied close to the external carotid, between it and the hyoid branch, or, preferably, nearer to the larynx, and beyond the origin of the sterno-mastoid artery.

The superior thyroid veins, which often have a plexiform arrangement, may complicate the operation. The needle may be passed from above downwards. Care must be taken to avoid the superior laryngeal nerve.

## THE LINGUAL ARTERY.

The artery may be secured in either the first or the second part of its course. In the former situation a ligature is but very rarely applied, the place of election being in the second segment of the vessel as it lies beneath the hyo-glossus muscle, and occupies the digastric triangle.

**Ligature of the artery at the "place of election,"** *i.e.* beneath the hyo-glossus muscle.

*Position.*—The patient lies close to the edge of the table, with the shoulders raised, with the arm of the affected side passed behind the back, and with the face turned to the opposite side. An assistant must keep the chin drawn well upwards, and the lower jaw fixed. The surgeon stands upon the side to be operated upon.

*Operation.*—An incision, some two inches in length, curved, and with the convexity downwards, is made between the lower jaw and the hyoid bone. The wound commences a little below and to the outer side of the symphysis, and ends a little below and to the inner side of the point where the facial artery crosses the lower margin of the maxilla. Its centre is just above the greater cornu of the hyoid bone (Fig. 8). On the right side the incision is made from behind forwards, on the left side from before backwards.

The integuments, platysma, and superficial fascia are divided in the line of the incision. Certain superficial veins will be encountered, and some will probably have to be secured.

The next step is to fully expose the submaxillary gland. It is lodged in a special compartment of the cervical fascia. This fascia should be opened transversely over the lower part of the gland, and the organ should be cleared and brought well out into the wound by means of the finger and the handle of a

scalpel. The gland should be turned upwards on to the margin of the jaw, and be kept out of the operation area by means of a broad and well-curved retractor held by the chief assistant.

The fascia exposed by the lifting out of the salivary gland is now to be divided transversely, and in the anterior angle of the wound the posterior edge of the mylo-hyoid muscle must be sought for and defined.

The digastric tendon and the two bellies of the muscle are now to be brought into view. Around the tendon, where it is nearest to the hyoid bone, a small blunt hook with a very long handle is to be passed and held by the assistant who stands at the surgeon's side. The tendon should be drawn downwards and towards the surface.

The hyo-glossus muscle can be now easily made out, and its exposed surface freed of connective tissue. The hypo-glossal nerve must be sought for, as it crosses the muscle, and the surgeon's work be limited to the segment of muscle below the nerve (Fig. 12).

Crossing the hyo-glossus below the nerve, and parallel with it, is the ranine vein. This vein will about correspond in position with the artery, which lies beneath the muscle.

The vein and the nerve should be displaced upwards.

The hyo-glossus muscle is divided transversely to the extent of about half an inch, a little above the margin of the hyoid bone, and parallel with it.

The incision in the muscular tissue must be cautiously deepened. If the cut has been well placed, the artery will bend out into the wound and make itself evident as soon as the whole thickness of the muscle has been divided.

The needle—unthreaded—is most conveniently passed from above downwards. In the ligature the

minute venæ comites which attend the artery are no doubt included.

The gland is replaced, and the edges of the incision are adjusted by sutures.

*Comment.*—The incision may be of less dimensions than those given, or may be extended if required.

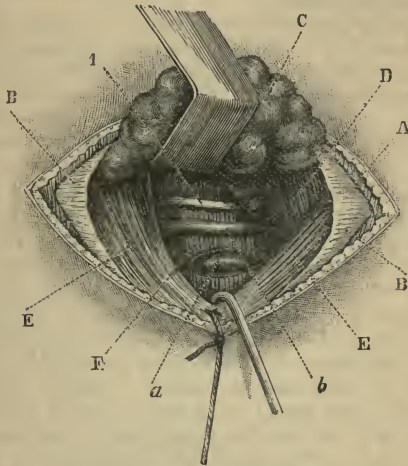


Fig. 12.—Ligature of Right Lingual Artery.

A, Platysma; B, cervical fascia; c, submaxillary gland; D, mylo-hyoid; F, digastric; E, hyo-glossus; a, lingual artery; b, ranine vein; 1, hypo-glossal nerve.

If the cut be carried too far back, the facial vein and artery are endangered. The chief difficulties of the operation depend upon the gland. I have ligatured the lingual more than sixty times (all in cases of carcinoma of the tongue), and have come to regard the state of the salivary gland as the main element of uncertainty in the procedure. This gland varies in

size, in density, and in the closeness of its attachments. These variations are probably never normal, but are incident to changes connected with cancer of the tongue.

It is most important that the gland be neither wounded nor damaged, as a temporary salivary fistula may possibly follow.

The hyo-glossus muscle varies in thickness; the part divided is, in the main, the basio-glossus, and the beginner will find the muscle much thicker, probably, than he had imagined.

#### LIGATURE OF OTHER BRANCHES OF THE EXTERNAL CAROTID.

**The facial artery** has been ligatured in the neck, through an incision similar to that employed in exposing the external carotid artery. It is, however, most conveniently secured as it crosses the lower margin of the jaw. A horizontal incision, one inch in length, is made across the course of the vessel, along, and under cover of, the inferior margin of the jaw. The artery crosses this margin at the anterior border of the masseter muscle. After the skin, platysma, and fascia have been divided, the artery should be in evidence, especially as its pulsations are readily felt. The facial vein is behind the artery, and very close to it. The needle should be passed from behind forwards.

A vertical incision in the course of the artery has been advised; but it exposes the vessel in a less convenient manner, and leaves a more conspicuous scar.

**The temporal artery** may be secured just in front of the meatus, as the vessel leaves the parotid gland. An incision one inch in length is made vertically, over the course of the vessel, between the tragus and the condyle of the jaw. The artery is



ligatured just above the root of the zygoma. It is here covered by the skin and a dense fascia. A single large vein accompanies it, lying behind the artery and overlapping it. The vessel is crossed by branches of the temporo-facial division of the facial nerve, and lies over and behind the auriculo-temporal nerve. The needle is passed from behind forwards.

The temporal bifurcates about one inch and a quarter above the root of the zygoma.

**The occipital artery** has been ligatured close to its origin, and also in that part of its course which lies beyond the mastoid process. In the first position it is reached by an incision similar to that employed for exposing the external carotid (Fig. 11). That vessel is made evident, and the hypo-glossal nerve, which winds round the occipital, is demonstrated.

In the second position a nearly horizontal incision, two inches in length, is made, which, commencing about the tip of the mastoid process, is carried backwards and a little upwards. The skin and fascia having been divided, the muscles are exposed. The posterior fibres of the sterno-mastoid must be divided; the splenius is then cut, and so much of the trachelo-mastoid as may be necessary. The surgeon now feels for the interval between the mastoid process and the transverse process of the atlas, and exposes the artery as it escapes from beneath the digastric muscle.

Two small venæ comites attend the artery. Care must be taken not to injure the veins issuing from the mastoid foramen. The needle may be passed either from above or from below.

## CHAPTER IV.

## LIGATURE OF THE ARTERIES OF THE LOWER LIMB.

## THE DORSALIS PEDIS ARTERY.

*Line of the artery.*—From the centre of the front of the ankle—the centre of the intermalleolar space—to the middle of the first interosseous space.

*Operation.*—The patient lies upon the back. The limb is straight and the heel is steadied firmly on the table. The surgeon stands to the outer side of the limb in each case, cutting from above downwards on the right side and from below upwards on the left.

An incision, one inch and a half long, is made on the line of the artery, and commences at the lower border of the annular ligament. The cut will be midway between the tendon of the extensor pollicis and the innermost tendon of the extensor communis (Fig. 13). The dorsal fascia of the foot is divided in the same line. The artery—often buried in much connective tissue—is found lying close to the bone. The ankle should be a little relaxed from the extended posture as the artery is sought for. The needle should be passed from the outer side to avoid the nerve.

*Comment.*—The inner division of the musculo-cutaneous nerve will be exposed in the subcutaneous tissue, and must be avoided. Care should be taken not to open the synovial sheaths of the two tendons between which the artery lies.

## THE ANTERIOR TIBIAL ARTERY.

*Line of the artery.*—From a point midway between the head of the fibula and the outer tuberosity of the tibia, to the centre of the front of the ankle-joint.

The artery may be ligatured at any part of its course on the front of the leg. The ligature in the lower third is the most common.

### 1. Ligature in the upper third of the leg.

*Position.*—The patient lies upon the back. The limb is straight upon the table. The foot projects beyond the end of the table, and is forcibly extended, and (with the leg) fully rotated inwards. The surgeon stands always to the outer side of the limb. The incision for the right artery is made from above down; for the left, from below up.

*Operation.*—An incision, three and a half inches in length, is made precisely along the line of the artery (Fig. 13). Its upper end will be about one inch below the head of the tibia. The deep fascia is exposed, and is divided along the same line. The interval between the tibialis anticus and extensor communis digitorum is made out. The foot is now flexed to relax these muscles. The space between them is opened up by means of the finger and handle of the scalpel. In doing this, the external border of

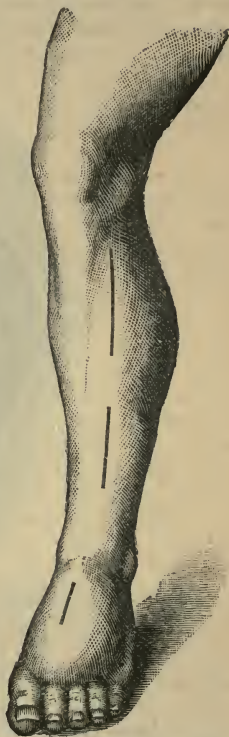

Fig. 13.—Ligature of the Anterior Tibial Artery, and of the Dorsalis Pedis.

the tibia is aimed for, and should be distinctly felt before the artery is sought. In proceeding towards this border, the extensor communis is held down by the first two fingers of the left hand, while the

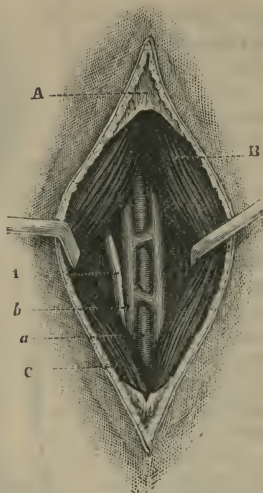


Fig. 14.—Ligature of Right Anterior Tibial Artery (upper third).

A, Fascia of leg; B, tibialis anticus; c, extensor communis digitorum; a, anterior tibial artery; b, anterior tibial veins; 1, anterior tibial nerve.

assistant holds the tibialis anticus towards the tibia with a retractor. The outer border of the tibia having been made out with the forefinger, the artery will be found to the outer side of it, lying on the interosseous membrane. It is covered and held down by a moderately dense connective tissue. The artery is now exposed, a second retractor being used to repress the extensor communis (Fig. 14).

The venæ comites will be probably enclosed in the ligature. The nerve lies to the outer side of the artery. The needle is passed from without inwards.

The nerve may not be seen. It may not join the artery until the middle third of the limb is reached. It, however, usually meets the vessel at the junction of the upper with the second fourth.

*Comment.*—The only difficulty in this operation is the finding of the gap between the tibialis anticus and the extensor communis digitorum. Not the least indication of it exists upon the surface of the deep fascia. The “white line” described by some authors is a myth, so far at least as this segment of the limb is concerned.

In seeking the proper muscular interval, the following points may be observed:—Incise the fascia precisely in the “line of the artery.” That line corresponds to the gap between the two muscles. Bear in mind that the gap may not be evident even after a liberal turning back of the fascia. The fibres of the two muscles have the same direction, and the outer edge of the tibialis anticus may overlap the border of the extensor communis. There is usually a slight septum between the two muscles, but it is limited to the upper third of the limb, or even the upper fourth or upper sixth. The gap required is to be felt rather than seen. The forefinger and handle of scalpel should alone be used. The gap lies about a finger’s breadth from the septum between the extensor communis and the peroneus longus, and about an inch or an inch and a quarter from the tibial crest.

## 2. **Ligature in the middle third of the leg.**

*Operation.*—The position is the same as in the above operation. Make an incision three inches in length along the line of the artery (Fig. 13). The deep fascia is exposed. The interval between the

tibialis anticus and extensor communis is indicated by a yellowish-white line. This is due, not to a distinct septum, but to a line of fatty tissue lodged between the two muscles. The deep fascia is divided along this line. The two muscles above-named are found lying close together. The outer edge of the tibialis

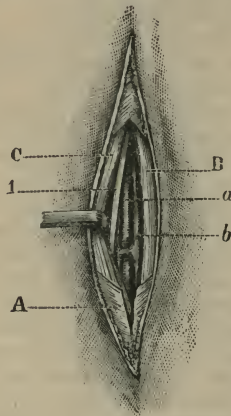


Fig. 15.—Ligature of Right Anterior Tibial (lower third).

A, Anterior annular ligament; B, tibialis anticus; C, extensor proprius pollicis  
a, anterior tibial artery; b, anterior tibial veins; 1, anterior tibial nerve.

anticus is still muscular, but the inner edge of the common extensor is now tendinous.

Flex the foot. Separate the muscles with the handle of the scalpel, keeping in the direction of the tibia. The artery is found upon the interosseous membrane, with the still deeply placed extensor pollicis to its outer side. The nerve will be exposed before the artery is reached, since it here usually lies in front of the vessel. The needle may be passed

from either side. It may be impossible to separate the venæ comites, but great care must be taken to avoid the nerve.

### 3. **Ligature in the lower third of the leg.**

*Operation.*—The position is the same, only the foot need not be so much rotated in.

An incision, two to two and a half inches in length, is made in the line of the artery, and just to the outer side of the tendon of the tibialis anticus.

The tendon must be identified beyond doubt before the operation is proceeded with. The deep fascia—here known as the upper band of the anterior annular ligament—is divided in the same line; and the space between the tibialis anticus tendon and the tendon of the extensor pollicis is defined. Both these tendons will be exposed. The artery lies between them on the front of the tibia, and embedded in a considerable quantity of fatty connective tissue. The foot is a little flexed, the extensor pollicis tendon is drawn to the outer side by a small blunt hook, and the exposed artery is easily secured.

The nerve lies to the outer side, and the needle should be passed from the nerve. As the vessel is quite superficial, the venæ comites may be separated so as to make room for the needle (Fig. 15).

*Comment.*—The operation is without difficulty if one tendon be not mistaken for another. The nerve may lie in front of the artery. The two malleolar arteries—vessels about the size of the posterior auricular—come off just above the ankle-joint.

#### THE POSTERIOR TIBIAL ARTERY.

*Line of the artery.*—A line drawn from the centre of the ham to a point midway between the inner malleolus and the heel will correspond to about the lower half of the artery. The upper half forms a slight curve inward from this line.

### 1. Ligature behind the malleolus.

*Position.*—The patient lies on the back. The knee is flexed, and the leg lies upon its outer side. The foot lies upon the table also on its outer side, and is secured in that posture by an assistant. The surgeon stands to the outer side of the limb in either instance (right or left limb).

*Operation.*—A curved incision, two inches in length, is made about half an inch behind and parallel with the margin of the inner malleolus. The knife is directed towards the tibia. The internal annular ligament is exposed, and divided over the artery. The vessels and the nerve lie in a gap between the tendons that can be appreciated by the touch. The artery having been exposed and separated from the veins, the needle is passed from without inwards.

*Comment.*—If the veins are very closely applied about the artery, they may be included in the ligature. In case of high division of the trunk, two vessels will appear, and both will require to be secured. Care must be taken not to open the sheaths of the adjacent tendons.

### 2. Ligature at the lower third of the leg.

*Operation.*—The position is the same as in the previous operation. An incision, two inches in length, is made along the line of the artery midway between the margin of the tendo Achillis and the inner edge of the tibia. The superficial and deep fasciæ are divided, together with the upper part of the inner annular ligament. The artery is found lying on the flexor longus digitorum muscle, with the nerve to its outer side. The needle is passed from the nerve. The venæ comites will have to be included if they cannot be readily separated from the artery (Fig. 16).

### 3. Ligature in the middle of the calf.

*Operation.*—The position is the same as in the preceding operations. The calf of the leg rests upon



the table on its outer side, and the surgeon leans over the limb. The incision is made from above downwards on the right side, and from below up on the left.

An incision, four inches in length, is made in the middle third of the leg, parallel to the inner margin of the tibia and three-quarters of an inch behind that

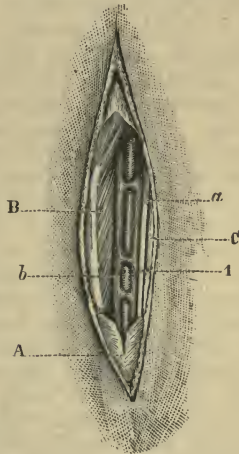


Fig. 16.—Ligature of Right Posterior Tibial Artery (lower third).

A, Fascia of leg (internal annular ligament); B, flexor longus digitorum and tendon; c, tendo Achillis; a, posterior tibial artery; b, posterior tibial vein; 1, posterior tibial nerve.

crest of bone. The skin having been divided, care must be taken not to wound the internal saphenous vein, which should be drawn aside. The deep fascia—the fibres of which are all transverse—is exposed and divided.

The soleus is now exposed, and must be divided through the length of the incision. The aponeurosis

of the muscle is cut through, together with the fleshy fibres attached to it. In making this section the knife should be kept perpendicular to the surface of the muscle. Its edge will therefore be directed towards the tibia, and its blade—in the position in which the limb is held—will be nearly horizontal. When the muscle has been divided, the outer part must be drawn well outwards by a broad retractor or retractors held by an assistant. The deep fascia that covers in the vessels and the deep muscles of the leg is now exposed. If the finger be introduced the vessel can be felt. It must be remembered that the artery lies near the outer border of the tibia. When the fascia has been divided (it is usually very thin) the fleshy fibres of the flexor longus digitorum are exposed. These fibres all run obliquely downwards. By following the surface of the muscle the vessels are reached. The veins are very conspicuous, and may hide the artery. The nerve lies to the outer side, and the needle should be passed from the nerve. It is practically impossible to separate the *venæ comites* from the vessel.

*Comment.*—This operation requires a good light.

The tissues must be carefully retracted, and all the soft parts drawn outwards. In using the retractors roughly, some fibres of the flexor longus digitorum may be torn up and made to hide the artery. If in dividing the soleus the knife be not kept towards the tibia, a too extensive division of muscle results, and the wound is unnecessarily deepened.

If the section of this muscle is made too close to the tibia, it is very easy to get the retractor beneath the flexor digitorum, and the surgeon dissecting on beneath that muscle may find himself at the interosseous membrane. The soleus at the point of section is, in a fairly developed subject, somewhat thicker than the little finger. In identifying muscle it should be remembered that the fibres of the soleus in this

situation are attached only along the narrow line formed by the inner margin of the tibia. The surgeon should not lose sight of the fact that the part for which he is aiming is in a line with the outer margin of the tibia.

#### THE PERONEAL ARTERY.

##### **Ligature about the middle of the leg.**

*Operation.*—The patient lies upon the sound side, almost upon the abdomen. The knee is a little flexed, and the leg lies upon its antero-internal surface, being held firmly upon the table by an assistant.

An incision, three and a half inches in length, is made parallel with, and immediately behind, the outer border of the fibula. The fascia having been divided, the soleus muscle is exposed. At the site of the operation the muscle will have ceased to arise from the fibula. The muscle must be drawn inwards, and any portion of its attachment to the fibula in the upper part of the wound is divided if necessary. The fibula will now be distinctly exposed. The fibres of the flexor longus pollicis are then to be severed close to the fibula, until the membranous wall of the canal containing the vessel is exposed. This is carefully laid open, and the artery is found lying against the inner margin of the bone.

The needle may be most conveniently passed from the outer side, and will probably take up also the *venæ comites*.

The muscular tissue must be well held aside by retractors, as the wound is deep.

#### THE POPLITEAL ARTERY.

The artery may be secured at its upper or at its lower part. In the middle of its course it would scarcely be exposed surgically. The vessel is here

very deeply placed, is surrounded by much fat, is covered by the vein and the nerve, gives off numerous branches, and is very close to the synovial membrane of the knee-joint.

Even as a dissecting-room operation, the ligature of the artery at its middle third has little to recommend it.

### 1. **Ligature of the lower part of the artery.**

*Operation.*—The patient is so rolled over as to rest upon the shoulder and one side of the chest, and is indeed made to lie as nearly prone as the circumstances attending the administration of an anæsthetic will permit. The limb is fully extended. The surgeon will stand to the outer side of the left limb and to the inner side of the right. In the case of either extremity the incision is made from above downwards.

A vertical incision—from three to three and a half inches in length—is made over the back of the limb, commencing opposite to the centre of the popliteal space (*i.e.* the level of the knee-joint), and extending downwards over the interval between the two heads of the gastrocnemius muscle.

The skin and superficial fascia having been divided, care must be taken not to damage the short saphenous vein and nerve. These structures will appear at the outer part of the wound, and should be drawn outwards. The deeper fascia is divided in the same vertical line.

The heads of the gastrocnemius muscle are now exposed, and the surgeon follows the interval between them.

Deep in the interval itself the large nerve to the soleus muscle (from the internal popliteal) will probably be met with, and must be drawn aside. It usually lies directly in the line of the operation.

Following the short saphenous vein, the surgeon

is guided to the popliteal vessels. This part of the operation is rendered easier by flexing the knee-joint a little so as to relax the gastrocnemius. The internal popliteal nerve is first encountered, then the vein and

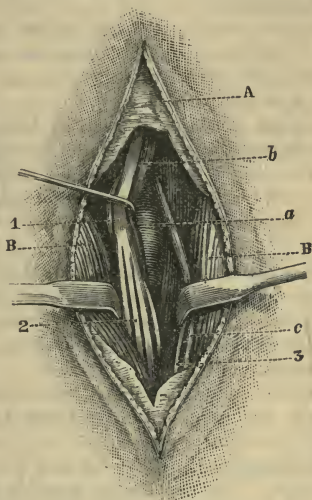


Fig. 17.—Ligature of Right Popliteal (lower part).

A, Fascia; B, gastrocnemius; a, popliteal artery; b, popliteal vein; c, external saphenous vein; 1, internal popliteal nerve; 2, muscular branches; 3, external saphenous nerve.

the artery. The two first-named structures are drawn to the inner side. The artery is cleared, and the needle is passed from the inner side (Fig. 17).

## 2. Ligature of the upper part of the artery

—This operation is carried out in the thigh. The vessel is secured close to the inner side of the femur and is reached between the semi-membranosus muscle and the tendon of the adductor magnus,

*Operation.*—The patient lies upon the back, with the hip a little flexed and the thigh fully abducted and rotated outwards. The knee-joint is bent at a right angle, and the knee and leg are thus made to lie upon the outer side.

The surgeon stands to the outer side of the extremity in either case. The incision on the right side is made from above downwards, and on the left from below upwards.

The incision is three inches in length, is commenced at the junction of the middle with the lower thirds of the thigh, and is parallel with, and just posterior to, the tendon of the adductor magnus. The position of this tendon should have been well defined (Fig. 18).

After the skin has been divided, there will probably be found in the subcutaneous fat the anterior division of the internal cutaneous nerve, which lies usually in the direct line of the operation. It should be drawn aside.

The anterior edge of the sartorius muscle is next exposed, and the whole muscle must be displaced backwards.

Upon this muscle at this point will lie the internal saphenous vein. The vessel may possibly be exposed, in which case it is drawn backwards with the sartorius.

The trunk of the internal saphenous nerve is not encountered. It lies beneath the sartorius.

The deep fascia having been well divided, the tendon of the adductor magnus is sought for, and is drawn forwards with a blunt hook. The semi-membranosus muscle is next exposed, and is drawn backwards with a retractor. The operator now seeks for the artery in the interval between the two structures. The vessel will be surrounded by much connective tissue, and is lying close to the bone. The

internal popliteal nerve is here at some distance from the vessel, and will not be seen. The vein also is not necessarily exposed. It lies posterior to the artery, and to its outer side. Indeed, as approached from this point the artery is the most superficial of the three structures named.

When the vessel has been properly exposed, the needle may be passed from below upwards.

In performing this operation care must be taken not to wound the deep branch of the anastomotica magna artery, which runs along the anterior surface of the adductor magnus tendon.

#### THE FEMORAL ARTERY.

*Line of the artery.*—The hip being a little flexed and the thigh abducted and rotated outwards, a line is drawn from a point midway between the anterior superior spine of the ilium and the symphysis pubis, to the tuberosity of the internal condyle (Fig. 18). The centre of Poupert's ligament is entirely to the outer side of the line of the vessels.

The superficial femoral may be ligatured in Hunter's canal or at the apex of Scarpa's triangle. The common femoral may be ligatured at the base of that triangle.

The only one of these three operations which is performed with any degree of frequency is the ligature at the apex of Scarpa's triangle. This is called the "place of election."

*Position.*—The patient lies upon the back, with the hip a little flexed, with the thigh abducted and rotated outwards, with the knee bent and the leg resting upon its external surface.

The surgeon stands to the outer side of the limb in either case. The incision—in the case of the right thigh—is made from above downwards, and in the case of the left from below upwards.

### 1. Ligature of the superficial femoral in Hunter's canal.

*Operation.*—The limb having been placed as already indicated, an incision three and a quarter inches in length is made along the line of the artery in the middle third of the thigh (Fig. 18).

In the layer of subcutaneous tissue the anterior

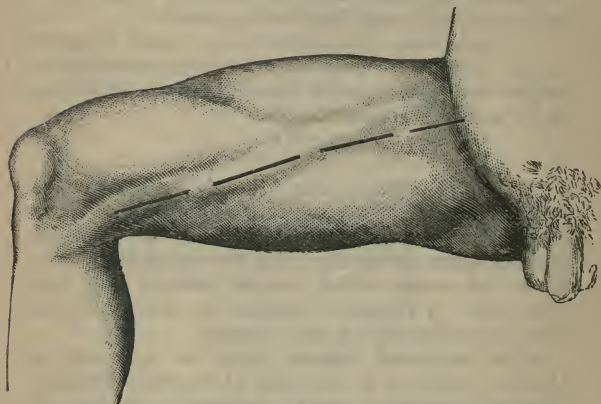


Fig. 18.—Ligature of the Right Common Femoral at the base of Scarpa's Triangle; of the Femoral at the apex of Scarpa's Triangle and in Hunter's Canal, and of the upper part of the Popliteal.

division of the internal cutaneous nerve will probably be met with, and to the inner side of it the long saphenous vein. This vessel must be drawn inwards. The fascia lata is now divided in the line of the original wound, and the sartorius is exposed and drawn inwards.

The site of Hunter's canal can now be defined, especially if the fibres of the great adductor and the lower border of the adductor longus are made prominent by fully abducting the thigh.



At this point there may be exposed, at the outer side of the wound, the nerve to the vastus internus.

The canal is opened in the line of the original wound, and the artery exposed (Fig. 19).

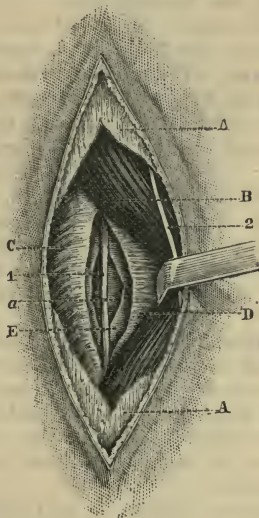


Fig. 19.—Ligature of Right Femoral Artery in Hunter's Canal.

A, Fascia lata; B, sartorius; C, vastus internus; D, fascia closing in Hunter's canal; E, sheath of artery; a, femoral artery; 1, long saphenous nerve; 2, anterior branch of internal cutaneous nerve.

The needle may be passed from either side.

In front and to the outer side of the vessel will be found the internal saphenous nerve, which is easily avoided.

*Comment.*—The cut is apt to be made too far outwards, in which case the vastus internus is exposed

instead of the sartorius, and the one muscle may be mistaken for the other.

The incision may be made too low down, and the popliteal artery be reached.

In making the skin wound carelessly the internal saphenous vein has been cut into.

The whitish tendon of the adductor magnus has been mistaken for the artery in the dead subject.

## 2. **Ligature of the superficial femoral at the apex of Scarpa's triangle.**

*Operation.*—The limb is placed in the position already indicated, and the line of the artery is marked out.

An incision, three inches in length, is made along this line as it crosses the apex of Scarpa's triangle. The centre of the wound should correspond to the apex, and the incision, therefore, will reach to within one and a half or two inches of Poupart's ligament (Fig. 18).

A large tributary of the internal saphenous vein will usually be exposed, and if it cannot be drawn easily aside it should be divided between two ligatures.

The fascia lata having been divided in the original line, the sartorius is exposed at the outer part and inferior end of the wound, its fibres running downwards and inwards.

Its inner border should be well isolated, and the whole muscle is then drawn outwards.

The operator now feels for the groove of the artery. In front of the vessel will be found branches of the internal cutaneous nerve, and deeper and to its outer side are the long saphenous nerve, and, possibly, the nerve to the vastus internus (Fig. 20).

The sheath of the vessel should be well opened, and the needle passed from the inner side.

*Comment.*—Scarpa's triangle is much smaller than would appear to be the case when the dissected region

is inspected. There may be no more than two inches of the artery left uncovered by the sartorius muscle.

In order to reach the edge of the sartorius muscle

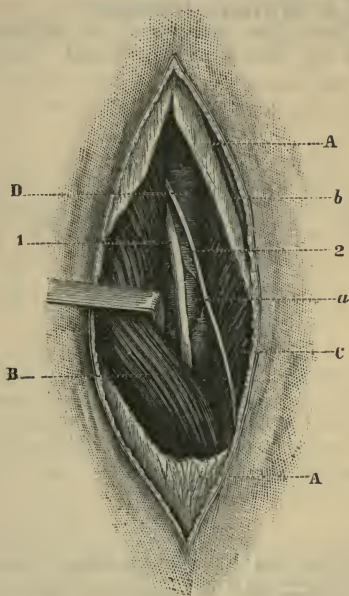


Fig. 20.—Ligature of Right Femoral Artery at Apex of Scarpa's Triangle.

A, Fascia lata; B, sartorius; C, adductor longus; p, sheath of artery; a, femoral artery; b, tributary to internal saphenous vein; 1, long saphenous vein; 2, internal cutaneous nerve.

easily the cut is often made too much to the inner side, with the result that the great saphenous vein is cut into. On the other hand, if the thigh be not placed in proper position, the incision is apt to fall too much to the outer side.

The special danger of the operation consists in the wounding of the vein in passing the needle.

### 3. Ligature of the common femoral at the base of Scarpa's triangle.

*Operation.*—The position of the surgeon and of the patient has been already indicated. An incision,

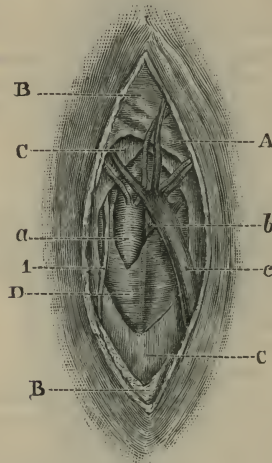


Fig. 21.—Ligature of Right Common Femoral at Base of Scarpa's Triangle. A, Line of Poupart's ligament; B, superficial fascia; C, fascia lata; D, sheath; a, femoral art.; b, femoral vein; c, int. saphenous vein; 1, genito-crural nerve.

two inches in length, is commenced a little above Poupart's ligament (*i.e.* on the abdomen), and is carried downwards parallel with the line of the artery (Fig. 18).

In dividing the layer of fatty tissue which covers the fascia lata, care must be taken not to injure any of the lymphatic glands of the region, and to avoid the superficial veins, notably the superficial epigastric and

superficial circumflex iliac. The cribriform fascia is now divided in the original line, and especial care must be taken not to wound the superficial arteries.

The crural branch of the genito-crural nerve lies upon the sheath of the artery, but upon the outer side of the vessel.

The sheath being clearly exposed and carefully opened, the needle is passed from the inner side (Fig. 21).

*Comment.*—By starting from the level of the centre of Poupart's ligament, the incision is placed to the outer side of the line of the vessels, and the vein is thus more certainly avoided. When the vein is at all distended, it is apt to overlap the artery.

#### LIGATURE OF THE ILIAC ARTERIES.

##### THE EXTERNAL ILIAC ARTERY.

*Line of the artery.*—A line drawn on the surface of the abdomen from a spot about a finger's breadth to the left of and below the navel, to a point midway between the anterior superior iliac spine and the symphysis pubis. The upper third of this line represents the common iliac, the lower two-thirds the external iliac (Fig. 22).

The patient lies upon the back, with the thighs extended and close together. The head and shoulders should be raised in order to relax the abdominal parietes a little.

The surgeon stands to the outer side of the body in dealing with either artery, and cuts from above downwards on the right side, and from below upwards on the left. His face is towards the patient's face. In slender subjects the left artery might be quite conveniently tied, as the operator stands to the right of the patient's body.

A good broad retractor is needed, together with

long dissecting forceps, and an aneurysm needle with a lateral curve.

There are two original methods of exposing the

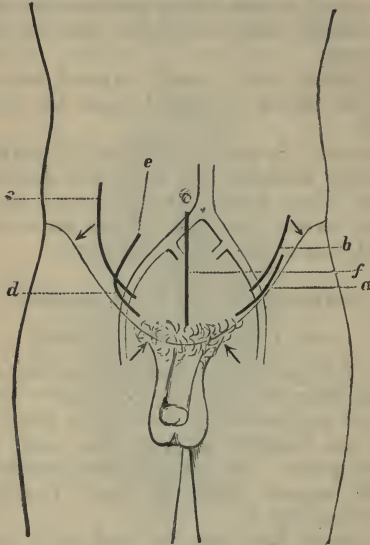


Fig. 22.—Ligature of External Iliac Artery.

*a*, Cooper's method (modified); *b*, Abernethy's method (modified). The arrows point to the anterior superior spines and the spines of the pubes.

Ligature of Common Iliac Artery.

*c*, Mott's method (modified); *d*, Marcellin Duval's operation; *e*, point  $1\frac{1}{2}$  inch to the outer side of the umbilicus; *f*, ligature of internal iliac artery (intra-peritoneal operation).

artery, both of which have been modified beyond recognition, and which are known as Cooper's operation and Abernethy's method.

1. **Sir Astley Cooper's operation** (modified).

An incision, three and a half inches in length, is

made above Poupart's ligament. The cut is commenced about one inch and a quarter to the outer side of the spine of the os pubis, and is placed three-eighths of an inch above Poupart's ligament. For the inner two-thirds of its length it runs parallel with the ligament, but for the outer one-third it curves a little upwards away from the ligament (Fig. 22, *a*).

The skin and subcutaneous tissues are cut through, and in the latter will be divided the superficial epigastric artery and vein.

The glistening aponeurosis of the external oblique muscle is now exposed, and is divided in the line of the skin incision. The parts being retracted, the surgeon now seeks for the external border of the conjoined tendon, which will be made out at the inner end of the wound.

The lower fibres of the internal oblique muscle are drawn upwards, and are divided close to their attachment to Poupart's ligament. The extent of the division corresponds to the extent of muscle tissue exposed in the wound. (The internal oblique is attached to the outer half or two-thirds of Poupart's ligament, the transversalis to the outer third only.)

The fascia transversalis is now exposed, and is divided transversely over the artery, and as far on either side of it as is necessary.

At this stage of the operation care must be taken not to wound the deep epigastric artery, which passes, between the transversalis fascia and the peritoneum, across the wound area.

The external iliac artery can now be made out. The subperitoneal tissue about the vessels should be gently loosened, and the peritoneum then with the utmost care be peeled from the artery and vein, and be pushed upwards in the direction of the umbilicus.

The fingers alone should be employed in this process.

The artery should be bared to such a height as to allow the ligature to be passed around it at a point one inch and a quarter above Poupart's ligament.

The peritoneum must be kept out of the way with the broad retractor while the artery is being exposed.

The needle is passed from within outwards.

After the ligature has been secured, the divided fibres of the internal oblique may be united to Poupart's ligament, and the rent in the external oblique aponeurosis be closed by a few points of catgut suture.

*Comment.*—The wound must be of sufficient length, and be carefully placed.

If it be made too low down, there is danger of dividing the circumflex iliac vessels; if made too high up, of cutting into the internal abdominal ring. If it be carried too far outwards, an unnecessary amount of muscular tissue is divided; and if too far inwards, the external ring and the structures of the cord may be placed in jeopardy.

The vein has been damaged in passing the aneurysm needle, and the genito-crural nerve has been included in the ligature.

The artery should be secured at least one inch and a quarter above Poupart's ligament, in order that the ligature might be well clear of the large branches given off close to the ligament, and a space be allowed for the formation of the necessary clot.

The deep epigastric artery has been accidentally cut during the operation.

2. **Abernethy's operation** (modified). — The incision is four inches in length, and is commenced one inch and a half above and to the inner side of the anterior superior iliac spine, and carried down in the direction of the external iliac artery, to a point half an inch above Poupart's ligament. This incision is shown in Fig. 22, *b*. The muscles are divided in



order, the peritoneum exposed and pushed back in the manner already described.

#### THE COMMON ILIAC ARTERY.

*The line of the artery* has already been given (page 57).

The incision may be made in many ways, but it is probable that in the future the artery will be reached by a simple incision into the peritoneal cavity through the anterior abdominal parietes. (*See* Ligature of the internal iliac artery.)

1. **The extraperitoneal operation.** — The position of the patient is the same as has been already described in dealing with the external iliac artery (page 57).

The incision on the right side may be made from above downwards, and on the left from below upwards.

(a) *Mott's operation.*—An incision from five to eight inches in length is commenced just outside the centre of Poupert's ligament, and one inch and a half above it.

It then curves upwards and outwards in the direction of the ribs, passing the crest of the ilium one inch and a half in front (*i.e.* to the inner side) of the anterior superior spinous process (Fig. 22, c).

The skin and subcutaneous tissues are divided, and the aponeurosis of the external oblique is exposed, together with—in the upper part of the incision—a portion of the muscle itself. Both aponeurosis and muscular fibres are divided in the line of the original incision. The internal oblique muscle is now reached, and is cut through in the same manner.

The transversalis muscle is in turn exposed, and its fibres are severed from one end of the wound to the other:

Between the two last-named muscles will be met the ilio-hypogastric, ilio-inguinal, and last dorsal nerves, and probably the ascending branch of the deep circumflex iliac artery. If the incision be carried high up, other dorsal (intercostal) nerves are met with.

The transversalis fascia is well exposed, and is divided along the whole length of the wound.

The peritoneum is now very carefully stripped from the iliac fascia, and the external iliac artery sought for. The serous membrane is pushed aside until the common iliac trunk is reached. The ureter is pushed aside (*i.e.* upwards and inwards) with the peritoneum.

The coat of the artery is well exposed, and the needle should be passed, on either side of the body, from right to left.

(*b*) *Marcellin Duval's operation.*—The incision is about five inches in length. It is commenced one inch and a quarter to the outer side of the spine of the pubes, a little above Poupart's ligament. The first inch and a half of the incision is parallel with Poupart's ligament. The incision is now sharply curved upwards, and ultimately follows a line which is perpendicular to the ligament, and is directed towards a point one inch and a quarter to the outer side of the umbilicus (Fig. 22, *d*).

The three abdominal muscles are divided, together with the transversalis fascia, and the artery is reached by pushing aside the peritoneum in the manner already described.

**2. The intraperitoneal operation.**—This method is carried out upon the lines indicated in the account of the ligature of the internal iliac artery. (*See* page 63.)

The same median incision in the abdominal wall is employed.

The operation is simple, and is without complication, and of the various methods of securing the vessel it must be considered to be the best, although the procedure has yet to be tested.

#### THE INTERNAL ILIAC ARTERY.

1. **The extraperitoneal operation.**—The incision employed is the same as that made to secure the common iliac artery, the procedure of Marcellin Duval being the best suited for the purpose (page 62).

The position assumed, and the general features of the operations for securing the iliac arteries, have already been dealt with in the sections on the common iliac and the external iliac.

In the present case the peritoneum is pushed aside, until the external iliac is reached. The surgeon is guided to the internal artery by following the more superficial trunk. The upper margin of the great sacro-sciatic notch is easily identified, and will serve to indicate the lower end of the artery. The passing of the ligature is difficult, and many aneurysm needles, of various sizes, and with various curves, should be at hand. The needle should be passed, on either side of the body, from within out.

#### 2. **The intraperitoneal operation.**

*Operation.*—The abdomen is opened in the middle line by an incision extending from the symphysis pubis to the umbilicus, or to a point a little above it (Fig. 22, *f*). The intestines having been pushed up and drawn aside, the area of the deep wound is surrounded by sponges, and so cut off from the peritoneal cavity. If the pelvis be well raised the intestines will gravitate towards the diaphragm.

The peritoneum over the artery is thus well exposed, and is divided to the extent of one inch and a half. The artery is followed down from the bifurcation

of the common iliac. The vein will appear to be about three times the size of the artery, and the separation of the two is a matter of some delicacy. Care should be taken that the ureter is not damaged nor accidentally included in the ligature. The many sympathetic nerve fibres which follow the artery may be avoided if the coat of the vessel be well exposed.

A good light, several broad retractors or spatulæ, long dissecting forceps, and a variety of aneurysm needles, are required. The operation should be performed with the care which is essential in every abdominal section.

*Comment.*—The advantages of this method are obvious. The vessel is easily and fully exposed, and the needle can be passed without risk to the vein or the ureter. The operation is simple, and involves but little time. The ligature can be applied accurately at the spot determined upon. The condition of the artery and of the surrounding parts can be made out; and a diagnosis confirmed or modified.

#### BRANCHES OF THE INTERNAL ILIAC ARTERY.

##### 1. **The gluteal artery.**

*Line of the artery.*—If a line be drawn from the posterior superior iliac spine to the top of the great trochanter, when the thigh is rotated in, a point at the junction of the upper with the middle third of that line will correspond to the point at which the gluteal artery emerges from the sciatic notch.

*Operation.*—The patient is rolled nearly over on to the face; the limb is allowed to hang over the edge of the table; the thigh is rotated in.

An incision five inches in length is made along the line just given. The centre of the incision should correspond to the point of exit of the artery.

After dividing the skin and superficial fascia with a few cutaneous nerves, the gluteus maximus is

reached, covered by its fascia. The incision runs parallel with the fibres of the muscle.

These fibres are separated in the line of the wound until the thickness of the muscle has been traversed. A muscular branch—from the superficial division of the artery—may here be met with, and will form a guide to the trunk.

The deep fascia between the glutei muscles is reached, and the contiguous margins of the gluteus medius and pyriformis muscles are exposed.

The gluteus maximus is now relaxed by placing the fully extended thigh upon the table. The interval between the gluteus medius and pyriformis is opened up with retractors, and the upper margin of the sciatic notch defined. The superficial division of the artery passes between the two muscles, and leads the operator's finger to the main trunk. The ligature should be applied as far within the notch as possible—almost within the pelvis—inasmuch as the artery breaks up into its two divisions as soon as it has cleared the notch.

Care must be taken to include neither the nerve nor the vein. In order to obtain a fuller view of the vessel, some fibres of the great sacro-sciatic ligament may require to be divided.

## 2. **The sciatic or internal pudic arteries.**

*Operation.*—The point at which the sciatic and pudic arteries emerge from the pelvis and reach the gluteal region is indicated by a line drawn (when the thigh is rotated in) from the posterior superior iliac spine to the outer part of the tuber ischii. The point in question is at the junction of the middle with the lower third of this line.

An incision, some four inches in length, is made obliquely across this line in the direction of the fibres of the gluteus maximus, and is so placed that its centre corresponds to the point just indicated.

The gluteus maximus is divided in the line of the wound, and the lower margin of the pyriformis muscle and the spine of the ischium are well defined.

The ligature should be passed as near to the pelvis as possible

## Part II.

### OPERATIONS UPON NERVES.

---

#### CHAPTER I.

##### INTRODUCTORY.

THE following are the operations which are considered in this connection :—

1. Nerve stretching.
2. Neurotomy, or section of a nerve trunk.
3. Neurectomy, or excision of a portion of a nerve trunk.
4. Neurorrhaphy, or suture of a divided nerve trunk.

*Nerve stretching* has been applied to nerves of all kinds, both large and small, to motor and sensory nerves, as well as to those of mixed composition.

The extensibility of nerves varies greatly, and is influenced by the size and situation of the trunk, its condition, the age and general state of the patient.

Nerve trunks are more extensile near the spinal cord than at a distance, and in the upper than in the lower limb.

The nerve is exposed at its most convenient and usually at its most superficial part, and is then clearly isolated and brought well into view.

In the limbs the joints may be so flexed as to relax the parts about the site of the operation. The

larger nerve trunks are stretched by means of the finger and thumb, smaller nerves by means of a suitable blunt hook, and the smallest cords by the aid of a probe or director.

The nerve having been replaced, the incision is closed.

*Neurorrhaphy* concerns the union of nerve trunks which have been severed by accident.

The term "immediate suture" is applied to cases in which the divided ends of the nerve are united within a short time of the accident; the term "secondary suture" to instances in which a period of time varying from weeks to months has elapsed between the receipt of the injury and the operation.

In the *immediate suture*, the wound is perfectly cleaned, the cut ends of the nerve are brought together and united by sutures. Any bruised or jagged part of the exposed nerve is cut away. The general features of the operation are identical with those now to be described.

In the *secondary suture* the steps of the procedure are as follow :—

The nerve is exposed.

The upper end of the nerve is more easily found than the lower. It is usually enlarged, bulbous, and sensitive.

The lower end, on the other hand, is usually atrophied and filiform, and is apt to be lost in cicatricial tissue.

The two exposed ends are excised. This is best done with sharp small scissors. The cut must be clean and quite transverse. The bulb on the upper end may be cut away layer by layer until a section of healthy nerve fibres is exposed. It is seldom necessary to remove the whole of the bulbous end.

With regard to the lower end of the nerve, it is only necessary to cut away the extreme end. It is



seldom necessary to remove as much as a quarter of an inch.

The two ends are united by sutures. From two to six or eight sutures will be required, according to the size of the divided nerve. The material should be either fine silk or chromicised catgut or the finest silkworm gut.

The wound is now closed.

## CHAPTER II.

OPERATIONS UPON THE NERVES OF THE HEAD AND  
NECK.

## THE TRIFACIAL NERVE.

1. **The supra-orbital nerve.**—The eyebrow is steadied by the operator's left hand while an assistant draws the eyelid downwards. An incision about three-quarters of an inch in length is made horizontally along the superior orbital margin in such a way that its centre will correspond to the supra-orbital notch. The integuments and orbicularis muscle having been cut through, the nerve is readily exposed. The vessels should be avoided.

A vertical incision exposes more of the nerve, and is simpler, but it makes a more considerable section of the muscle and leaves a larger scar.

2. **The infra-orbital nerve.**—This nerve may be exposed as it leaves the infra-orbital foramen by means of a transverse incision three-quarters of an inch in length made about a quarter of an inch below the lower margin of the orbit, and so placed as to cross the infra-orbital foramen.

After the skin, layer of subcutaneous fat, and orbicularis muscle have been divided, the levator labii superioris is exposed and must be severed in the line of the original wound. The nerve is now reached, and can be dealt with. The parts are vascular, and the view of the nerve is apt to be occluded by free bleeding.

Section of the nerve at this spot cuts off merely the terminal branches to the face.

Various methods have been devised for dealing

with the infra-orbital nerve nearer to its commencement by exposing it through the floor of the orbit.

An incision is made along or near the lower margin of the orbit, the orbital fascia is divided, and the contents of the cavity are displaced upwards by means of a thin spatula.

The infra-orbital groove is exposed, and the nerve divided as far back as possible. If the terminal part has been brought into view through the skin incision, a considerable part of the nerve might be drawn out after the division.

### 3. The trunk of the superior maxillary nerve and Meckel's ganglion.

*Operation.*—A V-shaped incision is made on the front of the cheek, so placed that the apex points directly downwards and the centre of the V is opposite to the infra-orbital foramen. The incision should form two sides of an equilateral triangle, each limb of which measures a little more than one inch (Fig. 23, B).

The knife is carried at once down to the bone, and the triangular flap formed by the soft parts is turned up over the lower lid.

The infra-orbital nerve is sought for, and isolated as it is emerging from the foramen. The bone having been cleared, a portion of the anterior wall of the antrum, measuring from half to three-quarters of an inch square, is removed with a chisel and mallet. The infra-orbital foramen will be a little above the centre of the part removed. The mucous lining of the antrum having been divided, that cavity is fully opened.

The posterior wall of the antrum is now exposed, and a portion about a quarter of an inch square is cut away with a fine chisel and mallet.

In removing the two portions of bone some surgeons use trephines—a half-inch trephine for the anterior wall, and a quarter-inch for the posterior.

The next step consists in dividing the mucous lining on the roof of the antrum, under the course of the infra-orbital canal. The bone forming the floor of this canal must be broken away from one end of the maxilla to the other. Much bleeding may be expected from the damaged infra-orbital vessels, which can seldom be surely isolated. When the posterior wall of the maxilla is reached, the white and conspicuous nerve will be hanging loose in the cavity of the antrum.

By means of long slender forceps and a director the surgeon endeavours to make out the position of the trunk as it issues from the foramen rotundum, and, if possible, the precise locality of the ganglion. The superior maxillary nerve is divided close to the foramen rotundum by a pair of slender curved scissors, and any branches which still hold the nerve in position having been divided, the whole trunk is removed with the ganglion attached.

The nerve cord removed should measure not less than one inch and three-quarters.

The antrum having been sponged out, the skin incision is united by sutures and the selected dressing applied.

#### **4. The trunk of the inferior maxillary nerve at the foramen ovale.**

*Operation.*—A square vertical flap is cut from the cheek. The two sides of the flap are represented by two vertical lines which are parallel with the anterior and posterior borders of the ascending ramus of the jaw. The base of the flap is represented by a transverse line joining the two vertical incisions about half-way down on the ramus of the jaw. The free end of the flap is a little above the zygoma (Fig. 23, A). The incisions are carried down to the bone at the free end of the flap. The zygomatic arch is exposed, and its two ends are sawn through. The piece of bone is

turned down, together with the masseter attached to it, and the soft parts covering the upper part of the ramus of the jaw.

Care must be taken not to damage the facial nerve nor the parotid duct, both of which are below

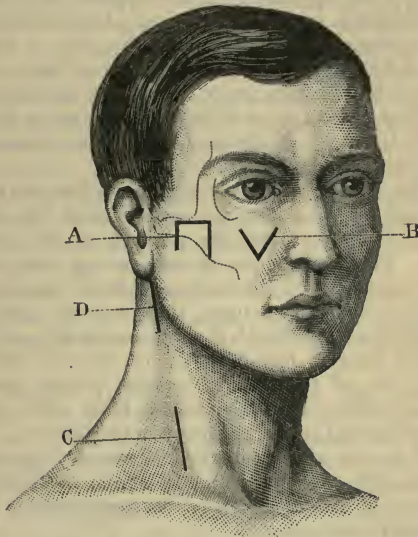


Fig. 23.—A, Neurotomy of third division of fifth nerve; B, removal of Meckel's ganglion; C, exposure of brachial plexus; D, exposure of spinal accessory nerve.

the base of the flap. The flap is drawn forcibly downwards rather than dissected up. After the bleeding has been arrested, the coronoid process is divided, and, with the attached temporal muscle, is turned upwards. The upper head of the external pterygoid muscle is separated from its attachment to

the sphenoid, and the nerve can now be exposed and divided with scissors.

The method described is that known as Krönlein's.

##### 5. **The inferior dental nerve.**

*Operation.*—The mouth is fixed well open by a Mason's gag applied upon the opposite side, or by a Hutchinson's spring mouth-prop placed between the incisor teeth. The cheek upon the side to be dealt with is held open by means of two blunt hooks, which are so drawn upon as to make the opening of the mouth at this angle as wide and as square as possible. If the tongue be in the way, it may be drawn aside with tongue forceps.

The surgeon with his forefinger defines the ascending ramus of the jaw, the substance of the internal pterygoid muscle, and the position of the spine of Spix. This latter point is more or less obscured by the attachment of the internal lateral ligament. If the tongue be drawn upon, the gustatory nerve may possibly be felt beneath the mucous membrane.

The mucous membrane is now incised along the inner side of the anterior border of the ascending ramus to the extent of about one inch. The incision is vertical and is carried down to the bone.

A narrow pointed periosteal elevator is now used to detach the mucous membrane from the jaw. The use of this instrument may be supplemented by the surgeon's forefinger.

The spine of Spix is sought for, and must be clearly defined. The periosteum must not be detached with the mucous membrane. When the spine of bone is reached, the internal lateral ligament may be divided with fine straight iris scissors, the utmost caution being used.

The nerve should now be brought into view, and be drawn forwards gently with a small blunt hook. Long-bladed dissecting forceps are required in this

stage of the operation. The nerve is exposed actually as it is entering the bone. Here the vessels are in close contact with it. A little higher up they are removed from the nerve. The inferior dental should therefore be exposed to the extent of about half an inch, and be divided with iris scissors high up. If the operator proceed too far above the dental foramen, he will come in contact with the internal maxillary artery. From a quarter to half of an inch of the cord can be excised. The higher section of the nerve is made first. No sutures are required for the wound.

The operation is very difficult and very tedious. The gustatory nerve may be mistaken for the inferior dental if the dental foramen be not clearly made out.

Much bleeding may follow the common accident of dividing the inferior dental artery.

#### 6. The gustatory nerve.

*Operation.*—The mouth having been opened and the cheek drawn aside as in the previous operation, the tongue is drawn forwards and towards the opposite side.

With the forefinger the surgeon can define the ramus of the jaw and the pterygo-maxillary ligament. The nerve can usually be felt beneath the mucous membrane behind the last-named ligament, and about half an inch behind and below the last molar tooth.

A vertical incision, about an inch in length, is made through the mucous membrane over the nerve, and therefore midway between the tongue and the gum, and at the level of the last molar.

The nerve is exposed, is drawn forwards by means of a small blunt hook, and some half-inch is excised.

#### THE FACIAL NERVE.

This nerve has been stretched close to its point of exit from the stylo-mastoid foramen for the relief of facial tic (*tic convulsif*).

*Operation.*—An incision is commenced close behind the pinna, and on a level with the auditory meatus. It is carried downwards and forwards to a point immediately below the lobule, and is then prolonged, in a direction slanting forwards, nearly to the angle of the jaw.

A small incision transverse to this is made just below the pinna. The two small flaps thus marked out are retracted. The fascia is divided, and the anterior edge of the sterno-mastoid and the parotid gland are exposed. The muscle is drawn backwards and the gland forwards by means of suitable retractors.

The posterior belly of the digastric is next exposed, and the surgeon, keeping to the upper margin of the muscle, seeks for the nerve at the point already indicated.

The nerve is raised and stretched by means of a small blunt hook. The amount of force employed is estimated at four to five pounds. It is not sufficient to raise the patient's head.

#### THE BRACHIAL PLEXUS IN THE NECK.

*Operation.*—The position of the patient should be the same as is assumed in ligaturing the third part of the subclavian artery. (See page 21.)

The plexus may be reached by a vertical incision, some three inches in length, which, commencing about half an inch above the centre of the clavicle, is continued upwards through the lower part of the posterior triangle. The wound will be parallel with the anterior border of the trapezius, and will be but little removed from the sterno-mastoid muscle (Fig. 23, c).

The integument and platysma having been divided, the external jugular vein must be sought for, secured between two ligatures, and severed. It is possible that in some instances the vein may be left untouched,



and may be merely drawn downwards and inwards out of the way. The supraclavicular branches of the cervical plexus will be encountered.

The deep cervical fascia must in the next place be divided in the full length of the incision.

If the finger be now introduced into the depths of the triangle, the cords of the plexus will be felt, and can be exposed by a little careful dissection. The clear outer border of the anterior scalene muscle should be defined. The omo-hyoid muscle will be exposed in the lower part of the incision, and should—if necessary—be drawn downwards.

The superficial cervical artery and vein cross the plexus transversely about its middle, and must be carefully sought for and protected. If the finger be passed along the plexus to the interval between the anterior and middle scalene muscles, there is no difficulty in identifying any particular cord.

#### THE SPINAL ACCESSORY NERVE.

*Operation.*—The shoulders are raised, the head is thrown a little back, and the face is turned to the opposite side.

An incision, three inches in length, is made along the anterior border of the sterno-mastoid muscle, commencing above at the tip of the mastoid process. The skin and superficial tissues having been divided, the anterior border of the muscle is exposed and the cervical fascia freely opened (Fig. 23, D).

The neck being relaxed a little, the sterno-mastoid is then drawn forcibly backwards by an angular steel retractor. This will serve to put the nerve upon the stretch, and to bring it a little nearer to the surface.

On careful examination with the finger the nerve may usually be felt at this stage. The best guide to its position is the conspicuous transverse process of the atlas, since the nerve crosses almost directly over

that process of bone. The inferior border of the digastric muscle should be defined, and passing from beneath the digastric to the sterno-mastoid across the site of the atlantoid process the nerve can readily be exposed by a little dissection.

*Comment.*—Although the nerve is very deeply placed in its course from the foramen lacerum to the sterno-mastoid, the operation is not difficult. The exposure of the spinal accessory in the posterior triangle is a simpler proceeding, but of very limited applicability, as division of the nerve will affect the trapezius only.

## CHAPTER III.

## OPERATIONS UPON THE NERVES OF THE EXTREMITIES.

1. **The median nerve.**

*Operations.*—(a) In the arm the nerve can be exposed through such an incision as is employed to secure the brachial artery, *e.g.* in the middle of the arm (page 16).

(b) At the wrist it is readily exposed through an incision, about one inch and a half in length, which is parallel with the tendon of the flexor carpi radialis and close to its ulnar side. A superficial vein or so may be cut, the fascia is divided, and the nerve can at once be brought into view.

2. **The ulnar nerve.**

*Operations.*—(a) Above the centre of the arm the nerve may be exposed by an incision parallel to the line of the brachial artery and half an inch to the inner side of it. In exposing the nerve, care must be taken to avoid injury to the venæ comites of the brachial artery, the nerve of Wrisberg, and the ulnar collateral nerve, all of which are in near association with the trunk sought for.

(b) The ulnar nerve is very conveniently exposed just above the internal condyle. The incision should be about one inch and three-quarters in length, and should lie upon the line for the nerve already given. The cut should extend to within about half an inch of the internal condyle. The nerve is found to lie along the back of the internal intermuscular septum with the inferior profunda artery, which is placed to its outer side.

(c) Just above the wrist the nerve may be exposed by means of an incision, one inch and a half long, made

parallel to the tendon of the flexor carpi ulnaris and just to its outer side. After the integuments and fascia have been divided, the nerve is brought at once into view, the artery lying to its radial side.

### 3. The musculo-spiral nerve.

*Operation.*—The nerve is most conveniently exposed at the point at which it gains the outer side of the arm. The elbow is flexed, and the arm carried a little across the patient's thorax.

An incision, from two to two and a half inches in length, is made obliquely across the outer surface of the arm at its lower third.

The centre of the incision is made to correspond with a point midway between the insertion of the deltoid and the external condyle, and its obliquity is so determined that the lower part of the incision will follow the line of the upper border of the supinator longus.

The skin and fascia having been divided, the surgeon with his forefinger seeks for the nerve as it lies close to the bone, piercing the intermuscular septum and about to cross the upper limit of the supinator muscle.

If the fibres of this muscle be exposed, the position of the nerve can be more readily determined.

The supinator muscle may be drawn outwards so as to demonstrate the groove between it and the brachialis anticus. The nerve may be carefully separated from the companion artery, and drawn forwards by means of a blunt hook.

### 4. The great sciatic nerve.

*Operation.*—The nerve is most accessible for stretching if exposed at the lower border of the gluteus maximus muscle, just as it is leaving the hollow between the tuber ischii and the great trochanter. This corresponds to its most superficial part.

The patient should be turned sufficiently over upon the face to enable the buttock to be exposed and the thigh to be extended. A vertical incision, four inches in length, is then made in the course of the nerve.

The incision should commence over the gluteal fold, and should be exactly opposite to the middle of the interval between the tuber ischii and the great trochanter. If the wound be made nearer to the tuber, there is an increased difficulty in displacing the hamstring muscles.

The centre of the incision will about correspond to the free lower margin of the gluteus maximus.

The skin and fascia having been divided, the small sciatic nerve and a few cutaneous arteries will be encountered. The quantity of the subcutaneous fat may be considerable.

The lower border of the gluteus maximus should be clearly exposed as it runs obliquely downwards and outwards.

The edge of this muscle must be drawn upwards by means of a strong and somewhat broad retractor.

The finger introduced into the wound will now encounter the hamstring muscles a little below their origin from the tuber ischii. These muscles should all be drawn inwards, their fibres having been first relaxed by bending the knee. They are retained in position by another strong and broad retractor.

The nerve should now be readily discovered and brought into view.

**5. The internal popliteal nerve.**—This nerve, the larger of the two divisions of the great sciatic, continues the direction of the main trunk, passes through the middle of the popliteal space, and at the lower margin of the popliteus muscle ends as the posterior tibial nerve.

The internal popliteal can be very conveniently

reached through the incision made for ligaturing the lower part of the popliteal artery (page 48).

#### 6. **The external popliteal nerve.**

*Operation.*—The patient lies upon the sound side with a sufficient tending to the prone position to expose well the outer aspect of the knee.

The knee-joint is extended. An incision, one inch and a half in length, is made parallel with and immediately posterior to the tendon of the biceps. The cut should be so placed that its upper half is in relation with the tendon, while its lower half is over the fibula. The skin and deep fascia having been divided, the biceps tendon is exposed.

The knee should now be a little flexed and the nerve sought, close to the point at which the tendon reaches the head of the fibula.

A narrow and unduly prominent ilio-tibial band has been mistaken for the biceps tendon.

#### 7. **The anterior crural nerve.**—This large nerve descends into the thigh in the groove between the psoas and iliacus muscles, and almost immediately below Poupart's ligament becomes flattened out and breaks up into numerous branches.

A vertical incision, two inches in length, should be made in the course of the nerve, and should commence a little above Poupart's ligament. In the superficial tissues of the region the crural branch of the genito-crural may be met with, and the superficial circumflex iliac vessels will cross the line of the wound. The fascia lata having been divided, and the hip a little flexed, so as to relax the muscles, the nerve will be found without difficulty. The edge of the sartorius muscle need not be exposed.

#### 8. **The internal saphenous nerve.**—The trunk becomes superficial opposite to the tibial tuberosity by piercing the fascia at the posterior border of the sartorius.

*Operation.*—An incision, about one inch and a half in length, made along the posterior margin of the sartorius, opposite to the tuberosity of the tibia, should bring the nerve into view.

The vein is an excellent guide to it, and as a rule the nerve will be found to be just posterior to the vein.

If the incision be made higher up, the patellar branch of the nerve—which lies in front of the vein—may be mistaken for the main trunk.

At the site of the operation some cutaneous arteries derived from the anastomotic will usually be found with the nerve.

The nerve is quite superficial at this point.

The vein when exposed should be gently drawn inwards.

## Part III.

### AMPUTATIONS

---

#### CHAPTER I.

##### METHODS OF PERFORMING AMPUTATION.

THE following are the principal procedures in amputation :—

1. The circular method.
2. The modified circular method.
3. The elliptical method.
4. The oval *or* racket amputation.
5. The amputation by flaps.

1. **The circular method.**—In this method of amputation the soft parts are divided by a series of circular cuts, made from the skin down to the bone. The tissues are not divided by one sweep from integument to periosteum, but by successive cuts, in such a way that the skin and the layers of muscle are severed at different levels.

Two forms of circular amputation are practised at the present day. They are identical in principle, and their differences, such as they are, are influenced only by locality.

A. The ordinary circular amputation is illustrated by an amputation through the arm. (*See* page 116.) After each circular cut the soft tissues are allowed to retract, or are retracted, before a second sweep is made with the knife. The result is that the wound



becomes funnel-shaped: the edge of the funnel is formed by the divided skin; the apex of the funnel, or infundibulum, by the divided bone.

B. The circular amputation *à la manchette* is adapted for parts where the covering of the bones is scanty and is composed of irregular tissues. Such a region is best illustrated by the wrist, where the bones are surrounded by many tendons, and where muscular tissue is scanty and unevenly disposed. (See page 116.)

In this method of amputating, the skin and subcutaneous tissues are dissected up in the form of a cuff, or *manchette*, and are turned back like the cuff of a coat.

The skin is divided, as in the previous operation, by a circular incision, and is then, together with the subcutaneous tissues, turned back as a cuff. The turning back of this cuff is mainly effected by the fingers of the surgeon's left hand. The skin is freed by the knife, which should always be held perpendicular to the surface. The cuff is not *dissected* up. It is gently freed and turned up.

The soft parts are then divided by a circular sweep, with the knife at the level of the retracted and everted skin.

2. **The modified circular method.**—Three important modifications need to be described: (a) In addition to the circular cut through the integuments, a vertical incision is made to join the original wound. The skin on each side of this vertical cut, and at the points where the cut joins the circle, is then reflected in the form of two imperfect skin flaps (Fig. 48, A).

(b) Two vertical incisions are made to join the circular wound. By this use of the knife, two square skin flaps can be dissected up, and the muscles, when exposed, can be divided by a circular sweep of the knife.

(c) Two very short flaps, of semilunar outline,

and of equal width and length, are dissected up. They are composed simply of the skin and the subcutaneous tissues, and consist of little more than curved incisions made across opposite surfaces of the limb, each being equal to one-half of the circumference of the limb.

The skin beyond the bases of the little flaps is then retracted as a whole, just as in the usual circular amputation. When the retraction has been carried to a sufficient extent, the muscles are divided by circular incisions in the usual way. This method is illustrated by an amputation of the thigh (page 211).

**3. The elliptical method.**—This method occupies an intermediate position between the circular operation and the amputation by a single flap.

The incision in the skin is elliptical or lozenge-shaped. The position and inclination of the ellipse vary according to the site of the amputation, and have to be carefully estimated. The skin and subcutaneous tissues are then retracted, by gliding, or by the turning up of a cuff, or by the separation of a definite flap.

The muscles are usually divided as in the circular operation. They may be, however, cut in part by transfixion, as in the disarticulation at the elbow-joint by an anterior ellipse.

The elliptical method is well adapted for amputations through certain joints.

**4. The oval or racket method.**—The skin incision takes the form of an oval with one end pointed, or of an isosceles triangle rounded at its base. The edges of the resulting wound are united in its long axis. The soft parts beneath the skin are divided down to the bone by cutting from without inwards. This operation is illustrated by some amputations at the joints of the fingers and toes.

To obtain a better exposure of a joint without loss of substance, and to afford a better covering for the

bone in the upper part of the wound, Malgaigne extended a longitudinal cut from the apex of the oval, producing thus *l'incision en raquette*, the longitudinal wound forming the handle of the "racket." This incision is also called by the French *l'incision en croupière*, and in some amputations it certainly more closely conforms to the outline of a "crupper" than to that of a "racket."

The racket, crupper, and T-shaped incisions are best illustrated by disarticulations at the metacarpophalangeal and metatarso-phalangeal lines of joints.

Amputation by the racket incision is also illustrated by certain disarticulations at the shoulder, and at the hip-joints.

**5. The flap method.**—Any flap or flaps may be composed of the integuments only, or of the integuments and the subjacent muscular tissue.

In every flap the skin must be cut longer than the muscle tissue. A flap containing too much muscular tissue is unwieldy; it is difficult to adjust, and the muscle is certain to protrude.

A flap composed of skin only is very apt to slough. This tendency is least observed in the integuments about joints, where the vascular supply of the skin is derived from many channels; elsewhere an extensive skin flap is very liable to perish for lack of blood.

In general terms, therefore, it may be said that the best flaps are those which contain muscular tissue, provided always that the skin covering the stumps be longer than the divided muscles which it contains.

**A. Varieties of flaps.** 1. Single flap.—A single flap involves a considerable sacrifice of tissues upon one aspect of the limb. It is well adapted, however, for certain instances of amputation for limited injury or disease.

As an example of amputation by single flap formed of skin only may be cited the disarticulation at the

knee-joint by a long anterior flap (page 200) ; and as examples of single muscular flaps, Farabeuf's amputation of the leg at the place of election (page 188), and the amputation at the shoulder-joint by a deltoid flap (page 137) may be quoted.

2. Double flaps may be lateral or antero-posterior. They may be equal in size, or unequal. In order to meet the cylindrical form of the limb, the flaps will be better fitting if made of U-shape than if cut square. Double flaps are generally so made as to be equal in width.

Examples of every form of double flap occur in the description of individual operations which follows.

B. *Modes of cutting flaps.*—Considered from the point of view of the manipulation of the knife, three methods of cutting flaps may be specified :—

1. By transfixion.
2. By cutting from without inwards (*par entaille*).
3. By dissection (*par désossement*).

1. In cutting by transfixion, a long knife, equal in length to one diameter and a half of the limb, is employed. The following is the description of an amputation of the arm by double flaps cut by transfixion as given in Heath's "Operative Surgery":—"The limb being held away from the trunk by an assistant, the operator grasps the biceps, with the brachial vessels and nerves, and entering the point of the knife upwards close below his thumb, passes it in front of the humerus, depressing the point as it appears on the opposite side close to the operator's fingers. With a steady sawing movement, a flap from two to three inches long is cut, with the skin left longer than the muscles. Drawing up the flap with his fingers, the operator passes the knife behind the bone, and cuts a slightly larger flap behind, bringing out the knife abruptly at the last,

Both flaps being gently retracted, the knife is swept round the bone, which is then sawn steadily through, the thumb and fingers of the left hand protecting the soft tissues."

By another method the skin incisions may be made by cutting from without inwards, and the exposed muscles be then divided by transfixion. This is illustrated by the amputation of the arm by antero-posterior flaps (page 129).

2. In cutting a flap from without inwards, the outline of the future flap is at first marked out by an incision which concerns only the skin and the subcutaneous tissues. When the skin has retracted, the muscles are divided down to the bone by cutting from without inwards.

For this purpose a small but strong knife is employed, and the edge is directed obliquely towards the bone, so that the muscular tissue shall be cut unevenly, the thinnest section being along the margin of the flap, the thickest at its base.

An illustration of this method is afforded by the disarticulation at the shoulder-joint by an external or deltoid flap (page 137).

As the skin is allowed to retract before any muscular tissue is cut, the integument of the stump must of necessity be longer than the contained muscle.

3. In separating a flap by dissection, the flap is at first marked out by a skin incision; and when the integuments have sufficiently and evenly retracted, the muscular part of the flap is cut with great care. The knife is passed obliquely through the muscle to the bone, and the soft parts forming the apex of the flap having been completely divided, the rest of the deeper tissues of the flap are very carefully dissected up or peeled off from the bone.

This method is well illustrated by the amputation

of the leg at the place of election by a single external flap.

The main points to be considered in *the selection of a method* are the following:—

1. The least sacrifice of the healthy tissues of the limb.
2. The providing of a good and permanent covering for the bone.
3. The obtaining of as small a wound area as is consistent with the proper performance of the amputation.
4. The securing of a good blood supply for the flaps or tissues which will form the stump.
5. The production of a well-adjusted cicatrix, and one so placed as to assist the healing process, secure efficient drainage, and be removed from pressure when the stump has healed.
6. The ease with which the bone can be exposed at the saw-line, and the general simplicity of the method.
7. The cutting of the main vessels transversely.

## CHAPTER II.

## AMPUTATION OF THE FINGERS AND THUMB.

**General considerations.**—The position of the phalangeal joints must be clearly defined, and the course of the digital arteries borne in mind. Care should be taken to remove as little of the digit as possible, and this applies especially to the thumb and index finger.

The slender bones of the phalanges and metacarpus should rather be divided with a fine saw than crushed roughly by bone forceps.

As the bones of the finger are comparatively large in relation to the surrounding soft parts, the flaps must be cut comparatively long. Thus a single palmar flap should be equal to one diameter and a half of the digit. If unequal dorsal and palmar flaps are cut, the palmar flap should be longer than the diameter of the digit, while the dorsal flap should be about the third of the palmar.

Flaps should be so cut that the cicatrix is removed from pressure. The scar is most conveniently located when placed upon the dorsum.

The fibrous sheaths for the flexor tendons when cut across, as in these operations, form rigid tubes along which pus may pass and enter the palm of the hand. The flexor tendons retract after division, but the sheaths do not, so there is provided in the depths of the stump a natural drainage-tube, the remote end of which leads into the palm; if no suppuration occurs, this hidden channel may produce no evil. If the stump, however, does suppurate, as is so common after crushes of the fingers, the pus can find its way with great readiness into the rigid patent fibrous tube,

and then ensues that deep-seated suppuration in the stump and in the palm which is by no means uncommon after the present series of operations.

To avoid this serious hindrance to healing, the fibrous sheath should be closed when possible after all amputations of the fingers and thumb. Over the terminal phalanx, and over the joint between the middle and terminal phalanges, there is no fibrous sheath. In front of the metacarpo-phalangeal joint it is scarcely evident. Over the first and second (proximal and middle) phalanges, and in front of the joint between these bones, the fibrous sheath is well marked, and appears as a rigid tube when cut across.

As the sheath crosses the metacarpo-phalangeal and first interphalangeal joints, it is adherent to the glenoid ligament, and is easily closed by two fine cat-gut sutures passed vertically, *i.e.* from the dorsal to the palmar wall.

Opposite the shafts of the first and second phalanges, however, there is much difficulty in effecting this closure, since the sheath is united to the periosteum, and that membrane is very thin. In these situations the periosteum should be stripped up a little from the palmar aspect of the bone, and the orifice of the tube secured by two fine sutures passed either vertically or transversely, as may appear the more convenient. This stripping off of periosteum should be effected before the bone is divided.

**The instruments required.**—Narrow, slender, and strong scalpels, the blades of which should be equal in length to about one diameter and a half of the digit to be removed. (A fine scalpel with a cutting edge one inch in length will serve admirably for most amputations of the fingers.) A fine keyhole-saw or very small Butcher's saw. Bone forceps. Dissecting and artery forceps. Tapes to hold aside the fingers. Scissors, needles, etc.



**Position.**—The surgeon sits with the patient's hand before him. The limb should be in the position of pronation while dorsal incisions and flaps are being made, and in supination during the fashioning of palmar flaps.

In the oval operation the limb may be kept pronated throughout, and disarticulation is in any case conveniently effected in that position.

The surgeon holds the finger to be removed with his left hand, placed in the supine position. An assistant is placed opposite to the surgeon. He holds the patient's hand in the required position, and keeps the sound digits out of the way.

#### AMPUTATION OR DISARTICULATION OF THE PHALANGES OF THE FINGERS.

These operations include amputations through the proximal, middle, or terminal phalanges, and disarticulations at the first or second interphalangeal joints.

Four methods will be described—

1. By single palmar flap.
2. By unequal dorsal and palmar flaps.
3. By single external flap.
4. By lateral flaps.

**1. By single palmar flap.**—Illustrated by the removal of the last phalanx at the joint.

Hold the digit between the left thumb and forefinger (the thumb upon the pulp of the digit, the forefinger on the nail). Ascertain the position of the joint. Commence the incision upon one side of the finger opposite to the joint-line and midway between the dorsal and palmar aspects of the digit. Mark out the palmar flap by an incision which involves the skin only. This flap will include the greater part of the pulp of the finger (Fig. 24). Now carry the

incision to the bone throughout, and dissect up the flap so freed, including in it everything down to the bone.

Let the patient's finger be now flexed, and make the dorsal incision. This incision is carried transversely across the finger at the level of the base of the distal phalanx. Retract the soft parts a little and open the joint.

Divide the lateral ligaments. Nothing now connects the phalanx with the rest of the finger but the

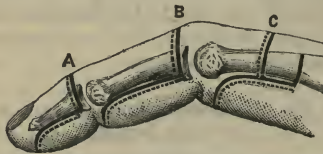


Fig. 24.—A and B, Disarticulations by large palmar flap ; c, amputation by unequal dorso-palmar flaps.

flexor profundus tendon and the glenoid ligament. Put the terminal phalanx in the position of extreme extension and divide these two structures, by cutting from below up against the base of that phalanx. No vessels require to be secured, and the tendon sheath is not opened.

## 2. By unequal dorsal and palmar flaps.

—Illustrated by disarticulation at the first interphalangeal joint.

The palmar flap should exceed a little in length the diameter of the digit at the joint-line. The dorsal flap is one-third the length of the palmar. (See Fig. 24, c.)

Ascertain the line of the articulation.

Hold the finger in the position of pronation, and mark out the flaps by skin incisions. The flaps should be squarely cut. The lateral incisions should

be placed midway between the dorsal and palmar surfaces, and should be commenced just above the joint-line.

Carry the lateral cuts to the bone. Flex the finger strongly, and carry the dorsal incision to the bone.

Dissect up the dorsal flap, including in it all the soft parts to the bone. Open the joint from the dorsal aspect.

Dissect up the palmar flap, dividing the flexor tendon at the end of the flap while the finger is in the extended position. This flap also includes all the soft parts to the bone.

When the joint is reached, divide the lateral ligaments, separate the glenoid ligament from the base of the second phalanx, and the disarticulation is completed.

The tendon sheath must be closed (page 92).

No vessels will probably require ligature. The dorsal arteries are cut at the end of the palmar flap.

**3. By single external flap.**—Illustrated by disarticulation at the first interphalangeal joint.

The flaps are fashioned as shown in Fig. 25, A.

The two longitudinal incisions are in the centre of the dorsal and palmar surfaces respectively, and both commence just above the level of the joint.

The outer transverse incision — marking the extremity of the external flap—is opposite the centre of the second phalanx. The inner transverse incision is opposite the joint.

The external flap, having been marked out, is dissected up. It contains all the soft parts down to the tendons.

The finger having been fully flexed, the joint is opened from the dorsum by cutting through the extensor expansion.

The lateral ligaments of the joint are now cut.

The finger is then placed in the position of extension, and the flexor tendons and the attachment of the glenoid ligament are divided from below up against the base of the second phalanx.

The tendons and the tendon-sheath may be dealt with as in the previous operation.

The digital vessels are divided in the transverse incisions, but will probably not require ligatures.

4. **By lateral flaps.**—Illustrated by amputation through the second phalanx.

The external and internal flaps are of equal size, and do not equal in length the diameter of the finger (Fig. 25, B). The dorsal and palmar incisions are median. The flaps are squarely cut, and contain all the soft parts down to the tendons. The flexor profundus tendon and the expansions from the flexor sublimis and extensor tendons are divided circularly at the saw-line. The bone is divided with a fine saw.

The digital arteries are cut at the extremities of the flaps.

*Comment.*—Of these four procedures, the two first-named are the best.

The third method—that by an external flap—answers well when the tissues upon the palmar and inner sides of the finger are damaged. It is peculiarly well adapted for the index finger.

The amputation by the lateral method produces well-nourished flaps and a shapely stump, but the cicatrix is inconveniently placed; and if the healing be imperfect, there is a disposition for the bone to project between the flaps.

Equal palmar and dorsal flaps produce a stump with the cicatrix at its extremity.

The oval method is not well adapted for these amputations. If applied to effect a disarticulation, the dorsal incision should commence just above the joint, and the circular incision be about the centre of

the phalanx below (Fig. 25, c). The resulting stump is clumsy, and the cicatrix is ill placed.

#### DISARTICULATION OF FINGERS AT THE METACARPO- PHALANGEAL JOINTS.

The following methods will be described :—

1. By the oval method.
2. By lateral flaps.
3. Operations for the forefinger.
4. Operations for the little finger.

**1. By the oval or racket method.** — The method here described corresponds to the French *incision en croupière*, and does not exactly accord with either the orthodox racket incision or the unmodified oval operation.

The dorsal incision is commenced just above the head of the metacarpal bone (*i.e.* opposite to its neck), and is carried down in the median line of the finger until it has passed the base of the phalanx.

The cut now divides, and its limbs sweep obliquely across each side of the root of the finger. They are joined on the palmar aspect by a transverse incision, which exactly follows the crease between the finger and the palm, and is therefore level with the free margin of the web (Fig. 25, F).

The surgeon, having made out the position of the joint, holds the finger in the prone position in his left hand. An assistant steadies the hand and keeps the other fingers out of the way.

Throughout the whole operation the limb is kept in the prone position.

The knife is entered upon the dorsum, and is carried first across one side of the root of the finger and then across the other side. The incision is completed by the transverse palmar cut. Three separate cuts with the knife are therefore required.

The incision should at first involve the skin only.

The finger is now extended to its utmost, and the palmar incision is carried to the bone, the flexor tendons being thus stretched and divided.

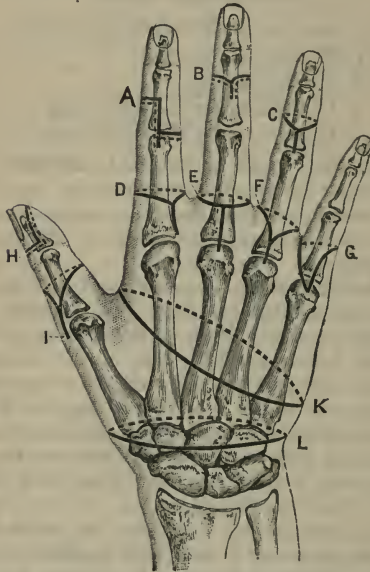


Fig. 25.—A, Disarticulation by single external flap; B, amputation by lateral flaps; C, disarticulation by oval or racket incision; D, modified racket incision for index finger; E, circular method, with vertical dorsal cut; F, incision *en croupière*; G, interno-palmar flap method for little finger; H, disarticulation by single palmar flap; I, disarticulation by racket incision; K, amputation of the fingers with their metacarpal bones; L, circular disarticulation at the wrist.

The finger being then turned to one or other side, the lateral incisions—on each aspect of the root of the finger—are carried to the bone. In this way the

digital arteries are cleanly divided, and the expansions from the lumbricals and interossei are cut.

The assistant now takes the finger, while the surgeon dissects back the flaps, as far as the joint-line, with the aid of forceps.

The wrist and finger being fully extended, the operator once more takes hold of the digit and proceeds to open the joint from the palmar aspect. He cuts the glenoid ligament transversely against the base of the phalanx, divides the lateral ligaments, and finally completes the operation by cutting the extensor tendon.

The synovial sheath of the flexor tendons may be closed.

The glenoid ligament remains in the stump.

The two palmar digital arteries will require to be ligatured or twisted.

The cicatrix is vertical—*i.e.* in the long axis of the limb.

2. **By lateral flaps.**—The flaps are of equal size and are a little rounded. The base of each corresponds to the joint-line, the free extremity of each to the level of the web. The median dorsal cut commences just above the metacarpo-phalangeal joint. The palmar median incision extends into the palm up to the level of that joint (Fig. 26, B).

The *modus operandi* is as follows:—

The surgeon marks out both the flaps by skin incisions. He then dissects up one of the flaps (that to his right) until the joint is reached. This flap includes all the soft parts down to the bone, and the digital artery is divided at its free extremity.

He then opens the joint by cutting the exposed lateral ligament, namely, that to his (the surgeon's) right.

Holding the knife vertically, with the blade directed upwards, the operator passes it across the

joint, cuts the opposite lateral ligament, and then fashions the other lateral flap (that to the surgeon's left) by cutting from within outwards.

All the tendons are divided at the joint-level, and are severed as the knife is passed transversely across the articulation.

The digital vessels are cut at the free end of each flap.

### 3. Modified operations for the forefinger.

—In order that the cicatrix may not be exposed to pressure when the thumb is opposed to the stump, or when anything is being held in the hand, the following modified procedures may be carried out:—

(a) By the racket incision, with the vertical cut placed upon the side of the index nearest to the middle finger, and with the incision carried a little farther on the radial than on the ulnar side of the digit. In the latter situation it corresponds to the web (Fig. 25, D).

(b) By unequal lateral flaps, the external flap being the larger.

(c) By the externo-palmar flap of Farabeuf. The incision commences at the joint-line, just to the radial side of the extensor tendon. It is carried down along the outer side of the dorsum nearly as far as the centre of the shaft of the phalanx. It is then made to sweep across the palmar aspect of the finger to the web. From the web it passes by the shortest route to the point at which the incision commenced (Fig. 26, A).

The large flap is dissected up, carrying with it all the soft parts down to the bone. The tendons are divided, and disarticulation effected in the usual way.

4. Modified operations for the little finger.—These have for their object the removal of the cicatrix from an exposed position.

(a) By a racket incision, with the vertical cut placed upon the side of the digit nearest to the ring-finger,



and with the incision carried a little farther on the ulnar than on the radial side of the finger.

(b) By unequal lateral flaps, the internal being the larger.

(c) By the interno-palmar flap of Farabeuf (Fig. 25, a). It corresponds to the flap already described as employed for the index finger, with the necessary difference that the position of the incisions is transposed.

*Comment.*—In all these disarticulations the head of the metacarpal bone should be spared whenever possible.

Of the two operations first described, the better is undoubtedly that by the racket incision.

The operation by lateral flaps has two great drawbacks: the cicatrix is carried into the palm, and the tissues are of necessity opened up.

The method by means of a circular incision at the level of the web, with a median dorsal cut (Fig. 25, E) affords a most excellent covering to the bone, but it provides a somewhat clumsy stump.

#### AMPUTATIONS AND DISARTICULATIONS OF THE THUMB.

In performing an operation through the first or the second phalanx, or in disarticulating at the interphalangeal joint, one or other of the methods already described may be employed (Fig. 25, H; and Fig. 26, c).

**Disarticulation at the metacarpo-phalangeal joint.**—The methods described in the previous section (page 97) apply in general terms to this disarticulation. The two most suitable operations are the following:—

1. *By the racket incision.*—The incision commences upon the dorsum, opposite the neck of the metacarpal bone, and is continued down along the line of the extensor tendon until the base of the first phalanx is passed. Here the incision divides to form the oval, the palmar cut crossing the thumb

transversely about opposite to the centre of the shaft of the phalanx (Fig. 25, 1).

The steps of the operation have been already

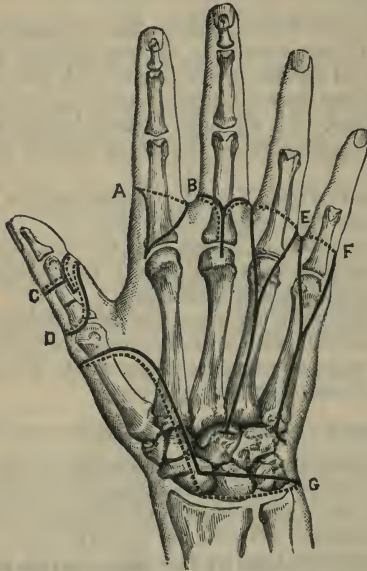


Fig. 26.—A, Disarticulation by special extero-palmar flap; B, disarticulation by lateral flaps; C, amputation by unequal dorso-palmar flaps; D, disarticulation by oblique palmar flap; E, disarticulation of the ring-finger, with its metacarpal bone, by racket incision; F, same operation upon the little finger; G, Dubrueil's disarticulation at the wrist.

described. Disarticulation may be effected from the dorsum.

The two extensor tendons are divided opposite to the joint-line. The flexor longus pollicis tendon may be severed opposite to the palmar incision, and the

extremity of the tendon may be attached to the sesamoid bones. The latter structures should be carefully detached from the base of the phalanx and are left in the stump.

The sheath for the long flexor tendon should be entirely closed. Two or more digital vessels will probably require ligatures.

2. *By oblique palmar flap.*

The dorsal incision is U-shaped, the concavity being towards the nail, and the bend of the U opposite to the joint-line.

The palmar incision is U-shaped, the convexity being towards the nail, and the bend reaching nearly to the interdigital fold in the skin. The lines of the cut follow the lateral borders of the thumb (Fig. 26, D). The flap is dissected up in the usual way. The extensor tendons are divided opposite to the joint, and the long flexor about the middle of the phalanx. The operation is finished in the manner already described.

## CHAPTER III.

AMPUTATIONS OF THE FINGERS AND THUMB, TOGETHER  
WITH PORTIONS OF THE METACARPUS.

**Instruments.**—A stout narrow scalpel with a blade about  $1\frac{1}{2}$  inch long will suffice for the oval methods, and a slender bistoury, with a cutting edge of some 9 inches, is required for transfixion operations. A fine keyhole-saw. Small retractors. Bone forceps. An elevator, if the periosteum is to be preserved. Dissecting and artery forceps. Scissors, needles, etc.

**Position.**—The surgeon sits with the patient's hand before him. The limb should be in the position of pronation. The operator grasps the finger to be removed, keeping his hand supine. An assistant, placed opposite to the surgeon, holds the patient's hand in the required position, and keeps the sound digits out of the way.

The following procedures will be described :—

- A. Partial amputations.
- B. Disarticulation of a finger with its metacarpal bone.
- C. Disarticulation of the thumb with its metacarpal bone.
- D. Amputation of several fingers with their metacarpal bones.

**A. Partial amputation.**—As much of the metacarpus should be preserved as is possible. In such partial operations the deep palmar arch is not exposed to the risk of being wounded: the attachments of certain tendons are preserved, the carpo-metacarpal synovial sacs are not opened up, and if the bone be

divided beyond its centre the synovial sacs of the flexor tendons may escape the knife in the case of the three middle digits.

The racket method should be employed. The vertical incision follows the median dorsal line of the metacarpal, while the oval cut traverses the web and follows the transverse digito-palmar crease.

The general features of the operation are the same as in the complete disarticulations. (*See infra.*)

The dorsal incision should be commenced a little way above the point at which it is intended to divide the bone.

The bone should be severed with a saw whenever possible, the soft parts being protected by a director during the passage of the instrument.

The second and fifth metacarpals should be divided obliquely, so that the end of the bone may not project unduly upon the margin of the hand.

**B. Disarticulation of a finger with the corresponding metacarpal bone.**—The racket incision is conveniently employed. The operation may be illustrated upon the ring-finger (Fig. 26, E). The joint-line having been made out, the *queue* of the racket is commenced just above the articulation, and is carried down along the dorsum of the metacarpal until the base of the knuckle is reached.

The incision here divides, and the oval wound, following the clefts between the fingers, crosses the web and terminates transversely at the digito-palmar crease in the skin.

The incision involves at first the skin only, the surgeon holding the finger and manipulating it as required with his left hand.

An assistant now takes charge of the finger while the surgeon deepens the dorsal incision and divides the extensor tendons just beyond the base of the bone.

The sides of the shaft of the metacarpal are now

bared from one end to the other, the knife being kept very close to the bone. During this step the surgeon uses his left finger to assist in the separation of the interossei from the shaft, the assistant rotating the digit as required.

The knife is carried back between the bases of the metacarpal bones (on either side of the bone to be removed), so as to divide the interosseous ligaments; the skin is at the same time retracted, so as to expose the part. To more conveniently reach the articulation, a transverse cut may be made at the end of the vertical incision (Fig. 26, E).

The operator now carries the knife forward through the tissues of the web on either side of the finger, and, the digit being fully extended, the palmar incision is carried down to the flexor tendons.

The assistant then holds the finger in the position of the extremest extension, while the surgeon lays bare the under-surface of the flexor tendons, which he ultimately divides opposite the neck of the shaft.

While the finger is still extended to the utmost, the operator exposes the palmar surface of the bone as well as is possible and as far back as is possible.

The ligaments of the joint having been divided, the finger is turned back upon the dorsum of the hand, and the last structures divided are such resisting palmar structures as still remain, together with the tendon of the extensor carpi radialis brevis.

The digital arteries are divided in the tissues of the web.

The synovial sheath of the flexor tendons should be closed with fine catgut sutures, if possible.

In the case of the *index finger* the vertical incision should be carried along the dorsum of the bone rather than along its radial side, as sometimes advised. A transverse cut should be made over the trapezoid at the end of this incision.

In removing the *little finger* with its metacarpal bone, the dorsal incision should be placed rather towards the inner side of the shaft of the bone, and from its extremity a short transverse cut may be made towards the ulnar margin of the hand (Fig. 26, F).

**c. Disarticulation of the thumb, together with its metacarpal bone.**—In this operation especial care must be taken not to wound the radial artery as it passes close to the base of the metacarpal bone to reach the palm, and not to open the joint between the metacarpal of the index and the trapezoid.

One of the two following methods may be employed :—

1. *The racket method.*—The hand is to be held in the mid-position between pronation and supination. The wrist is steadied by an assistant while the surgeon holds the thumb.

The dorsal incision commences in the *tabatière*, just above the carpo-metacarpal joint, and on the tendon of the extensor primi internodii pollicis. It runs along the dorsum of the thumb, keeping nearer to the external than the internal border of the metacarpal bone.

The oval encircles the head of that bone and crosses the palmar aspect of the digit on a level with the free edge of the web as displayed when the thumb is abducted.

The procedure is the same as that already described for the finger.

The sheath of the flexor tendon should be closed if possible.

The arteria princeps pollicis, or its two collateral branches, will be found divided on the palmar aspect of the wound and will require a ligature.

The two dorsal arteries of the thumb are small and may not require to be secured.

2. *By palmar flap.*—This operation may be

rapidly performed, but it is decidedly inferior to the method just described.

“An assistant should grasp the finger while the surgeon abducts the thumb. The knife, introduced

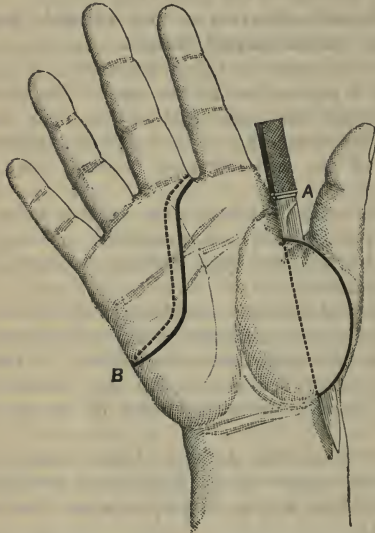


Fig. 27.—A, Disarticulation of the thumb with its metacarpal bone by palmar flap; B, amputation of the three inner fingers with their metacarpal bones.

into the centre of the web, and passed towards the trapezium, beneath the muscles of the thumb, is made to emerge at the base of the metacarpal bone, and then by cutting outwards a rounded flap is formed, comprising the whole of the tissues of the ball of the thumb (Fig. 27, A). The extremities of this flap are now united by a straight incision across the dorsal



aspect, the thumb being still held strongly abducted, the remaining soft tissues are divided, the joint opened on the inner side, and the disarticulation completed.

“The flap may be formed by introducing the knife at the base of the metacarpal bone, and bringing it out at the centre of the web. This is preferable on the left side” (*MacCormac*).

**D. Amputation of several fingers, together with their metacarpal bones.**—These operations cannot be systematised.

They concern for the most part cases of crush of the hand and of frost-bite, in which the least amount of tissue is sacrificed, and in which definite flaps can seldom be cut or definite incisions followed.

In amputation of the two inner fingers and their metacarpal bones, the racket method may be employed.

In amputation of the three inner fingers with their metacarpal bones the knife may follow the lines shown in Fig. 27, B.

In amputation of all the fingers with their metacarpal bones a short palmar flap may be made. The lines of the incisions are shown in Fig. 25, K. The dorsal wound is concave forwards, the palmar wound convex.

## CHAPTER IV.

## DISARTICULATION AT THE WRIST-JOINT.

**Instruments.**—A narrow amputating knife, with a stout handle, and a blade from three to four inches in length. A scalpel. Dissecting and artery forceps, scissors, needles, etc.

**Position.**—The surgeon sits facing the patient's fore-arm, which is abducted horizontally, and with the hand pronated. An assistant steadies the limb, draws up the soft parts, and takes charge of the flaps as they are formed. He can also manipulate the hand if required.

The following methods of disarticulating will be described :—

1. By elliptical incision.
2. By long palmar flap.
3. By external flap (Dubrueil's operation).

**1. The elliptical method.**—The highest point of the ellipse is on the dorsum, a little to the inner side of the middle line, and half an inch below the line of the wrist-joint.

The lowest point is on the palm, in a line with the middle finger, and about two inches below the level of the highest point.

In forming the ellipse between these two points the incision on the ulnar side should pass between the pisiform bone and the base of the fifth metacarpal, while on the radial side it should cross the carpo-metacarpal joint of the thumb (Fig. 28, B).

The surgeon, holding the subject's hand in the supine position, marks out the palmar part of the

ellipse, commencing the incision on the left side (the surgeon's left) of the hand.

The operator now pronates the hand and marks out the dorsal segment of the ellipse, the assistant at

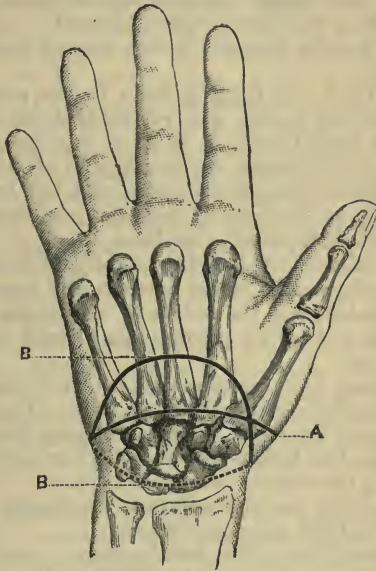


Fig. 28.—A, Palmar incision in the circular disarticulation at the wrist; B B, Incisions in the elliptical disarticulation at the wrist.

the same time drawing up the integuments at the back of the hand.

The first incision concerns the skin and the subcutaneous tissues only.

The integuments on the dorsum are separated up until the styloid processes and the joint-line are cleared,

The surgeon, holding the pronated hand in the position of forced flexion, now divides in order the left lateral ligament, the extensor tendons and posterior ligament, and the right lateral ligament. The tendons are divided immediately opposite to the articulation, which is thus freely opened.

The anterior ligament is now severed close to the carpus.

The hand, still hanging down in the position of pronation and flexion, is so rotated that one or other border is turned forwards so as to face the surgeon. While in this position the lateral parts of the ellipse are deepened towards the palm, and the two bony eminences at the root of the palm are cleared, the knife being kept close to the bone.

The instrument is held vertically, with its point downwards, and is passed between the mass of the flexor tendons and the hollow of the carpus. With the knife held in this position the "carpal canal" is cleared out.

Nothing now remains but to divide the flexor tendons and the surrounding soft parts. The tendons are dragged upon and are cut obliquely from within outwards, the knife—now held horizontally—finally following the existing cutaneous incision.

When the wound is adjusted, the cicatrix appears as a curved line upon the dorsum.

*Hæmorrhage.*—The radial artery is cut in disarticulating, and is found divided at the outer extremity of the dorsal wound. It is severed above the origin of the branches to the thumb and index finger.

In the inner portion of the palmar flap the ulnar artery is divided as it is forming the commencement of the superficial palmar arch.

Deeper in this part of the palmar flap the deep branch of the ulnar artery is cut.

In the outer segment of the palmar flap the superficialis volæ will be found severed.

The deep palmar arch and the greater part of the superficial arch are of course removed with the hand.

2. **By a long palmar flap.**—The flap is U-shaped. It commences half an inch below the radial styloid process, and ends half an inch below the tip of the corresponding process of the ulnar. The outer limb is directed towards the gap between the index and middle fingers, the inner limb towards the web between the little and ring fingers.

The almost transverse extremity of the flap reaches nearly to the middle of the metacarpus. The dorsal incision is carried straight across the back of the limb from one extremity of the palmar flap to the other. It will therefore cross the carpus.

A stout knife with a blade some three inches in length is required.

The operator grasps the patient's hand and holds it in the position of extension and supination.

Entering the knife half an inch below the styloid process to his left, he carries it across the palm, in the direction indicated, to the corresponding point on the other side of the hand, and thus marks out the palmar flap.

An assistant now takes the hand and retains it in the same position while the operator proceeds to dissect up the great flap. This should include all the soft parts down to the flexor tendons. A considerable portion of the muscles of the thenar and hypothenar eminences will consequently form a part of the flap, and the limb of the superficial palmar arch will be divided at its free end.

The flap should be dissected up to the level of the radio-carpal joint, care being taken to clear the bony prominences in the palm of the hand.

The surgeon now takes the hand and holds it in

the pronated position, while the assistant draws up the skin on the back of the limb. The dorsal incision is made. The integuments are dissected up to the joint-line, and the extensor tendons and the ligaments of the wrist are divided precisely as in the previous operation.

Nothing now connects the disarticulated hand with the fore-arm but the mass of the flexor tendons and the tissues about them.

These are drawn upon and divided by a vigorous transverse cut made from above downwards—*i.e.* from dorsum to palm—care being taken that the palmar flap is held well out of the way at the time.

The palmar flap should never be cut by transfixion. The bony prominences in the palm render such a method difficult, and an unduly scanty flap is apt to result.

*Hæmorrhage.*—The vessels are divided as in the previous operation. The deep palmar arch and the transverse part of the superficial arch are removed with the hand.

**3. Dubrueil's operation by an external flap.**—The incision is commenced on the back of the wrist at the junction of the outer with the middle third, and at a point half a centimetre below the line of the wrist-joint. It is thence carried downwards towards the thumb upon the dorsal aspect of the limb, and is made to cross the first metacarpal bone transversely about its middle. The incision now follows the inner part of the thenar eminence, and terminates at a point diametrically opposite to the point at which it was commenced. This represents the outline of the external or thenar flap (Fig. 26, c).

This flap is now dissected up to its base, and is made to include as much of the thenar mass of muscle as is possible.

The skin and soft parts internal to the flap are

then divided in a circular manner through an incision on a level with the base of the flap.

Disarticulation having been effected, the operation is complete.

The thenar flap is brought transversely across the face of the radius and ulna, and is there secured.

*Comment.*—Of the operations described, the best procedure is undoubtedly the elliptical method. The cicatrix falls upon the dorsum, the bones are well covered, and the free end of the stump is made up of the tough and well-nourished tissues of the palm. The styloid processes are well protected.

The disarticulation is always more readily effected from the dorsum. In dissecting up the palmar tissues it is not easy to avoid removing the pisiform bone with the soft parts. It will often be found more convenient to include it in the tissues of the palmar flap, and to subsequently remove it by dissection.

In planning any operation, account must be taken of the very great retractibility of the dorsal tissues, and of the difficulty of properly covering the radial styloid process.

The lower ends of the radius and ulna should not be sawn off.

Disarticulation may be effected by the circular method. The lines of the incision are shown in Fig. 25, L, and Fig. 28, A.

## CHAPTER V.

## AMPUTATION OF THE FORE-ARM.

**Instruments.**—An amputating knife, with a blade four to five inches in length. A stout scalpel. An amputating saw. Retractors (the linen retractor used to protect the soft parts during the sawing of the bones may have three “tails,” the middle and narrowest slip being passed through the interosseous space). Pressure, artery, and dissecting forceps; scissors, needles, etc.

**Position.**—The arm is abducted, and the surgeon stands to the right of the limb in all cases—*i.e.* to the outer side of the right fore-arm and the inner side of the left.

The following *operations* are described :—

1. Circular method.
2. Equal anterior and posterior flaps.

The former is better adapted for the lower third of the limb; the latter for the upper two-thirds.

1. **The circular method** (*through the lower third*).—The circular cut in the skin will be placed at a distance below the future saw-line, equal to the antero-posterior diameter of the limb at that line.

The patient's limb is held in the supine position.

The surgeon, passing his hand beneath the patient's fore-arm, commences the incision on that border of the limb which is the nearer to him, and uses the heel of the knife for the purpose.

The knife is now drawn from heel to point across first the flexor and then the extensor aspect of the limb, until it reaches the point at which the incision was commenced.



During this manœuvre the operator grasps the fore-arm above the incision with his left hand.

A cuff of skin is now dissected up, and turned back, and this retraction of soft parts should be continued until the level of the future saw-line is reached.

Throughout, the limb is kept with the hand supine, but the elbow should be flexed so as to render the fore-arm vertical while the posterior part of the *manchette* is being dissected up.

The fore-arm being extended, with the hand supine, the soft parts on the flexor side of the limb are transfixed by the knife, which is so passed transversely across the fore-arm that its point is made to enter and emerge at the level of the retracted skin. The knife should follow the curve of the bones, so as to take up as much of the tissues on the front of the limb as possible. It is now made to cut its way abruptly out, so that the muscles and tendons shall be divided transversely a little below the future saw-line.

The soft parts on the extensor side of the limb are transfixed and divided in precisely the same way, the limb being still kept in the same position during the process.

While the flexor tissues are being cut, the hand is kept a little extended; and while the tissues on the extensor side of the limb are being cut, the hand is a little flexed.

The soft parts might be divided—as is usual—by a circular sweep with the knife at the level of the retracted skin; but as the structures to be severed are for the most part tendons, they are much more easily and more cleanly divided by cutting from within outwards, as advised.

With a scalpel any remaining soft parts are now separated from the bones until the saw-line is well exposed, and at this level the interosseous membrane is divided transversely.

The retractor having been applied, the bones are sawn through. In dividing the bones it is convenient to have the hand placed in the mid-position between pronation and supination, and to saw the radius first and then the ulna.

*Hæmorrhage.*—On the face of the flexor part of the wound are found divided the radial and ulnar arteries.

Behind the interosseous space, and between the superficial and deep muscles, the posterior interosseous artery may be found bleeding, and in front of that membrane the anterior interosseous and possibly the median.

2. **By equal antero-posterior flaps** (*through the upper two-thirds*).—The base of each flap should be equal to half the circumference of the limb at the level of the saw-line.

The length of each flap should be equivalent also to half the circumference after the usual allowance has been made for retraction.

The flaps are U-shaped, and the lateral incisions correspond to the lateral margins of the limb. The anterior flap will contain the supinator longus and the flexor muscles. The posterior flap will contain the extensors. In the radial incision the vertical cut will involve the two extensors of the radial side of the carpus. In the lateral ulnar wound the flexor profundus and the flexor carpi ulnaris are found to be marked by the vertical incision.

The hand having been supinated, the anterior flap is marked out by a skin-cut. In the case of the right limb the knife is entered at the commencement of the ulnar incision, is carried down along the ulnar border, and is then made to sweep transversely across the flexor surface of the limb. The knife being withdrawn, its point is entered at the upper end of the radial incision, and is carried down along the radial

border of the fore-arm to meet the first incision. The flap is marked out therefore by two cuts, and the incision is commenced on the side more remote from the surgeon. In the left limb the knife is first entered upon the radial border.

The elbow being now flexed so that the fore-arm is vertical (the hand being still supine), the posterior flap is marked out in the integuments only.

The skin thus fashioned for the future flaps is allowed to retract.

The fore-arm is now again held horizontally, with the elbow a little flexed and the hand still supine.

The operator lifts up the tissues on the front of the limb with the fingers on the left hand, and proceeds to transfix.

The knife is entered at the angle of the wound nearest to the surgeon, and is made to follow as accurately as possible the curves of the bones and the interosseous membrane. Its point should just graze the bones as it moves across the limb.

While the assistant extends the hand, the surgeon cuts a muscular flap from within outwards, bringing the knife out sharply just at the level of the retracted skin.

The posterior flap is cut by transfixion in the same way, the limb being held in the same posture. It is difficult to insinuate the knife behind the ulna, and its movements in that position must be assisted with the left fingers.

While the muscular tissue is being divided the assistant flexes the hand.

The two flaps are now drawn up to the level of the saw-line, and the remaining soft parts are divided at that level to fully clear the bones.

The threefold retractor having been applied, the bones are sawn in the manner already described.

Some surgeons advise that the median, ulnar, and

radial nerves should be resected from the anterior flap.

*Hæmorrhage.*— The radial artery will run the whole length of the anterior flap, and be cut near its outer border on the inner side of the supinator longus. The ulnar artery will be cut shorter and will be in front of the bone and between the flexor sublimis and flexor profundus digitorum. The anterior interosseous vessels will be divided immediately in front of the interosseous membrane. The posterior interosseous artery will be cut long and will be found between the superficial and deep muscles.

## CHAPTER VI.

## DISARTICULATION AT THE ELBOW-JOINT.

**Instruments.**—An amputating knife some six to seven inches in length for transfixion. A stout knife with a cutting edge of four to five inches, when flaps are cut from without inwards, and for disarticulating. A scalpel; retractors; pressure, artery, and dissecting forceps; scissors, needles, etc.

**Position.**—The arm is abducted to a right angle. The surgeon—except in the first instance below specified—stands to the right of the limb in all cases, *i.e.* to the outer side of the right elbow and the inner side of the left.

One assistant, standing to the operator's left and near the patient's shoulder, steadies the arm, retracts and supports the flaps, etc. The other, to the surgeon's right, holds and manipulates the hand and fore-arm.

The following *methods* will be described:—

1. The elliptical.
2. The large anterior flap.

**1. Elliptical method.**—This operation may be performed in one of two ways:—

A. *Anterior ellipse (Farabeuf).*—The figure described by the incision is rather lozenge-shaped than elliptical.

The highest point of the ellipse is behind, over the prominence of the olecranon. The lowest point is on the anterior surface of the limb, over the eminence formed by the supinator longus, and at a spot a little above the middle of the fore-arm (Fig. 29).

In performing this operation the surgeon may conveniently stand to the left of the limb to be

removed, *i.e.* to the inner side of the right fore-arm and the outer side of the left. The elbow will be on his right hand, the hand on his left.

The elliptical incision may be made in one sweep from olecranon to olecranon.

Holding the wrist in his left hand, and flexing the elbow a little, the surgeon so rotates the limb as to turn the farther side of the fore-arm towards him. (This will be the radial margin on the right limb, and the ulnar margin on the left.)

He carries the incision downwards from the olecranon to the lower extremity of the ellipse.

As the knife crosses the anterior aspect of the limb, the fore-arm is kept extended, with the hand supine.

The elbow is once more flexed, and the limb is now so held as to bring uppermost the border of the fore-arm nearest to the surgeon.

The knife is carried upwards across the border to terminate at the point of commencement over the olecranon.

The incision involves the skin only.

An assistant now takes the fore-arm, while the surgeon separates and retracts the integuments a little all round.

This retraction will shorten the anterior flap about one inch and a half.

The elbow being a little flexed, and the hand supine, the operator pinches up the soft parts on the flexor aspect of the bones with the left hand, and then transfixes the limb transversely. The knife should be entered as near the joint as possible, and should pass close to the anterior surfaces of the radius and ulna.

The muscles are cut obliquely and an anterior flap is thus formed.

An assistant draws up this flap, and the surgeon, keeping his knife close to the bones and almost flat,

cuts upwards until the anterior aspect of the joint is reached.

Nothing now remains but to disarticulate and to divide the triceps and any tissues which have escaped division along the lateral and posterior aspects of the limb.

A curved cicatrix on the posterior aspect of the limb results.

*Hæmorrhage.* — In addition to muscular branches, divided with the cut muscles, the radial and ulnar arteries will be found severed near the free end of the anterior flap; and on the deep surface of that flap the interosseous artery, and possibly the posterior ulnar recurrent, may require ligation. Bleeding may also occur from the terminations of the superior profunda in front of the external condyle, and of the inferior profunda behind the inner condyle.

B. *Posterior ellipse (Soupard).*  
—In this operation the highest point of the ellipse is in front and the lowest point behind. The flap is therefore taken from the posterior aspect of the limb (Fig. 30).

“The arm being semi-flexed the point of the knife is entered nearly an inch below the internal condyle of the humerus, curved upwards over the front of the fore-arm nearly to the line of the joint, and downwards again to a point an inch and a half below the external condyle. The arm being then forcibly flexed, the ellipse is completed on the back of the fore-arm by a

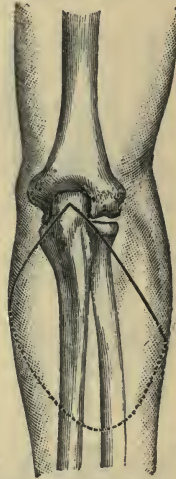

Fig. 29.—Disarticulation at the elbow-joint by the anterior ellipse method.

curved incision passing nearly three inches below the tip of the olecranon.

“The cuff thus marked off is rapidly dissected upwards as far as necessary, when the muscles of the front of the fore-arm are cut about half an inch below, and the ulnar nerve as far above the joint, and disarticulation is effected from the outer side.

“The brachial artery is divided, and other vessels may be severed as in the circular operation.

“The wound is closed transversely, and leaves a small curved cicatrix in front of the bone” (*Ashhurst*).

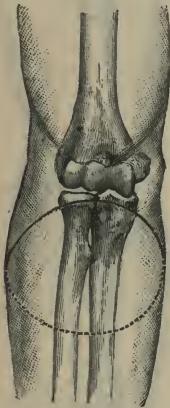


Fig. 30. — Disarticulation at the elbow-joint by the posterior ellipse method.

**2. By large anterior flap.**—The base of the flap should represent more than half the circumference of the limb, and should be U-shaped.

The anterior incision should commence three-quarters of an inch below the line of the joint on the inner side, and one inch and a half below that line on the outer side. The extremity of the flap (the curve of the U)

should reach some three inches below the articulation.

The posterior incision is made to connect directly the extremities of the anterior incision (Fig. 31).

The position of the operator has been already indicated (page 121). The anterior flap should be marked out by a skin incision, the limb being at the time extended and the hand supine, and the knife should be entered upon the border of the fore-arm most remote from the surgeon.



The muscular part of the flap is cut by transfixion, precisely as in the anterior elliptical method.

The flap is drawn up and the posterior incision made.

The operation is completed as in the disarticulation by the anterior ellipse, and the blood-vessels are divided in the same manner.

Many surgeons cut a short posterior flap about one-half or one-third the length of the anterior flap.

*Comment.* — Several methods of disarticulating at the elbow-joint have been advised or practised in addition to those described. Among these may be mentioned the amputation by lateral flaps, the external being the larger; by antero-posterior flaps, the anterior predominating; by a racket incision, the *queue* of which is over the olecranon; by the circular method and by a single external flap.

The elliptical method — and notably the amputation by the anterior ellipse — is on the whole the best, provided, of course, that the tissues upon the flexor side of the limb are sound.

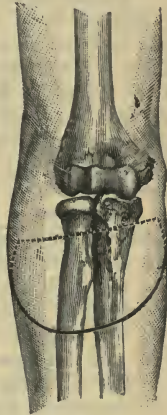


Fig. 31.—Disarticulation at the elbow-joint by anterior flap.

## CHAPTER VII.

## AMPUTATION OF THE ARM.

**Instruments.**—An amputating knife equal in length of blade to one and a half times the width of the limb for transfixion. A knife with a still longer blade for the circular method. A stout knife, some four inches in length, with which skin flaps may be marked out and muscles separated from the bone. An amputating saw. Some seven or eight pressure forceps. Artery and dissecting forceps. Scissors, retractors, etc.

**Position.**—The patient lies upon the back and near to one or other edge of the table, according to the side of the amputation.

The limb is horizontal and abducted until it is at right angles to the body.

The surgeon stands to the outer side of the right arm and the inner side of the left.

The following two *methods* will be described. The first-named is considered to apply especially to the lower half of the arm, the second to the middle of the limb:—

1. The circular method.
2. By antero-posterior flaps.

1. **The circular method** (*lower half of the limb*).—Fixing the arm with his left hand, the surgeon makes a circular sweep through the skin. To effect this he passes his hand beneath the limb, and bending his wrist over the patient's arm, he commences his incision with the heel of the knife, upon the surface of the limb nearest to himself (*i.e.* upon the outer surface of the right arm and the inner surface of the left).

The assistant holding the fore-arm so rotates the limb as to make the tissues meet the knife.

The cut can be made to extend with one sweep around about three-fourths of the limb. The circle is completed by withdrawing the knife, and having entered it again at the point of commencement, the surgeon now cuts in the opposite direction—*i.e.* towards himself—and so incises the small tract of skin yet undivided (Fig. 32, A).

The incision involves the skin only, and care must be taken that the knife does not pass deep enough to wound the brachial artery.

The integuments are now separated, especially along the lines of the intermuscular septa, and the skin thus freed is well and evenly retracted by the assistant.

No cuff of skin should be turned back. In a stout or muscular arm the proceeding is almost impossible unless a lateral incision be made.

When the skin has been sufficiently drawn up, the biceps is divided about a thumb's-breadth below the edge of the retracted skin.

With a circular sweep of the knife the remaining muscular tissue is divided down to the bone, as close as possible to the edge of the divided integument.

This circular cut is made in the same manner as the first incision in the skin.

The assistant still further retracts the divided soft parts, until they appear as a kind of fleshy cone. A second circular incision is now made at the base of this cone, at the level of the now fully retracted integument. The knife is carried down to the humerus.

The bone is now cleared, the periosteum divided, the retractors are applied, and the shaft is sawn through.

Before applying the saw, it is well to see that the

musculo-spiral nerve is cleanly severed. It is apt to escape division, as it lies in the bony groove, and to be mangled by the saw.

The sutures are so applied that the cicatrix

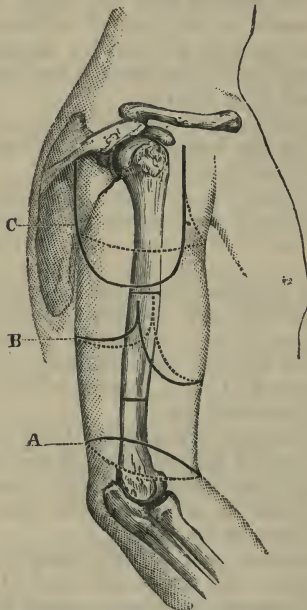


Fig. 32.—A, Circular (inclined) amputation of the arm; B, amputation of the arm by antero-posterior flaps; C, amputation at the shoulder-joint by deltoid flap.

becomes vertical (antero-posterior), to ensure good drainage.

To secure a terminal cicatrix, the circular incision should be not quite horizontal, but should incline

lower down upon the antero-internal aspect, as shown in Fig. 32, A.

*Hæmorrhage.*—The vessels are divided upon the face of the stump—the brachial to the inner side with the median nerve; the superior profunda upon the postero-external aspect of the bone with the musculo-spiral nerve; the inferior profunda to the inner side of the brachial with the ulnar nerve. In addition to these three vessels several muscular branches will need to be secured.

2. **By antero-posterior flaps** (*middle of the limb*).—The base of each flap should be equal to one-half the circumference of the limb.

The length of the anterior flap should equal that of the diameter of the limb. The posterior flap should be half the length of the anterior.

Both are U-shaped, and the incisions defining them are commenced just below the future saw-line (Fig. 32, B).

These incisions are so disposed that the brachial artery comes in the posterior flap, and great care must be taken that the division between the flaps is not just over the vessel, which would in such case probably be split in cutting the flaps by transfixion.

An assistant, grasping the limb by the elbow and wrist, flexes the fore-arm and rotates the extremity as required.

These incisions concern the skin only.

The skin having been evenly freed all round, the anterior and posterior flaps are cut by transfixion, the edge of the knife being brought out at the level of the retracted skin.

As already said, care must be taken not to transfix nor to slit the brachial artery.

The bone having been freed up to the saw-line, and the flaps well drawn up, the humerus is divided, care being taken of the musculo-spiral nerve.

*Hæmorrhage.*—Some muscular arteries are divided in the anterior flap. In the posterior flap the brachial, the superior profunda, and the inferior profunda are found severed.

**Comment.**—The circular operation is peculiarly well adapted for the lower half of the arm, and is undoubtedly the best procedure for amputation in that situation. The method is not applicable to the upper half of the limb, owing to the freedom of the muscles and their consequent ready retraction. It is here, therefore, that the flap operation proves so serviceable.

## CHAPTER VIII.

## DISARTICULATION AT THE SHOULDER-JOINT.

**Methods of controlling hæmorrhage during the operation.**—1. The method of controlling bleeding by means of an elastic band, which is carried across the axilla and brought well up over the point of the shoulder, is strongly to be condemned as useless and dangerous. In such a method the axillary artery is compressed mainly against the humerus. At the moment of the disarticulation the band is apt to slip. It is in the way of the operator, and cannot with any ingenuity be made trustworthy.

2. The subclavian artery may be compressed in the neck against the first rib.

The fingers are apt to slip during the movements of the limb or of the patient, and the assistant who controls the artery is somewhat in the way.

3. The main artery may be compressed in the flap by the fingers of an assistant, who takes hold of the part immediately before the vessel is divided.

This procedure is described in the account of Spence's operation (page 134).

4. The artery may be exposed and ligatured before it is divided and early in the course of the operation. An account of this method is given in the description of Larrey's disarticulation (page 136).

**Methods of operating.**—The following modes of disarticulating at the shoulder will be described :—

1. The racket method.
  - A. Spence's operation.
  - B. Larrey's operation.
2. The external or deltoid flap.

**Instruments.**—A stout knife with a blade from four to five inches in length. (If a transfixion operation be performed, an amputating knife with a blade equal in length to one diameter and a half of the limb will be required.) A scalpel. Ten pressure forceps. Artery and dissecting forceps. An aneurysm needle, metal retractors, scissors, etc.

**Position.**—The patient lies close to the edge of the table, with the shoulders raised and the head turned to the opposite side. The upper limb is carried a little from the side.

The surgeon should stand to the outer side of the limb in the case of both the right and the left arms. It is often, however, more convenient to stand to the inner side of the left extremity.

1. **The racket method.**—(A) *Spence's operation.*—The following is Prof. Spence's own account ("Lectures on Surgery," vol. ii. p. 662):—

"(1) Supposing the right arm to be the subject of amputation. The arm being slightly abducted, and the head of the humerus rotated outwards if possible, with a broad strong bistoury I begin by cutting down upon the head of the humerus, immediately external to the coracoid process, and carry the incision down, through the clavicular fibres of the deltoid and pectoralis major, till I reach the humeral attachment of the latter muscle, which I divide.

"I then, with a gentle curve, carry the incision across and fairly through the lower fibres of the deltoid towards the posterior border of the axilla, unless the textures be much torn. (The incision so far is carried the whole length directly down to the bone.)

"I next mark out the line of the lower part of the inner section by carrying an incision through the skin and fat only, from the point where my straight incision terminated (*i.e.* at the lower end of the insertion of the pectoralis major), across the



inside of the arm, to meet the incision at the outer part (Fig. 33). This ensures accuracy in the line of union, but is not essential.

“(2) If the fibres of the deltoid have been thoroughly divided in the line of incision, the flap so marked out can be easily separated (by the point of the finger, without further use of the knife) from the bone and joint, together with the trunk of the

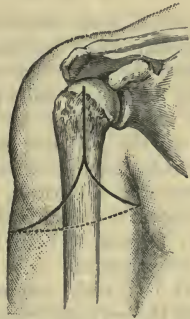


Fig. 33.—Disarticulation at the Shoulder by Racket Incision. (*Spence's operation.*)

posterior circumflex, which enters its deep surface, and be drawn upwards and backwards so as to expose the head and tuberosities.

“(3) The tendinous insertions of the capsular muscles, the long head of the biceps and the capsule, are next divided by cutting directly on the tuberosities and head of the bone (the humerus being rotated by the assistant as required). The broad subscapular tendon especially, being very fully exposed by the incision, can be much more easily and completely divided than in the double-flap method. By keeping the large outer flap out of the way by a

broad copper spatula or the finger of an assistant, and taking care to keep the edge of the knife close to the bone, as in excision, the trunk of the posterior circumflex is protected.

“Disarticulation is then accomplished and the limb removed by dividing the remaining soft parts on the axillary aspect.”

(4) This final step of the operation is effected as follows :—

The arm, abducted and rotated out, is thrust upwards by an assistant until the head of the bone is projecting well above the glenoid cavity. The surgeon, taking hold of the head thus made prominent, draws it away from the trunk, while he passes his knife behind it so as to cut the posterior part of the capsule and the only remaining tissues—those of the axilla—which connect the arm to the trunk.

An assistant follows the knife with his two thumbs, while he keeps the fingers of both hands spread out over the axillary integument. Just before the main vessels are divided he firmly compresses them, and holds the flap until the severed trunks are secured.

All the soft parts on the axillary aspect are divided with one sweep of the knife, which is made to emerge from the skin wound already marked out. The operation is completed by cutting the axillary nerves short, and by uniting the wound so as to form a vertical cicatrix.

Spence pointed out that the main vessel might be secured by ligature early in the operation, if thought well. “By a few touches of the bistoury,” he writes, “the vessel can be exposed, and can then be tied and divided between two ligatures, so as to allow it to retract before dividing the other textures.”

In disarticulating, the capsule should be divided transversely by a cut made upon the head of the bone. The three muscles attached to the greater

tuberosity are cut while the humerus is being rotated in, the subscapularis while it is being rotated out.

*Hæmorrhage.*—The main artery is divided between the origins of the posterior circumflex artery and the superior profunda.

On the edges of the vertical incision there may be bleeding from the humeral branch of the acromiothoracic artery, and in the depths of that incision the anterior circumflex artery will be divided.

There will be bleeding from muscular branches in the deltoid flap, and considerable hæmorrhage should the posterior circumflex artery be unintentionally cut.

(B) *Larrey's operation.*—This is the method designated by Farabeuf as the best of the many operations for disarticulation at the shoulder.

(1) The limb being held a short distance away from the side by an assistant, the surgeon steadies the skin of the shoulder with the left hand while he makes a vertical cut, which is commenced just below and just in front of the prominence of the acromion, and is continued down the arm for four inches.

Along this incision the knife is carried through the fibres of the deltoid muscle to the bone. By means of this preliminary wound the shoulder-joint may be explored.

(2) From the *centre* of the vertical incision the oval part of the racket is commenced, and is carried across the front of the arm to pass transversely over the inner side of the limb on a level with the lowest point of the vertical incision. It is finally continued up along the postero-external aspect of the limb to end where it commenced (Fig. 34).

This oval cut at first involves the integuments only. On the right arm it may be made with one sweep of the knife, commencing with the anterior segment of the oval and finishing with the posterior.

On the left extremity the two curved incisions

marking out the oval may be commenced at the lowest point, and be each made by cutting from below upwards.

(3) The anterior part of the wound is now deepened by cutting through the anterior segment

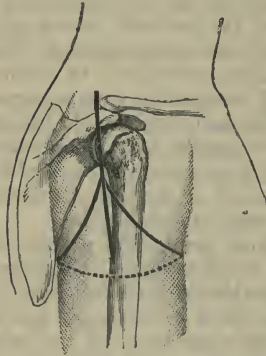


Fig. 34.—Disarticulation at the Shoulder-joint. (*Larrey's operation.*)

of the deltoid. The tendon of the great pectoral muscle is exposed, isolated, and divided close to the bone. The coraco-brachialis and biceps are in the next place isolated and then divided.

To the inner side of these structures the axillary artery is exposed, and is secured below the origin of the posterior circumflex. It may be secured between two ligatures and then divided.

(4) The operator now turns to the posterior part of the oval, and divides the whole of the posterior segment of the deltoid, carrying the knife back to the under part of the axilla.

While these deep incisions are being made the arm is rotated as required.

(5) Disarticulation is now effected precisely as in the previous operation, and the remaining axillary tissues which connect the limb with the trunk are severed in the same manner.

*Hæmorrhage.*—The main artery is divided as in the previous operation. Some bleeding may occur from the anterior circumflex artery in the region of the bicipital groove.

The posterior circumflex artery is very apt to be divided in the posterior segment of the oval incision.

2. **The external or deltoid flap.**—The base of the flap extends from the coracoid process in front to the spine of the scapula at the root of the acromion behind. It is U-shaped, and its extremity reaches nearly to the insertion of the muscle. If well-shaped, the flap includes practically the whole of the deltoid. At its base it should be represented by the entire thickness of the muscle, while at its margins it should be comparatively thin.

The surgeon should always stand at the outer side of the limb, and almost facing the patient.

(1) The flap is marked out by a skin-incision. In dealing with the right shoulder, the arm should be carried well across the chest and the knife be entered at the root of the acromion. It is then made to follow the outline of the deltoid, and to end at the coracoid process (Fig. 32, c).

As the knife is carried up towards the latter point, the arm is withdrawn from the chest and a little abducted.

It is more convenient that the surgeon should manipulate the limb himself with his left hand.

On the left shoulder the process is reversed. The arm is drawn away from the side and the incision commences at the coracoid. As it approaches the acromion, the arm is brought across the chest.

(2) The knife is now carried deeply along the whole

length of the incision, and the flap containing the substance of the deltoid muscle is raised. In cutting the flap the knife should be held a little obliquely, in order that the section of the muscle may be comparatively thin at the margins of the flap.

The flap is drawn well upwards by an assistant, and the outer surface of the shoulder-joint is thereby exposed.

(3) A transverse incision, involving the skin only, is now made across the inner side of the arm, about two inches below the outlet of the axilla. It joins the great wound in front and behind.

(4) Disarticulation is finally effected in the manner already described, and the operation is completed precisely as in Spence's method.

An assistant follows the knife with his thumbs, and compresses the great vessels, before they are cut, in the manner already detailed.

*Hæmorrhage.*—In the deltoid flap there will be bleeding from muscular branches only, notably from such as are furnished by the acromio-thoracic artery. The posterior circumflex artery will have been cut. The axillary vessels are divided at the free edge of the inner flap, the artery being cut below the origin of the two circumflex vessels. These arteries will be found severed in the margin of the inner flap, and the posterior of the two will certainly require a ligature.

## CHAPTER IX.

AMPUTATION OF THE UPPER LIMB TOGETHER WITH  
THE CLAVICLE AND SCAPULA.

THE amputation involves the removal of the upper limb, together with the scapula and the outer two-thirds of the clavicle. No disarticulation is attempted at the shoulder-joint.

The best method is that of Paul Berger by two flaps—an antero-inferior or pectoro-axillary flap, and a posterior-superior or cervico-scapular flap.

**Instruments.**—A strong, stout amputating knife with a blade from five to six inches in length ; a stout scalpel ; a periosteal elevator curved on the flat ; metal retractors, spatulæ, and blunt hooks ; a keyhole saw ; bone forceps, lion forceps, aneurysm needle, pressure forceps, artery and dissecting forceps, scissors, etc.

**The operation.** *1st step.*—The patient lies upon the back, close to the edge of the operating-table. The shoulders are raised. The arm is by the side or a little separated from it. The surgeon stands to the outer side of the limb, facing the patient.

The clavicular incision is now made with a stout scalpel. The incision is horizontal, is made along the surface of the bone, commences internally at the outer border of the sterno-mastoid muscle, and ends externally just beyond the acromio-clavicular articulation.

The knife divides everything down to the bone.

The inner third of the clavicle is not disturbed in any way.

By means of a small rugine or periosteal elevator curved on the flat, the periosteum is separated from the superficial part of the middle portion of the bone, which is now well exposed.

A large blunt hook may now be very carefully passed round the inner end of the exposed clavicle, and while an assistant draws the bone forward and steadies it by means of this hook, the surgeon saws it through at about the junction of the middle with the inner third. The section is accomplished by means of a keyhole saw.

The outer fragment of the divided clavicle is now drawn forwards by the lion forceps, the remaining periosteum is separated from its posterior and deep surfaces, and the bared bone is then again sawn through at the outer end of the middle third.

The middle third of the clavicle is thus entirely removed. The exposed subclavius muscle is now isolated, is divided close to the site of the inner section of the bone, and is dissected up so as to expose the great vessels, and turned outwards.

A double ligature is passed round, first the artery and then the vein, and between the ligatures each vessel is divided.

*2nd step.*—While the patient is still lying on the back, the body is brought as near to the couch as possible, and the shoulder is made to project beyond it.

An assistant draws the upper limb away from the body, and the surgeon stands to the inner side of the limb, *i.e.* between it and the trunk. The whole of the scapular region should be free of the table, the back resting upon the hard cushion, which is at the very edge of the table, and the head being drawn to the opposite side.

The assistant moves the limb as required during the cutting of the pectoro-axillary flap.

The incision marking out this flap is commenced at the centre of the clavicular incision, is then curved downwards and outwards, passing just beyond (*i.e.* to the outside of) the coracoid process, and then runs along the deltoid muscle, parallel to, but to the outer



side of, the groove between that muscle and the pectoralis major (Fig. 35). On reaching the point where the anterior wall of the axilla joins the arm, the incision crosses the lower margin of the pectoralis major, and passing transversely across the skin upon the inner or axillary surface of the arm, reaches the lower margin of the tendons of the latissimus dorsi

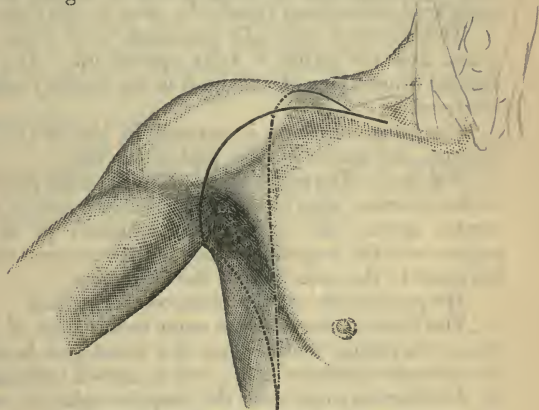


Fig. 35.—Interscapulo-thoracic Amputation.

and teres major. At this point the limb is well raised by the assistant, and the wound is completed by carrying the knife downwards and inwards to stop over the posterior surface of the inferior angle of the scapula. In the last part of the course the knife follows the groove between the vertebral border and the muscular mass formed by the teres major and latissimus dorsi.

The incision involves at first only the skin and the subcutaneous tissues.

The surgeon now dissects up the structures of the

flap which comprise the soft parts of the pectoral and axillary regions.

The pectoralis major is divided about where it is becoming tendinous, the pectoralis minor is severed close to the coracoid process. An assistant holds back the tissues of the flap, while the surgeon exposes the cords of the brachial plexus, which are then divided at the same level as the main vessels, *i.e.* close to the first rib.

The shoulder now falls outwards away from the trunk, and the axilla is fully opened up. Any undivided connections of the limb in the axillary region are freed.

The latissimus dorsi is severed in the line of the incision, and serves to form part of the flap.

*3rd step.*—The patient lies still in the same position at the extreme edge of the table; but the arm is now carried across the chest by an assistant so as to expose well the scapular region, and the surgeon takes his place to the outer side of the extremity.

He proceeds to cut the postero-superior flap.

The incision starts at the outer termination of the first or clavicular incision (*i.e.* at a point just beyond the acromio-clavicular joint), and is carried backwards by the shortest route over the scapular spine to meet the termination of the anterior flap incision, at the inferior angle of the scapula (Fig. 35). The wound concerns the integuments only. The skin is well reflected in the upper part of the incision, so as to lay bare the trapezius muscle. This muscle is divided close to its attachments to the clavicle and scapula, and is entirely severed from its connections with the limb.

*4th step.*—Nothing now remains but to sever the connections of the scapula with the trunk.

One assistant holds back the anterior flap, another the posterior. The limb is allowed to hang away from the side, supported by a third assistant, and steadied and directed by the left hand of the operator.

The operator himself may conveniently stand to the inner side of the right arm and the outer side of the left. The superior and vertebral borders of the scapula being made prominent, the following muscles are rapidly divided from above downwards close to the bone: the omo-hyoid, levator anguli scapulæ, rhomboideus minor and major, and the serratus magnus.

The limb is now free. The two teres muscles, the subscapularis, and the supra- and infraspinatus muscles go untouched with the amputated extremity.

*Hæmorrhage.*—The early ligature of the main vessel renders the bleeding in this formidable operation comparatively slight.

It is during the fourth step of the operation that most hæmorrhage is to be expected. It will come from the vessels descending from the neck or from the suprascapular and the posterior scapular.

## CHAPTER X.

## AMPUTATION OF THE TOES.

IN dealing with the anterior part of the foot it must be remembered that the foot rests upon the heel, the heads of the metatarsal bones, and the inner margin of the sole. In amputation, therefore, every care should be taken to save as much as possible of the metatarsus, and especially of the first metatarsal bone and the phalanges of the great toe. The same care need not be taken to preserve every possible part of the four outer toes. A sloughing stump has often resulted from too great anxiety to preserve these almost useless digits.

**Instruments.**—Stout, narrow scalpels, with blades from one inch to two inches in length, and with well-rounded points. A fine keyhole saw, or minute Butcher's saw. Bone forceps. Dissecting and artery forceps. Tapes to retract the toes. Scissors, needles, etc.

**Position.**—In all these operations upon the toes the patients should lie on the back, and the foot be brought well beyond the end of the couch. The surgeon should sit at the end of the table facing the patient. The assistants stand—facing the surgeon—one on each side of the end of the table. One should fix the limb and hold the toe, while the other attends to the wound.

The operations included in this chapter will deal with in the following order:—

- A. Amputation of the distal phalanges.
- B. Disarticulation at the metatarso-phalangeal joints.

c. Amputation of the toes *en masse* through the metatarsus.

A. AMPUTATION OR DISARTICULATION OF THE DISTAL PHALANGES OF THE TOES.

1. **Disarticulation of the last phalanx of the great toe.**

*Large plantar flap.*—Hold the toe between the thumb and first two fingers of the left hand—the thumb on the pulp of the toe, the fingers on the nail. Cut the plantar flap as the toe is thus held. Enter the knife—at right angles to the surface—just over

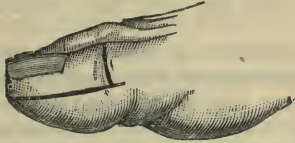


Fig. 36.—Disarticulation of the last Phalanx of the Great Toe by a large Plantar Flap.

the head of the first phalanx. Cut along the side of the toe to the pulp. This incision should be parallel to the phalanx, and nearer to the dorsal than the plantar aspect. Shape the flap as shown (Fig. 36) and return to the same point on the opposite side. The incision should extend down to the bone.

Let the assistant forcibly extend the last phalanx while the flap is dissected back, it being held by the left hand while so doing. In making this flap the surgeon must keep as close as possible to the bone. When the glenoid ligament is reached, cut it transversely against the base of the last phalanx. The joint is thus opened.

Now let the surgeon forcibly flex the toe and make a transverse cut across the dorsum that at once divides the extensor tendon and opens the joint.

Rotate the toe out, and carefully divide the internal lateral ligament. Rotate it in and divide the external band, and the disarticulation is complete. In disarticulating, keep the knife very close to the bone, so as to avoid wounding the plantar digital arteries. Cut the lateral ligaments from without inwards. The cicatrix of the stump will come well on the dorsum.

*Hæmorrhage.*—The two dorsal digital arteries will be cut at the corners of the dorsal incision. They are small, and usually do not need to be secured. If the flap has been well cut, the two plantar digital arteries will not be wounded, but will lie buried in the flap until they anastomose at its free end.

**2. Amputation or disarticulation of the distal phalanges of the four outer toes.**—In operating upon the smaller toes the neighbouring digits should be held aside by the assistant by means of tapes. It is well not to use too long a scalpel.

*The terminal phalanges* may be removed by the operation just described.

In *disarticulation of the second phalanx* use the oval or racket incision and proceed precisely as in the corresponding operation in the hand. (*See page 97.*)

*Hæmorrhage.*—Two dorsal and two plantar digital arteries are found cut in the lateral edges of the wound. The dorsal will require no attention, the latter may be twisted.

In *amputation through the first phalanx* employ the circular method. Make a circular cut round the phalanx at the level of the web; cut to the bone. As the knife crosses the dorsum, flex the toe so as to cut the extensor tendon short. As the scalpel crosses the plantar aspect, extend the digit to its utmost. Separate the soft parts from the phalanx as high up as possible, and divide the bone. Close the sheath of the flexor tendon (page 91). The vessels are cut as

in the last instance. The cicatrix should be vertical, *i.e.* dorso-plantar.

*Comment.*—In disarticulating the second phalanx, remove the head of the first phalanx, or replace the operation by an amputation through the latter bone at the level of the web. The head of the first phalanx is large, and is apt to play the part of a foreign body between the other toes when it is left. Its removal is no detriment to the use of the foot.

As has been observed elsewhere (page 91), the bone should be divided by a very fine saw rather than crushed by forceps.

#### B. DISARTICULATION AT THE METATARSO-PHALANGEAL JOINTS.

1. **Disarticulation of the great toe at the metatarso-phalangeal joint.**—In this operation notice must be taken of the very large size of the head of the metatarsal bone. Its dimensions are increased by the presence of the sesamoid bones, which should never be removed with the phalanx. It is of considerable importance to the future use of the foot that the head of the metatarsal bone should be preserved, and it will be seen that the chief difficulty of the operation is to provide flap enough to cover the projection. It is important also that the scar should be away from the plantar surface and the line of the sesamoid bones.

(1) *By internal plantar flap (Farabeuf).*—The surgeon sits to the front and the inner side of the foot. The four surfaces of the digit—dorsal, plantar, internal, and external—should be noted and conceived to be each of equal extent. The joint-line is made out, and the toe being grasped with the left hand, the knife is entered over that line and at a point where the dorsal and internal surfaces meet. An incision, 2 c.m. in length, is made along the toe,

parallel to the extensor tendon and on the line between the two surfaces named. It is then curved downwards over the inner surface to the plantar margin (Fig. 37). The toe is now turned in, and the knife, placed beneath the member, is drawn across the plantar surface to the edge of the web between the toes. The knife is now held above the toe, and the incision completed by a cut to the point

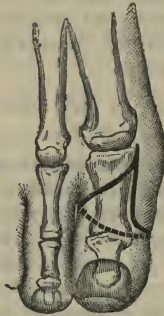


Fig. 37.—Disarticulation of the Great Toe by Internal Plantar Flap.

of starting, made by the shortest route. The whole of this incision should involve the skin only.

It should now be deepened down to the bone in the same order. In drawing the knife across the plantar surface, extend the toe, so as to cut the flexor tendon high up. Dissect back the flap, keeping close to the bone. In so doing, the assistant should hold the toe and turn it to one or other side as required, while the surgeon uses his left fingers to turn back the soft parts. Separate the tissues about the point of starting; clear the soft parts from the surface of the joint. Forcibly extend the toe, and cut the glenoid ligament transversely close to the base of the



phalanx. The joint is thus opened; the ligament, with the sesamoid bones, remains behind. Divide the lateral ligaments, and finally cut the extensor tendon. Close the fibrous sheath for the flexor tendon (page 91).

*Hæmorrhage.*—The outer plantar digital artery will be found cut close to the web, the inner vessel at the free end of the inner flap. The dorsal digital vessels will probably not need to be secured.

(2) *By racket or oval incision*—The toe is grasped by the left hand. The knife is entered about 1 c.m. above the metatarso-phalangeal joint in the dorsal median line. It is continued down to the centre of the first phalanx, and when carried round the toe to form the racket should just avoid the web. The proceeding is identical with that described in a like disarticulation in the hand (page 101). The joint should be opened from below, through the glenoid ligament.

The fibrous sheath for the flexor tendon is closed (page 91).

In disarticulating, also, care must be taken to keep close to the phalanx and to cut towards the bone; the soft parts must be well dissected back and the ligaments exposed. If such care be not taken, the plantar digital arteries—which lie close to the joint—will be divided. The cicatrix comes over the head of the bone and is vertical to the sole.

The digital arteries will be found divided at the free margin of the flap on each side.

When possible, the base of the first phalanx of the toe should be saved, on account of the important series of muscles to which it gives attachment (abductor and adductor pollicis, flexor brevis pollicis, and transversus pedis). Although these muscles can no longer act upon the toe, they are of value in maintaining the strength of the sole.

The skin in this region is often much thickened, and is consequently unyielding, and in adjusting flaps care must be taken that too much strain does not come upon the sutures.

**2. Disarticulation of the outer toes at the metatarso-phalangeal joints.**

The best operation is that by the *oval* or *racket incision* already described (pages 97, 107).

**3. Disarticulation of the toes en masse at the metatarso-phalangeal joints.**

This is best effected by short dorsal and plantar flaps.

The operator should sit at the end of the table, facing the foot, which should project some way beyond the extremity of the table.

The line of the metatarso-phalangeal joints must be defined.

The chief difficulty in the operation is to provide a sufficient covering for the large head of the first metatarsal bone.

Supposing the left foot to be the one dealt with, the operator grasps the toes with the left hand, his thumb being on the dorsum and his fingers on the plantar surface. The foot is turned out, and the knife is entered just over the metatarso-phalangeal joint of the great toe. The point of entrance should be midway between the plantar and dorsal surfaces. An incision is now made from this point along the inner side of the foot. It is longitudinal, and is carried as far as the centre of the first phalanx.

The foot is now extended and the toes are gently flexed, while the incision is carried abruptly across the dorsum. The cut crosses the centre of the first phalanx of the great toe transversely, and then follows the line of the web.

To follow the hollows between the toes, the operator must separate each pair a little with his left

fingers as he proceeds. On reaching the dorsum of the little toe, the incision is carried longitudinally back along the lateral margin of the little toe to the level of the metatarso-phalangeal joint.

This incision may in the first instance involve the skin only. The dorsal flap thus marked out must be dissected back. The assistant takes charge of the toes, which he keeps flexed; the surgeon has his left hand free to manipulate the flap. The flap should contain all the soft parts down to the extensor tendons. When about half the flap has been dissected back these tendons should be divided. Before each one is cut the corresponding toe should be flexed to its utmost by the assistant. The flap is carried back until the line of joints is exposed.

The plantar flap is now cut. The toes are held in the extended posture by the surgeon, his thumb being on the plantar aspect and his fingers on the dorsum.

The incision is simply transverse, and joins the distal ends of the two lateral incisions. It is so carried across the foot as to follow the creases which separate the toes from the sole. The incision should extend to the flexor tendons. The flap is dissected back, the assistant keeping the toes extended. When the flap is about half made, the flexor tendons may be divided, and the whole of the soft parts are then dissected back to the line of joints.

The flaps should be now sufficiently retracted to expose this line well. The articulations having been opened on the dorsal aspect, the lateral ligament of the first joint is divided; the toes are then extended fully, and the line of articulations finally opened from the plantar aspect. The glenoid ligaments are preserved. The disarticulation should then be completed, joint by joint, in the left foot, from the inner to the outer side. In the right foot the incisions are

commenced at the outer side, and the disarticulation is begun at the joint of the little toe.

The sheaths of the flexor tendons should be closed.

*Hæmorrhage.*—The plantar digital arteries will be found divided some way down on the plantar flap, and the dorsal digital at about the same place on the dorsal flap.

The latter will probably not need to be secured.

*Comment.*—This is a dead-house operation, and one that can scarcely ever be required in the living subject. It may be called for in some very limited cases of crushed toes, and possibly in some instances of frost-bite.

#### C. AMPUTATION OF THE TOES EN MASSE THROUGH THE METATARSUS.

This operation is carried out upon the same principles as that just described.

The best procedure is that of a *long plantar flap*. The points at which the bones are to be sawn must be first determined. The saw-line must be oblique, so as to follow the natural line of the metatarsal bones. The saw-cut, in fact, should be about parallel with the line of the web. The plantar flap may be cut first. This is done with the foot well flexed.

Assuming the left foot to be the one operated on, the knife is entered at the inner margin of the foot, midway between the dorsal and plantar surfaces. The point of entrance is over the first metatarsal, and is just behind the point at which that bone is to be divided. The incision is carried along the side of the foot until the level of the crease that separates the great toe from the sole is reached. It is now made to sweep across the plantar surface just behind the web. On reaching the outer surface of the little toe, the incision is carried back along the margin of the foot

until a point is reached just posterior to the spot selected for the section of the fifth metatarsal bone. In making this plantar incision the surgeon should keep the foot rigid with his left hand, and at first the cut should be through the skin only. An assistant now takes the foot and keeps it well flexed at the ankle, while the surgeon uses his left fingers to aid in dissecting back the flap. The flexor tendons should be divided as soon as the separation of the flap has been well commenced. While they are being cut the individual toes must be fully extended.

The plantar flap should contain all the soft parts down to the bone.

The foot having been extended, the dorsal incision is made. It should be parallel with the plantar cut, and should join the lateral parts of the plantar flap about one inch from their points of commencement. In other words, this little flap is about one inch in length. The flap must include all the soft parts down to the bone. The extensor tendons should be divided when the flap is about half separated.

In dividing the bones, the plantar flap should be carefully protected by an ivory spatula. Each bone should be sawn separately from the dorsal aspect with a fine narrow saw. The rude crushing of the bones with cutting forceps is not to be advised.

It is to be remembered that the shafts of the metatarsal bones are embraced by the interossei muscles. These must be cleanly divided before the saw is applied.

The cicatrix comes upon the dorsum of the foot.

*Hæmorrhage.* — In the plantar flap six arteries (the digital) may possibly require to be secured. One will be found opposite to each of the four interosseous spaces, a fifth opposite the outer side of the fifth metatarsal, and a sixth opposite the inner side of the first metatarsal. The two latter vessels may not

require to be secured. The largest vessel is that opposite the first interosseous space.

Vessels similarly placed will be divided in the dorsal flap. Probably none will require attention except the artery (the first dorsal interosseous) that is cut opposite the gap between the first and second metatarsal bones.

## CHAPTER XI.

## PARTIAL AMPUTATION OF THE FOOT.

AMPUTATIONS THROUGH THE TARSO-METATARSAL  
JOINTS.

THESE operations consist in the removal of single toes with their respective metatarsal bones, and in the removal of the whole of the metatarsus by Lisfranc's and Hey's operations.

**Instruments.**—A stout knife with a blade three inches long. Narrow metal retractors. Lion forceps (in the event of the part being crushed). Dissecting, pressure, and artery forceps.

*Position.*—The same as for previous amputations. (See page 144.)

DISARTICULATION OF A TOE, TOGETHER WITH ITS  
METATARSAL BONE.**Disarticulation of the great toe, together with its metatarsal bone.**

*By oval or racket incision.*—Having defined the metatarso-tarsal joint, grasp the toe with the left hand, and enter the knife at the inner border of the foot, just below the line of the joint. Carry the incision outwards, parallel to the articulation line, until the centre of the dorsal aspect of the metatarsal bone is reached (Fig. 41, A). Now continue the cut straight down towards the nail, along the median line of the dorsum of the bone. This incision will lie to the inner side of the extensor proprius pollicis tendon. On reaching the centre of the metatarsal bone, incline the incision to the web, then round the outer side of the root of the toe (the phalanx being

turned out), and so on to the plantar aspect. Let the knife cross the plantar surface transversely in the groove that separates the toe from the sole. Finally, curve the incision round the outer aspect of the toe to reach the dorsal wound at the centre of the metatarsal bone. The incision involves the skin only.

Now deepen the dorsal cut. Divide the tendons of the extensor proprius and extensor brevis close to the metatarso-tarsal joint. Separate the soft parts from the inner and outer sides of the bone, keeping close to it, and cutting from the tarsus towards the toe. While effecting this separation the assistant turns the toe to one or other side, and the surgeon uses his left fingers to draw away the soft parts. The assistant now partly extends the toe, and, the flexor tendon having been cut, the soft parts are dissected off from the plantar aspect of the bone. The bone should be bared back to the joint. The sesamoid bones are left behind.

Care must be taken not to wound the communicating branch of the dorsalis pedis artery, which runs between the two toes.

The next step is to open the joint on the dorsal aspect, and as far as possible on the outer and inner sides. The surgeon now once more grasps the toe and divides the plantar and remaining ligaments. Last of all, the tendons of the peroneus longus and tibialis anticus are cut, and the toe with its metatarsal bone is free.

Cut the flexor tendon short, and close its sheath (page 91). If the transverse cut at the commencement of the incision be not employed, the wound must start over the cuneiform bone.

*Hæmorrhage.*—The dorsal digital branches (of the first interosseous artery) to the sides of the toe are divided in the dorsal incision. The inner one will probably need no attention. In the plantar aspect of



the wound are divided the termination of the internal plantar artery, the first plantar digital artery, and the internal digital branch to the great toe. There is great risk of wounding the communicating branch of the dorsalis pedis in the gap between the first and second toes.

**Disarticulation of the little toe, together with its metatarsal bone, by the oval or racket incision.**—The toe being grasped by the left hand, the knife is entered at the outer margin of the foot, about 1 c.m. behind the tuberosity of the fifth metatarsal bone. An oblique cut—parallel with the cubo-metatarsal joint—is made (Fig. 40, A), and a median dorsal incision is carried thence to the neck of the metatarsal bone. Here the oval is made just as in the disarticulation of the great toe (page 155). The subsequent steps of the operation are practically identical with those already described.

*Hæmorrhage.*—In the dorsal incision the dorsal digital arteries of the toe are divided, while the plantar digital vessels are found cut on the plantar aspect of the wound.

Any one of the *other metatarsal bones* may be removed, with its corresponding toe, by the oval incision. The outer two bones may in like manner be removed together by the oval operation, the *queue* of the oval running along the interosseous space between the two bones.

These operations are of little practical value.

#### LISFRANC'S OPERATION.

A disarticulation of the anterior part of the foot at the tarso-metatarsal line.

**Instruments.**—A strong, stout, narrow knife, about four or five inches long in the blade; a scalpel; a saw, in the event of the joints being ankylosed; a narrow metal spatula; pressure forceps, artery and

dissecting forceps; lion forceps, if the toes be crushed.

**Position.**—The patient lies on the back. The foot is drawn well beyond the end of the table, and is raised upon a support until on a level with the surgeon's neck. The operator may stand to cut the dorsal flap, but should sit at the end of the table facing the patient, to cut the sole flap, and complete the disarticulation. The assistants stand one on each side of the end of the table.

**Operation** (*Right foot*). 1. *The dorsal flap.*—Grasp the extended foot with the left hand, so that the thumb is on the base of the fifth metatarsal bone and the forefinger on that of the first, while the palm of the hand faces the sole. The skin on the dorsum is stretched, and the knife is held in the free hand, with the forefinger on the back of the blade. In this position the dorsal flap is cut. The incision commences at the outer margin of the foot, just behind the tubercle of the fifth metatarsal bone (Fig. 38). For about an inch it follows the outer border of the bone. It then sweeps across the dorsum parallel to the line of the tarso-metatarsal joints, and about half an inch in front of it. The cut is curved towards the toes, and reaches the plantar aspect of the inner border of the foot, about half an inch in front of the tarsal joint of the great toe. It finally follows the inner margin of the foot, and ends three-fourths of an inch behind the said joint.

The assistant now holds the foot fixed in the extended position, while the surgeon uses his left fingers to dissect back the dorsal flap. The dissection at first includes the skin only; but when the integument has been retracted about one-fourth of an inch, the extensor tendons are divided. The flap contains, therefore, all the soft parts down to the bones. It is important to expose the metatarsus well, and to carry

the flap back far enough to expose the tarso-metatarsal joint-line.

2. *The plantar flap.*—The plantar flap is now cut. The surgeon flexes the foot with the left hand, his thumb being along the line of the toes, and his fingers on the dorsum. The knife is introduced at right angles to the surface of the now well-exposed sole. The incision, commencing on the outer side, follows the plantar edge of the fifth metatarsal for a short distance, and then sweeps obliquely across the sole to the neck of the fourth metatarsal. It now traverses the sole just behind the line of the heads of the metatarsus, and finally follows the plantar edge of the metatarsal bone of the great toe to join the extremity of the dorsal incision. The plantar flap is thus convex forwards, and the inner segment is longer than the outer (Fig. 38).

The incision at first involves the skin and the subcutaneous tissues only. The assistant now grasps the toes and keeps them fully extended while the surgeon dissects back the flap. This should include the subcutaneous structures only until the hollow behind the heads of the metatarsal bones is reached. When this hollow is exposed, the tightly-stretched flexor tendons are divided by a vigorous transverse cut. The rest of the flap includes all the soft parts down to the bones. These are dissected up by short transverse cuts with the knife while the operator pulls back the flap. The separation is carried back until the line of the tarso-metatarsal articulations is reached. The exposure of the peroneus longus tendon will indicate when this line is reached. The tendon should for the present be left uncut.

3. *The disarticulation.*—Return to the dorsum. Grasp the foot with the left hand and extend it fully. Let an assistant hold back the dorsal flap with one hand while by means of a metal spatula he retracts

and protects the plantar flap with the other. Enter the knife just behind the tubercle of the fifth metatarsal bone, and, cutting obliquely forwards and inwards, open the tarsal joints of the three outer metatarsal bones. In this manœuvre the tendons of

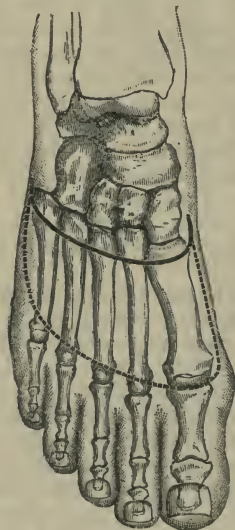


Fig. 38.—Lisfranc's Amputation.

the peronei brevis and tertius are divided. Now turn to the inner side of the foot, and open the joint between the first metatarsal and the inner cuneiform, cutting at the same time the tibialis anticus expansion. In the next place, open the joint between the second metatarsal and the middle cuneiform on its dorsal aspect. The complete separation of the metatarsal

bone is difficult, and is thus effected: Hold the knife like a trocar and—keeping it nearly parallel with the dorsum of the foot—thrust the point in deeply between the bases of the first and second metatarsal bones until it is arrested by bone. The edge is turned towards the ankle. Now grasp the knife in the hand like a dagger, and elevate the handle until it is perpendicular to the dorsum of the foot, at the same time cutting in the direction of the external malleolus. By this manœuvre (the *coup de maître*) the strong ligament of Lisfranc is severed.

Divide any remaining ligaments, especially those on the plantar aspect of the joints, and finally the metatarsus is left attached only by means of the peroneus longus tendon. Draw this tendon out, and cut it at the outer angle of the incision, and the parts to be removed are free.

*Left foot.*—Commence the dorsal and plantar incisions on the inner side of the foot. In disarticulating, open first the joint between the metatarsal bone of the great toe and the inner cuneiform, then open the tarsal joints of the three outer metatarsals, and finally disarticulate the second metatarsal.

*Hæmorrhage.*—In the dorsal flap are divided the dorsal interosseous arteries (four), opposite to the interosseous spaces, and the plantar branch of the dorsalis pedis as it dips down between the bases of the first two metatarsal bones. In the plantar flap are divided the plantar digital branches of the external plantar, and probably that vessel itself, near the base of the second metatarsal. The terminal part of the internal plantar artery is also divided.

*Comment.*—The dorsal flap having been made, the disarticulation may be at once proceeded with, and the operation completed by cutting the plantar flap from within outwards—*i.e.* practically by transfixion. Or the disarticulation having been effected from the

dorsum, the plantar flap may be afterwards cut in the manner already described. On the other hand, the operation may be commenced by cutting the plantar flap, and then be completed by the making of the dorsal flap and disarticulation.

It is a common fault to make the dorsal flap too small, and to limit it strictly to the dorsum. This flap should include not only the dorsal structures, but also the greater part of those of the outer and inner margins of the foot. If the dorsal incision be carried too far back, the joint between the scaphoid and cuneiform bones may be opened by mistake on the inner margin of the foot.

#### HEY'S OPERATION.

This operation resembles Lisfranc's procedure in all essential points, and differs only in this—the four outer metatarsal bones are disarticulated from the tarsus, and the projecting end of the internal cuneiform bone is sawn through, carrying the first metatarsal bone with it.

## CHAPTER XII.

## PARTIAL AMPUTATION OF THE FOOT.

AMPUTATION THROUGH THE MEDIO-TARSAL JOINT  
(CHOPART'S OPERATION).

THIS consists of a disarticulation of the foot at the medio-tarsal joint.

**Instruments and position.**—The same as for Lisfranc's operation.

**Operation.**—In its main points the procedure is identical with Lisfranc's amputation. 1. *The dorsal flap.*—The incision commences at a point midway between the tip of the outer malleolus and the tuberosity of the fifth metatarsal on the outer side, and at a point just behind the tuberosity of the scaphoid on the inner side. The cut follows on each side the margin of the foot for a little distance, and is then so curved over the dorsum as to cross the bases of the metatarsal bones (Fig. 39). 2. *The plantar flap* extends between the two points first-named. It follows in the main the lines of Lisfranc's flap, and has the same shape. It is so carried over the sole as to cross the middle of the metatarsus (Fig. 39). The flexor tendons are divided as soon as a little skin has been retracted. Both flaps contain all the soft parts down to the bones. The medio-tarsal joint-line should be well exposed.

3. *The disarticulation.*—In disarticulating, the foot may be conveniently held in the position of talipes varus, and be well extended. Care must be taken to open the right joints. It is easy to open the scapho-cuneiform joints in the place of the astragalo-scaphoid, and to actually leave the scaphoid behind.

The tendons that are especially to be noted in cutting the deeper parts are the three peronei and the two tibials.

*Hæmorrhage.*—In the dorsal flap, the dorsalis pedis artery is cut as it dips down between the first

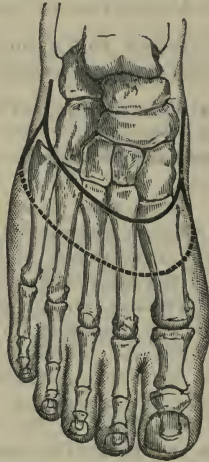


Fig. 89.—Chopart's Amputation.

and second metatarsal bones. The metatarsal and tarsal branches of that vessel are also divided. The two saphenous veins come in this flap.

At the anterior part of the inner segment of the plantar flap the internal plantar artery is divided, and near the base of the second metatarsal bone the end of the external plantar. In the outer part of the flap are the digital branches of the latter vessel.



## CHAPTER XIII.

## PARTIAL AMPUTATION OF THE FOOT.

## SUBASTRAGALOID DISARTICULATION.

THIS operation consists of a disarticulation at the astragalo-scapoid and astragalo-calcaneal joints. The astragalus is the only bone of the foot that is left behind, and forms the summit of the stump.

**Position and instruments.**—The same as in the preceding operation.

The following *methods* will be described:—

1. The oval operation.
2. By the heel flap.

**1. The oval operation (Maurice Perrin).—**

The incision in this procedure commences behind, at the insertion of the tendo Achillis, and is carried forwards along the outer side of the foot—parallel with its external border, and one inch and a half below the external malleolus—to a point just behind the base of the fifth metatarsal bone.

It is then curved across the dorsum to reach on the inner side of the foot the level of the joint between the first metatarsal bone and the cuneiform.. The incision now sweeps back across the sole and joins the first cut some two inches behind the base of the fifth metatarsal bone (Fig. 40, B).

The incision may at first involve the skin only, but must then be carried well down to the bone.

The leg is flexed upon the thigh, and the foot projects beyond the end of the table, with its outer surface well exposed and lying horizontally.

Let the dorsal part of the flap be now dissected

up sufficiently to expose well the head of the astragalus ; divide the tendo Achillis ; open the astragaloscaphoid joint on its dorsal aspect. Keep the knife between the bones, and, cutting backwards, pass it between the os calcis and astragalus, and so sever the interosseous ligament. This entails no difficulty if the outer surface of the foot be well exposed and kept upon the stretch with the left hand. As the ligament

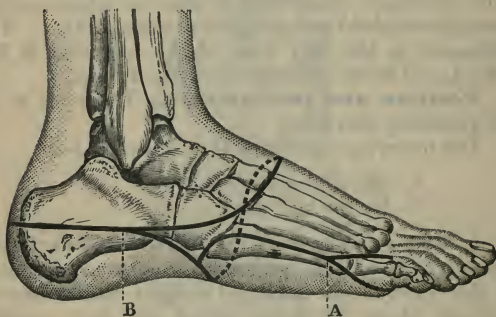


Fig. 40.—A, Disarticulation of the little toe, together with its metatarsal bone, by the oval or racket incision ; B, Maurice Perrin's subastragaloid amputation.

is divided, turn the os calcis more and more out. See that all the tendons, etc., are divided on the outer side of the foot, and that the outer aspect of the os calcis is bared to the periosteum.

Now with the left hand twist the foot round until it is in the position of the extremest varus. In this position dissect—by cuts made from left to right in the left foot, and from right to left in the right foot—all the soft parts from the inner and under surfaces of the os calcis. Special care must be taken of the vessels that lie in the hollow on the inner side of that bone.

Clear the under surface of the bone, still turning the foot out. When this process of enucleation is complete, the foot will have been so turned round that the dorsum will face downwards. Now separate the foot and cut any neglected tendons short.

The suture line on the stump is horizontal, and is on the outer side of the extremity.

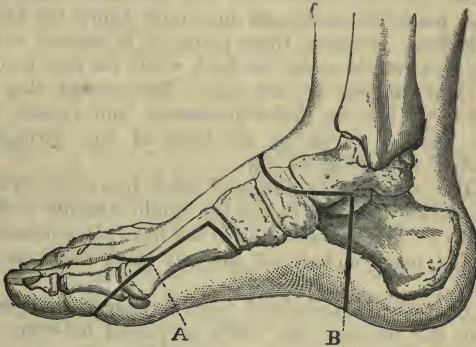


Fig. 41.—A, Disarticulation of the great toe, together with its metatarsal bone, by the oval or racket incision; B, subastragaloid amputation by heel flap.

It is advisable to saw off the head of the astragalus.

In the left foot the disarticulation may be carried out as soon as the dorsal and external parts of the flap have been dissected back. In the right foot the whole of the flap had better be dissected back as far as possible, and the os calcis cleared before the disarticulation is attempted.

*Hæmorrhage.*—In the edge of the upper or dorsal incision are cut the posterior peroneal, the anterior peroneal, and branches of the tarsal and metatarsal arteries.

The dorsalis pedis is divided opposite the centre of the head of the astragalus. In the inner part of the flap the internal and external plantar are cut.

**2. Disarticulation by a heel flap. —**

The flaps made in this operation are a modification of those of Syme's amputation (page 170). The plantar incision commences half an inch below the outer malleolus, and ends one inch below the inner malleolus. Between these points it is carried vertically downwards across the heel, while the foot is held at right angles to the leg. The dorsal flap is U-shaped, has its limbs horizontal, and crosses the foot, with a curve, at the level of the astragalo-scapoid joint (Fig. 41, B).

The heel flap is dissected back just as in Syme's amputation (page 171) and the tendo Achillis is then divided. The dorsal flap is in the next place dissected up, and must include all the soft parts down to the bone.

The astragalo-scapoid joint having been opened from the dorsum, the knife is passed between the astragalus and os calcis, and the disarticulation is effected.

The head of the astragalus should be removed with the saw. The vessels divided are practically the same as those cut in Syme's operation.

## CHAPTER XIV.

## AMPUTATION OF THE FOOT.

Two procedures will be described :—

- A. Disarticulation at the ankle-joint.
- B. Intracalcaneal amputations of the foot.

A. DISARTICULATION AT THE ANKLE-JOINT (SYME'S AMPUTATION).

This is the principal operation for removing the entire foot. The flap is made from the heel, the soft parts having been peeled off the os calcis. The two malleoli, together with the articular surface of the tibia, are sawn off.

The blood supply of the heel-flap is a matter of great importance; the two chief vessels of supply are the external calcaneal of the posterior peroneal on the outer side, and the internal calcaneal of the external plantar on the inner side. The first-named vessel is a continuation of the posterior peroneal. It runs just behind the inferior tibio-fibular joint, and then behind the outer malleolus to the heel. With regard to the internal calcaneal artery, the posterior tibial divides "on a level with a line drawn from the point of the internal malleolus to the centre of the convexity of the heel." This line is dangerously close to the line of the incision. The internal calcaneal artery arises from the external plantar, close to the bifurcation and under the fibres of origin of the abductor pollicis. Inasmuch as this is the chief vessel of the flap, the greatest care must be taken of it.

**Instruments.**--A stout narrow knife, with a blade three inches long, a narrow but rounded point,

and a large strong handle ; a scalpel ; a saw ; two metal retractors to hold back the flaps when sawing the leg bones ; lion forceps ; pressure forceps ; artery and dissecting forceps, scissors, etc.

**Position.**—The patient lies on the back, with the foot projecting beyond the end of the table, and the toes pointing upwards. The surgeon sits facing the end of the table. The lower end of the leg is raised on a support to the level of the surgeon's face. The surgeon sits to cut the heel flap, and stands to cut the dorsal flap and to disarticulate.

**The operation.**—An assistant steadies the leg with one hand, and holds the foot—by the toes—rigidly at a right angle to the leg with the other hand.

1. *The heel flap.*—The incision starts from the tip of the outer malleolus, and in a line nearer to its posterior than its anterior border.

It is carried vertically down the heel, exactly at right angles to the long axis of the foot, runs transversely across the sole, and passing up vertically on the inner side of the heel, ends at a point about half an inch below the tip of the inner malleolus (Fig. 42).

In making this incision, supposing the right foot to be operated on, the surgeon holds the ankle with the palm of his left hand on the dorsum of the foot, with his thumb on the outer malleolus, and his forefinger on the inner malleolus.

Entering the knife at the inner starting-point, the incision is carried down to the sole and then across the plantar aspect of the os calcis at one cut. The knife is now re-entered at the outer starting-point, and is carried down to meet the first incision at the sole. If an attempt be made to perform the incision at one cut, and to make the outer limb of the incision by cutting from the heel towards the leg, the knife may slip and cut too far up into the leg, running by the starting-point. On the left foot the same precaution

is observed, but the incision is commenced on the outer side.

This incision should be carried well and cleanly down to the bone. The heel flap is now dissected back: the thumb-nail of the left hand is used with force to drag back the soft parts, while the knife is kept well on to the bone and parallel to the surface of the flap. The os calcis must be laid perfectly bare. The great point in Syme's amputation is to "keep close to the bone."

The flap must be cleared from the tuberosities of the os calcis, and then from its posterior surface.

2. *The dorsal incision.*—The surgeon now holds the foot in the left hand in the position of full extension, and connects the extremities of the heel incision by a cut which simply sweeps across the front of the ankle region. The dorsal and heel incisions are about at right angles to one another (Fig. 42). The cut includes all the soft parts down to the bone. The tendons must be cleanly divided while the foot is kept on the stretch.

3. *The disarticulation.*—The ankle-joint is at once exposed, the anterior ligament having been severed. The knife is now introduced into the joint and the lateral ligaments are divided, in both instances by cutting from within outwards. These complex ligaments are difficult to cut if attacked from the outer side of the articulation. The posterior ligament is cut, the upper surface of the os calcis is cleared, and by the division of the tendo Achillis the disarticulation is completed.

4. *The removal of the malleoli.*—The soft parts are cleared from the two malleoli and the lower end of the tibia, great care being taken not to damage the flaps. The exposed bones are then divided by a horizontal saw-cut, the saw being applied about a quarter of an inch above the inferior margin of the tibia.

The flaps may be protected by spatulæ during the sawing. If it should be necessary, the malleoli may be held with lion forceps.

Before the wound is adjusted by sutures, a hole may be made in the centre of the heel flap, and a drainage-tube introduced.

*Hæmorrhage.*—The anterior tibial artery is cut in the dorsal flap just opposite the centre of the front of

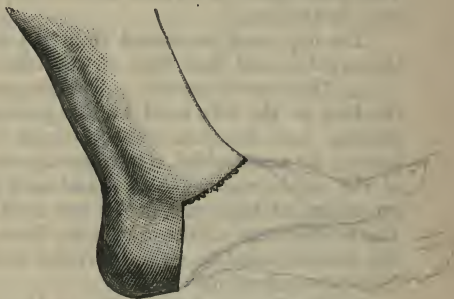

Fig. 42.—Syme's Amputation of the Foot.

the ankle. The external and internal plantar arteries are divided in the inner section of the heel flap. The following vessels may give rise to hæmorrhage: the internal malleolar of the posterior tibial behind the inner malleolus; the anterior peroneal in front of the tibio-fibular joint; the external and internal malleolar of the anterior tibial in front of their corresponding malleoli. The internal saphenous vein is cut in the dorsal flap, the external in the heel flap.

#### B. INTRACALCANEAL AMPUTATIONS OF THE FOOT.

**Pirogoff's operation.**—This operation closely resembles Syme's, save that the os calcis is sawn



through, and its hinder part is left in the heel flap. The lower ends of the tibia and fibula are sawn through, and to this cut surface of bone the surface of the divided os calcis is adjusted.

The operation usually described is a modification of Pirogoff's original procedure. Pirogoff divided the calcaneum vertically, and left the articular surface of the tibia, unless it was diseased.

*Position and instruments.*—The same as in Syme's

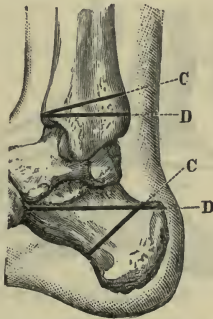


Fig. 43.—c c, Saw-cuts in Pirogoff's operation; d d, saw-cuts in Pasquier and Le Fort's operations; d shows also the saw-cut made in the os calcis in Tripier's operation.

operation. The saw should either be a fine Butcher's saw, or a slender saw with a movable back. Retractors are required.

*Operation.*—The incisions are nearly the same as in Syme's operation, with these modifications:—They commence on the outer side, just in front of the tip of the malleolus, and end on the inner side a few lines in front of the internal process. The heel incision is carried a little farther forward than in Syme's operation. It is carried well down to the bone. The

soft parts are dissected backwards from the os calcis for about a quarter of an inch.

The dorsal cut is then carried out, and may be a little more convex than in Syme's amputation. The ankle-joint is opened, and disarticulation effected precisely as already described.

The foot is now dragged forward and placed in the position of full extension.

The whole of the upper surface of the os calcis is

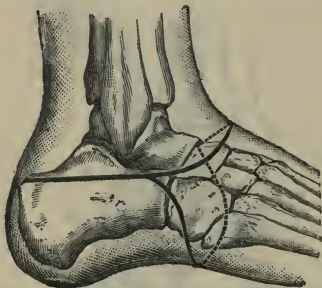


Fig. 44.—Pasquier and Le Fort's Operation.

exposed. The saw is now applied to this surface, one finger's-breadth behind the astragalus, and is made to cut the bone obliquely, following the lines of the now distorted heel incision. In sawing the bone, the soft parts must be carefully retracted, and, in the position in which the foot is held, the saw runs nearly vertically (Fig. 43, c). The greatest care must be taken not to damage the arteries in the inner part of the heel flap.

The soft parts are now dissected from the lower ends of the tibia and fibula. The saw is applied to the anterior aspect of these bones, close to the articular surface of the tibia, and is made to cut so obliquely

upwards that the saw emerges on the posterior aspect of the tibia, a finger's-breadth above the articular surface (Fig. 43, c). Any unduly long tendons are divided. The wound is sutured as in Syme's operation, the cut surfaces of bone being thus brought into close contact.

Care must be taken in the after-treatment that the heel fragment is not drawn up by the tendo Achillis.

**Le Fort's operation.**—This is a modification of Pirogoff's procedure. It is described by Farabeuf as "Pasquier-Le Fort's operation."

The skin incisions are shown in Fig. 44. The wound-lines conform to the racket rather than to the oval operation.

The calcaneum is cut horizontally just below the sustentaculum tali (Fig. 43, d).

The incision having been carried to the bone, the soft parts are dissected back as far as possible, especially on the dorsum and about the external part of the wound. The ankle-joint is opened from the outer side, the anterior and external ligaments being first attacked. The disarticulation is made complete, and the foot rotated very strongly outwards, so that the astragalus presents at the outer part of the wound.

The astragalus is now seized with large lion forceps and turned (together with the whole foot) still more outwards, until at last the forceps are quite horizontal. The upper portion of the os calcis is carefully cleaned, and all the part of the bone that requires removal will now be seen in the outer wound, the inner surface of the os calcis looking directly upwards. The saw is applied to the surface, just below the sustentaculum tali, and the bone is divided quite horizontally. The insertion of the tendo Achillis is preserved. The inferior and lateral ligaments of the calcaneo-cuboid joint having been divided, the foot is free.

The lower ends of the tibia and fibula are sawn through horizontally, just above the articular surface for the ankle-joint (Fig. 43, D).

It is claimed that this procedure is superior to Pirogoff's, on the following grounds:—A good thick flap, well supplied with blood, is provided. A larger amount of the soft parts that cover the heel is saved. The whole length of the os calcis rests upon the ground, and the patient is provided with a wider area of support. The parts are left in a more natural position.

#### **Tripier's operation.**—

This operation is really a modification of Chopart's amputation.

The dorsal incision has its concavity upwards and inwards. It commences at the outer edge of the tendo Achillis, on a level with the tip of the external malleolus. It sweeps forwards about one inch below that point of bone, passes a finger's-breadth behind the tuberosity of the metatarsal bone, and ends at the

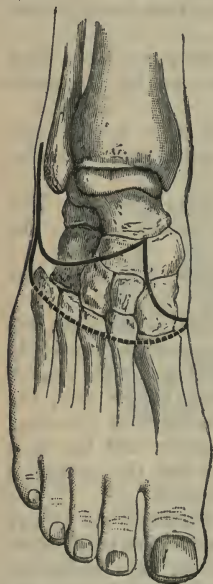

Fig. 45.—Tripier's Operation.

inner side of the extensor proprius pollicis tendon, two fingers'-breadths in front of the ankle-joint. The plantar incision commences at this point, is carried over the inner cuneiform bone at the internal margin of the foot, sweeps with a curve across the sole, reaches the outer edge of the foot about the base of the fifth

metatarsal, and then joins the dorsal incision (Fig. 45).

The incision extends to the bone. The flaps are dissected back so as to make clear the medio-tarsal joint. Disarticulation is now effected as in Chopart's operation. With a rugine the whole of the under part of the os calcis is bared of periosteum, the plantar flap having been dissected up as high as the sustentaculum tali. The os calcis is now seized with lion forceps, and so turned as to expose well its inner surface. The saw-cut is made horizontally, just below the sustentaculum, and runs from the inner to the outer surface (Fig. 43, D). The angle which the cut surface of the os calcis forms with the cuboid surface of that bone is finally rounded off with the saw, and the operation is complete.

## CHAPTER XV.

## AMPUTATION OF THE LEG.

THE amputations may be dealt with in three regions:—

- A. Supramalleolar amputation.
- B. Amputation through the middle of the leg.
- C. Amputation at the "place of election."

## A. SUPRAMALLEOLAR AMPUTATION.

**Methods.**—The following methods of operating will be described:—

1. Oblique elliptical incision (Guyon's operation).
2. Oblique elliptical incision (Duval's operation).
3. By large posterior flap.
4. Teale's amputation.

**Instruments.**—A small amputation knife with a blade of about five inches; a stout, somewhat narrow, knife, with a blade four inches long, a narrow but rounded point and a large, strong handle (this would be a modified resection knife and is required for Guyon's operation; it may also be used to separate the anterior or posterior flap from the bones in the other amputations); a scalpel, an amputating saw, retractors, pressure forceps, artery and dissecting forceps, scissors, etc.

**Position.**—The patient lies on the back, with the foot and lower part of the leg projecting well beyond the end of the table. The surgeon should stand to the outer side of the right limb, and to the inner side of the left. In performing Guyon's amputation he may

more conveniently take up his position at the foot of the table.

**1. Amputation by oblique elliptical incision** (*Guyon's operation*).—This operation a little resembles Syme's amputation. It allows the terminal part of the stump to be covered by the tissues of the back of the heel, and involves a low division of the

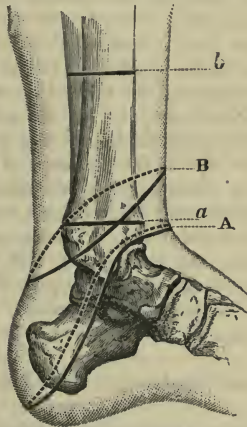


Fig. 46.—A, Guyon's supramalleolar amputation—(a) saw-line for that operation; B, Duval's supramalleolar amputation—(b) saw-line for this operation.

bones. It can rightly be termed a supramalleolar amputation, and the medullary canals of the bones are not opened by the saw.

The incision commences in front, at a point just opposite the line of the ankle-joint, and ends behind, over the summit of the curve of the heel.

Between these points the incision sweeps in a slightly curved manner from above downwards across

the ankle. The cut on the inner side just skirts the malleolus; on the outer side it passes a little in front of the corresponding process (Fig. 46, A).

The first incision involves merely the skin and the subcutaneous tissues. The surgeon then proceeds to dissect up the posterior or heel flap. This must include all the soft parts down to the bone. An exception may be made of the peronei tendons behind the external malleolus. They need not be disturbed, and should not be divided until a level above the ankle-joint has been reached. Great care must be taken of the vessels on the inner side of the os calcis. The tendo Achillis is cut, and the soft parts are cleared away from the bones of the leg up to a point about two inches above the tips of the malleoli. It is convenient to sit in order to dissect up the posterior flap.

The foot should now be extended, and the anterior incision carried well down to the bone, care being taken to avoid opening the ankle-joint. The soft parts on the front of the leg are dissected up to the level named.

Retractors having been adjusted, the bones are divided horizontally well above the bases of the malleoli.

The posterior tibial nerve should be dissected out and removed.

*Hæmorrhage.*—The anterior tibial artery is divided near the anterior border of the tibia. The posterior tibial vessel is cut at the inner side of the heel flap, and the termination of the peroneal at the outer side.

In the soft parts in front of the outer malleolus the anterior peroneal is divided.

**2. Amputation by oblique elliptical incision** (*Marcellin Duval's operation*).—In this operation the bone is divided much higher up than in Guyon's amputation. An oblique elliptical incision is made around the limb above the malleoli.

The incision is thus planned :—The point at which



the bones are to be divided having been determined upon, the lower or posterior extremity of the ellipse should reach a distance below that point equal to not less than the antero-posterior diameter of the limb at the level of the saw-cut. The higher, or anterior, extremity of the ellipse should be no less distance below the proposed saw-cut than that equal to half the antero-posterior diameter (Fig. 46, B).

The first incision includes the skin only. The skin is well separated and allowed to retract. The knife—kept close to the margin of the retracted skin—is now made to traverse all the soft parts down to the bone. The tendo Achillis is cut early. The tissues, on both the anterior and posterior aspects of the limb, are dissected up to a little beyond the level of the proposed saw-cut.

### 3. Amputation by a large posterior flap.—

Two flaps are made, the posterior being the larger. The length of the posterior flap, when completed, is equal to that of half the circumference of the limb at the saw-line. This is after retraction has been allowed for. As the flap may be considered to lose about one-third of its length by retraction, the posterior flap, as originally marked out on the skin, will to this extent exceed in length the measurement given.

The anterior flap is about one-fourth of the posterior. The flaps may be conveniently fashioned as shown in Fig. 49, A. The posterior flap reaches, so far as its skin limit is concerned, to about the insertion of the tendo Achillis. The internal vertical incision which limits it descends in front of the inner border of the tibia. The external vertical incision lies behind the fibula.

1. The skin incisions having been made and the tendo Achillis divided, the limb is well turned upon its outer side, and an incision is made through the exposed muscles down to the tibia. This deep

incision, which follows the line of the skin-cut, may be about two inches in length. It should be deepened by separating the muscles from the tibia. The limb is then turned upon its inner side, and a like incision is made down to the fibula, and the wound is deepened, so far as it extends, by separating the muscles from that bone. In this manner two deep lateral slits or gaps (*fentes*) are made down to the bones through the whole thickness of the posterior flap.

The thumb having been thrust into one of these gaps, and the forefinger into the other, the soft parts at the back of the limb can then be pinched up by the surgeon's left hand. The foot is maintained in the flexed position, while the posterior flap is completed by cutting from without inwards. The posterior flap so fashioned leaves the bones and the interosseous membrane practically free.

2. The anterior flap is now cut. The soft parts are divided down to the bones as soon as the skin has fully retracted, and are then dissected up so as to leave the bones and the interosseous membrane on this aspect of the limb practically bare also.

3. Retractors having been adjusted and the interosseous membrane divided, the tibia and fibula are sawn through; the posterior tibial nerve is dissected out and removed.

Deep sutures may be passed between the muscular masses upon the front and back of the limb.

*Hæmorrhage.*—The anterior tibial artery is cut in the anterior flap, in front of the interosseous space. The posterior tibial and peroneal vessels are divided posteriorly; the former about the middle of the flap, and the latter in a line with the fibula. The internal saphenous vein may possibly be cut in making the internal vertical incision.

4. **Teale's amputation by a large anterior flap.**—The lower third of the leg is considered to be

a particularly favourable position for the practice of Teale's amputation.

The circumference of the limb having been taken at the level of the future saw-line, the anterior flap is so marked out that in its length, as well as in its breadth, it shall be equal to one-half the circumference.

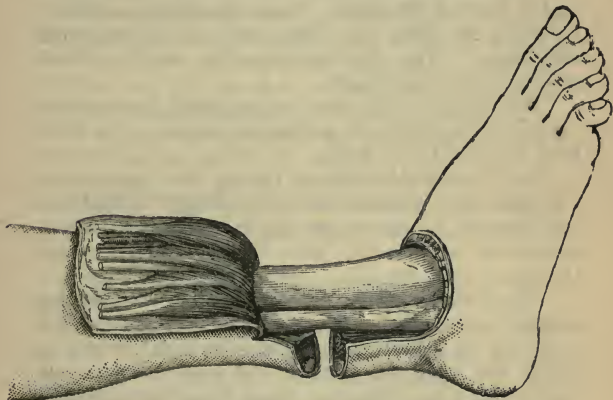


Fig. 47.—Teale's Amputation of the Leg.

The posterior flap should be one-fourth the length of the anterior flap, and will include the remaining half of the circumference of the limb (Fig. 47).

The lateral incisions follow the margins of the tibia and fibula. The limits of the greater flap may be conveniently marked out upon the skin with ink.

The anterior flap may be commenced on the inner side of the limb on the right side, and on the outer aspect on the left side. The two lateral incisions should be made by cutting from above downwards. It should be remembered that the anterior flap is rectangular, and of the same size all the way down.

The incision marking out the great flap should at first concern the skin only. The incision is then deepened down to the bones. The foot should be extended while the tendons at the end of the flap are being divided.

The anterior flap should contain all the soft parts on the front of the limb. These should be carefully dissected up from the bones and the interosseous membrane. The flap contains the anterior tibial artery in its whole length.

The posterior flap may be completed by a simple vigorous transverse cut across the back of the limb from the skin to the bones.

The foot should be flexed during this manœuvre. The flaps having been retracted to a little beyond the saw-line, the retractors are applied, the interosseous membrane is divided, and the bones are sawn through.

*Hæmorrhage.*—The anterior tibial vessels are divided at the free lower end of the anterior flap, and at about its middle. The posterior tibial artery is found cut upon the face of the posterior flap and towards its inner side, the vessel lying between the margins of the flexor longus digitorum and flexor longus pollicis.

The peroneal vessels are divided on the outer part of this flap, close to the fibula, and under cover of the flexor longus pollicis.

The long saphenous vein will be found in the anterior flap, the short saphenous in the posterior flap.

*Comment.*—Inasmuch as the leg narrows towards the ankle, it is easy, by following the general lines of the limb, to make the anterior flap too narrow below.

It is claimed for this amputation that the bones are covered by a flap which does not contain too much muscular tissue, and which possesses an artery in its entire length. It is also urged that the cicatrix is

placed at the back of the stump, and is not exposed to pressure.

Teale's amputation makes a great demand upon the structures on the anterior aspect of the limb, and involves a comparatively high division of the bones.

Of the other operations above described, it may be said in general terms that Guyon's amputation is the best when a low division of the bones is possible, and that the most suitable mode of amputating the leg in its lower third is by means of the long posterior flap.

A mode of amputation by a modified circular method is shown in Fig. 48, A.

#### B. AMPUTATION THROUGH THE MIDDLE OF THE LEG.

The procedure best adapted for this region is the following :—

**Amputation by a large posterior flap** (*Hey's operation*).

*Instruments.*—An amputating knife with a blade about five inches in length ; a stout scalpel ; an amputating saw ; retractors (the linen retractor used to protect the parts during the sawing of the bones may have three tails, the central and narrower slip being passed through the interosseous space) ; pressure forceps ; artery and dissecting forceps ; a periosteal elevator ; scissors, etc.

*Position.*—The patient lies upon the back, with the leg and knee beyond the end of the table. In dealing with the right limb, the surgeon stands to the outer side of the leg ; in dealing with the left limb, to the inner side.

The circumference of the limb at the saw-line having been noted, the posterior flap is so made that its length and breadth are equal to a third of that measurement—*i.e.* are equal to the diameter of the limb.

The anterior flap is about a third of the length of

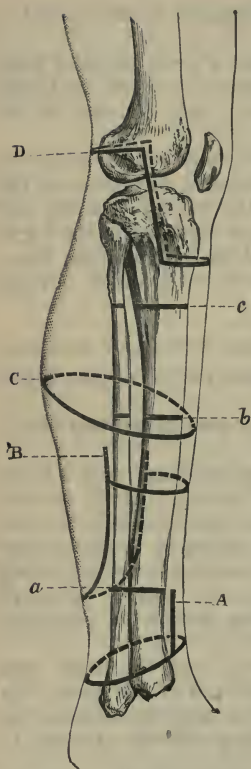


Fig. 48. — A, Modified circular supramalleolar amputation — (a) saw-line of same; B, Hey's amputation — (b) saw-line of same; C, circular amputation at "the place of election" — (c) saw-line of same; D, Gritti's operation.

the posterior one. The large posterior flap is U-shaped. The main incisions are commenced about one inch below the point at which the bones are divided. The inner limb of the U of the posterior flap is just behind the internal border of the tibia, while the outer limb of the U runs posterior to the peronei muscles (Fig. 48, B). These muscles are consequently found divided in the anterior flap.

1. The operation is commenced by cutting the large flap.

On the right side the limb is turned upon its outer surface (*i.e.* with that surface looking downwards), the knee is flexed, and the inner vertical incision is made from above downwards. The inner segment of the bend of the U is then completed. The leg is now turned upon its inner side, and the outer vertical incision is made by cutting from above downwards. In finishing it, the bend of the U, the terminal part of the flap, is completed (Fig. 48, B).

On the left leg the limb may be first turned upon its inner side, and the operation be commenced by cutting the outer vertical incision.

The incisions thus made concern the skin only, and the integuments are well freed along all parts of the cut.

2. The leg is now flexed upon the thigh, and the knee turned outwards so as to expose the calf. When in this position, and while the foot is flexed, the gastrocnemius muscle is picked up between the fingers and thumb and is divided transversely at the level of the retracted skin.

3. Two short, deep, vertical incisions are now made from above downwards through the soft parts at either margin of the flap. These incisions extend to the bone: the inner direct to the tibia, the outer to the fibula behind the peronei muscles.

Into the gaps thus made the thumb and fingers of the left hand are inserted, and the muscles of the calf, being firmly grasped, are lifted up from the bones.

The muscles are now carefully separated from the bones along these two short lateral incisions with a stout scalpel until the middle of the flap is entirely free, and the thumb and forefinger can be made to meet between the deep muscles and the bones. These muscles and the vessels they carry with them are finally divided at their lower parts by a vigorous transverse cut. To effect this, the amputating knife is introduced between the separated muscles and the bones, and is made to cut from within outwards. The posterior flap is now quite free below, and the soft parts above are cleared away from the tibia and fibula and intervening membrane until the level of the saw-cut is reached.

4. The anterior flap is made by passing the knife in a curved manner across the face of the limb. The incision at first involves the skin only. When

retraction has taken place, the muscles are cleanly divided down to the bones. These muscles are then dissected up as far as the level of the future saw-cut, the interosseous membrane being thus bared in front as well as behind.

5. Retractors having been applied, and the interosseous membrane divided transversely, the bones are sawn through. The periosteum may be separated from the lower end of the tibia.

The prominent projection of the anterior border of the tibia should be removed with the saw in the manner described on page 483. (*See Fig. 52.*)

The posterior tibial nerve is dissected out and removed.

*Hæmorrhage.*—The anterior tibial artery is divided at the free end of the anterior flap, the posterior tibial and peroneal vessels at the free margin of the posterior flap. The position of these vessels has been already indicated.

#### C. AMPUTATION AT THE "PLACE OF ELECTION."

The term "place of election" refers to the spot at which the bones are divided. This point is about a hand's-breadth below the knee-joint, and is about, or a little above, the great nutrient foramen of the tibia. The tibia is here still of good size, the cancellous tissue is considerable, but the medullary canal has commenced.

The following are the *methods* described:—

1. Large external flap (*Farabeuf's operation*).
2. Circular method.
3. Equal lateral flaps.

#### 1. Amputation by large external flap (*Farabeuf's operation*).

*Instruments.*—An amputating knife with a blade from five to six inches in length; a stout scalpel; an amputating saw; a periosteal elevator;



retractors; six pressure forceps; artery and dissecting forceps; scissors, etc.

*Position.* — The patient lies upon the back, and is so placed that the middle of the thigh rests upon the edge of the table. The sound limb is secured out of the range of the operation.

In operating upon the right leg, the surgeon stands throughout on the outer side of the limb. In amputating the left leg, he should stand at the end of the limb, and a little to the outer side of it, while making the preliminary skin incisions. While dissecting up the flap and completing the operation, he should stand to the inner side of the limb.

*Operation.* — The external flap is U-shaped. Its length is equal to that of the diameter of the limb at the level of the future saw-line — *i.e.* is equivalent to one-third of the circumference of the leg at the same level (Fig. 49, B).

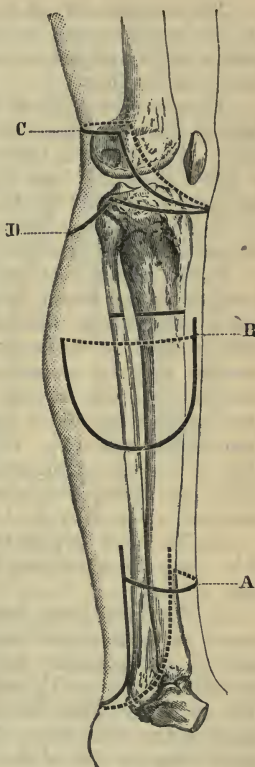


Fig. 49.—A, Amputation of lower part of leg by long posterior flap; B, amputation at "the place of election" by large external flap (Farabeuf's operation); c, Carden's amputation; d, Lister's modification of the same

The anterior limb of the **U** is commenced opposite to the saw-line, and in passing down the leg runs parallel with and just to the inner side of the anterior border of the tibia.

The posterior limb of the **U** follows a line on the back of the calf diametrically opposite to the anterior limb. The posterior incision ends, however, above, at a point about  $1\frac{1}{2}$  inch below the commencement of the anterior limb of the **U**.

1. The operation is commenced by marking out the external flap by a skin incision.

In the case of both the right and the left legs, the knee should be flexed and the limb turned upon its inner side—*i.e.* so turned that its outer aspect is well exposed to the surgeon. On the right side the incision may be commenced in front, and may be completed in one sweep, the anterior wound being thus made from above downwards and the posterior from below upwards. In the case of the left limb, both of the vertical incisions can be more conveniently made by cutting from above downwards, and can be afterwards joined by the terminal curved incision.

2. The next step in the operation is to free the skin along the whole length of the incision, so that it may retract.

3. The limb being turned outwards, the knife is passed across the inner side of the leg, from the upper end of the posterior incision to a point on the anterior cut about  $1\frac{1}{2}$  inch below its commencement (Fig. 49, B). This incision is slightly curved, and involves the skin only. The integuments are lightly freed along the line of the incision.

4. The limb being again turned with its inner surface downwards, the operator proceeds to dissect up the great flap, which should contain all the soft parts down to the bones.

The flap is separated along the anterior limb of the

**U** incision by cutting from above downwards down to the bone along the outer side of the anterior border of the tibia. The fingers of the left hand are thrust into the gap so made, and the tibialis anticus is separated from the bone. When the muscle is sufficiently separated, it is cut obliquely from above downwards

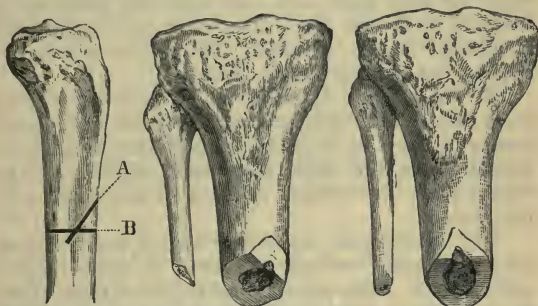


Fig. 50.—Method of Sawing the Tibia.

Fig. 51.—Method of Sawing the Bones of the Leg.

Fig. 52.—Method of Sawing the Bones of the Leg.

and outwards, so that the section of the muscle will be thin when the margin of the skin is reached.

The whole of the soft parts involved in the external flap are dissected up from the bones and interosseous membrane. In effecting this the finger and the handle of a scalpel are used more freely than the knife. The muscles should be cut obliquely at their lower extremities, so that the section of muscle close to the free margin of the skin—*i.e.* at the bend of the **U**—shall be quite thin. The anterior tibial artery is divided at the free end of the flap in making one of these oblique sections of the muscles.

In dissecting up the soft parts, great care must be taken not to dissect the flap up too far. If this be done, it is possible to reach the spot where the

anterior tibial artery is piercing the interosseous membrane, and to actually divide the vessel at that spot.

5. The soft parts included in the small inner flap may now be cut by transfixion at the level of the retracted skin. The muscular tissue so divided must be in the next place separated from the bones up to the level of the saw-line. The bones and interosseous membrane should be bared. The retractors are now applied and the bones sawn through.

6. The manner in which *the bones are sawn* is of some importance, especially as the prominent anterior border of the tibia is apt to project into the anterior wound when the flaps have been adjusted. The remarks now to be made apply to all amputations in this region.

The interosseous membrane having been incised, the periosteum covering the tibia is divided by a circular cut. This circular cut is joined from above by two lateral vertical incisions through the investing membrane. The two flaps—*anterior and posterior*—of periosteum thus marked out should be separated from the bone by an elevator. If preferred, these flaps may be dissected up from the bone with the deepest layers of muscle; or, on the other hand, the periosteum on the posterior surface of the tibia may be ignored, and only the anterior segment preserved. Some surgeons strip up the periosteum from the fibula also.

The periosteum is retracted to a point just above the saw-line. The surgeon stands in the same position—*i.e.* to the outer side of the right leg and to the inner side of the left—and divides the fibula first. The limb is still so placed that the external surface is uppermost. In sawing the left fibula, the point of the saw is directed downwards, towards the floor. In dividing the right bone, the point of the

instrument is directed upwards, towards the ceiling. The fibula should be divided about 1 c.m. above the tibia, and the saw should pass obliquely from above downwards and inwards (Fig. 51). The saw is now entered upon the inner surface of the tibia, above the level at which the bone is to be divided. The instrument is made to cut downwards and outwards for a certain distance (Fig. 50, A). The transverse saw-cut is now made from before backwards (Fig. 50, B), with the result that the whole bone is divided, the piece marked out by the first saw-incision drops off, and the tibia presents a sloping surface on its inner side (Fig. 51).

This method of dividing the bones is adapted to the amputations by external flap or by two lateral flaps.

In the case of amputation by antero-posterior flaps or by the circular method, the fibula may be cut at the same level as the tibia, and the anterior margin of the tibia should then be removed by a sloping saw-cut, the instrument being applied in the manner just detailed (Figs. 50 and 52).

*Hemorrhage.*—The anterior tibial artery is divided at the free end of the external flap. The posterior tibial and peroneal vessels are cut close together and lie on the same plane upon the face of the inner flap.

Several muscular branches will require ligature, notably the sural arteries connected with the gastrocnemius muscle, and the large branch from the posterior tibial artery to the soleus. The nutrient artery of the tibia will be divided at or about its entrance into the bone.

## 2. Amputation by the circular method.

—The circular skin-incision should be made at a distance below the saw-line equal to one-half of the diameter of the limb at that line (Fig. 48, c). This

applies to the position of the incision when retraction of the skin has been allowed for.

The posterior segment of the circular incision should be a little higher than the anterior segment. The tissues at the back of the leg—notably the superficial flexors—retract more readily than do the soft parts upon the front of the limb. If the circular incision be quite horizontal, too much skin will be found in what may be termed the posterior flap.

*Operation.*—The limb being extended, the circular skin-incision is made. The skin is freed all round along the line of the incision.

The knee is now flexed, and the calf being well exposed, the gastrocnemius muscle is separated from the deep flexors with the fingers, and is divided transversely at the level of the retracted skin.

The integuments all round are retracted as high as possible, the gastrocnemius muscle being separated up with the skin at the posterior part of the leg.

The soft parts are now divided transversely a little below the saw-section and are then separated all round from the bones and the interosseous membrane, and the separation is carried to a point a little above the saw-line.

Retractors having been applied, the tibia and fibula must now be sawn in the manner described on page 192. The bones after division will present the appearance shown in Fig. 52.

### 3. Amputation by equal lateral flaps.—

The general shape and position of the flaps are shown in Fig. 53, A. The flaps are semilunar in outline. The anterior median incision is commenced some 2 c.m. below the future saw-line, and is carried vertically downwards just to the outer side of the crest or anterior border of the tibia. The posterior incision is commenced on the back of the leg, at a

point diametrically opposite to the commencement of the anterior incision.

In length each flap should slightly exceed the half-diameter of the limb at the saw line, retraction being allowed for.

Thus, if the half-diameter be  $2\frac{1}{2}$  inches, or 6 c.m., the lowest curve of each flap may reach to a point  $3\frac{1}{2}$  inches, or 9 c.m., below the saw-line. When the skin has retracted, each flap will be found to be about  $2\frac{1}{2}$  inches in length.

The flaps are dissected up as skin flaps.

A little way below the saw-line the soft parts of the limb are divided transversely down to the bones. They are then separated from the bones, and the operation is completed as in amputation by the circular method. The bones are divided as shown in Fig. 52.

This operation is merely a modification of the circular amputation. It is easier to perform. The cicatrix is antero-posterior instead of being transverse.

## CHAPTER XVI.

## DISARTICULATION AT THE KNEE-JOINT.

THE following methods are here described :—

1. Disarticulation by lateral flaps (Stephen Smith's operation).
2. Disarticulation by elliptical incision (Bauden's operation).
3. Disarticulation by long anterior flap.

**1. Disarticulation by lateral flaps** (*Stephen Smith's operation*).—The flaps consist of the integuments only, the posterior muscles being divided transversely about the level of the articulation.

*Instruments.*—An amputating knife with a blade five to six inches in length ; a stout scalpel ; six pressure forceps ; artery and dissecting forceps ; retractors, scissors, etc.

*Position.*—The patient lies upon the back, and is so placed that the middle of the thigh rests upon the lower margin of the table. The sound limb is secured out of the way. The surgeon stands to the outer side of the right leg, to the inner side of the left.

*Operation.*—The flaps are of somewhat semilunar outline. The incision commences in front, in the median line, about one inch below the tubercle of the tibia. It is carried in a curved manner across the most prominent part of the outer side of the leg, and is then made to slope upwards to reach the middle line at the posterior aspect of the limb. It terminates as a vertical cut opposite the centre of the inter-articular line.

A second incision begins at the same point on the



front of the limb as the first, and pursues a similar direction across the inner side of the leg, meeting the first incision at the median line upon the posterior aspect of the extremity. The inner flap should be a little fuller than the outer, in order to ensure a sufficient covering for the internal condyle, which is longer and larger than the external.

The outline of the flaps is shown in Fig. 54, A.

1. The skin incisions on both the right and the left leg are more conveniently made by cutting from behind forwards.

The knee-joint should be extended during the cutting of the flaps.

2. The skin is freed all round, and the two flaps are dissected up. They should include all the soft parts down to the tendons and muscles, which are well laid bare, but are as yet left uncut. The patellar ligament is cut as soon as it is reached.

The flaps are retracted to the level of the joint-line.

3. An incision is now made along the extreme upper margin of the tibia. This incision, which is transverse and concerns the anterior and lateral

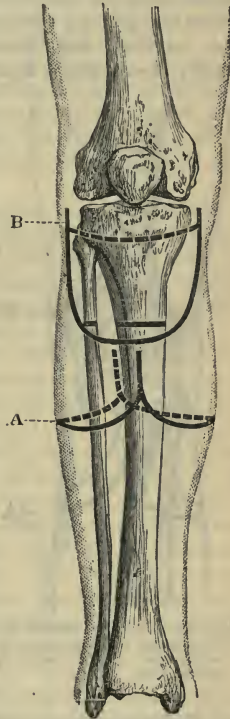


Fig. 53.—A, Amputation at "the place of election" by lateral flaps; B, disarticulation at the knee by long anterior flap.

aspects of the bone, divides everything down to the bone, including the ilio-tibial band, the tendons of the sartorius, gracilis, semitendinosus and biceps muscles, the internal and external lateral ligaments, and, lastly, the coronary ligaments attaching the semilunar

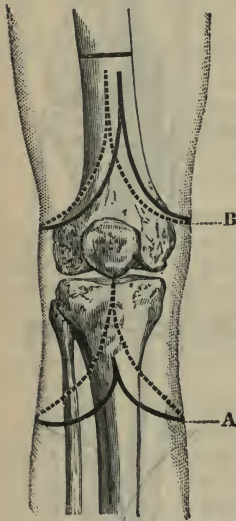


Fig. 54.—A, Stephen Smith's disarticulation at the knee; B, amputation of the thigh by lateral flaps.

cartilages. The knife, indeed, enters the joint between the upper surface of the tibia and these cartilages, and it is in this manner that the articulation is opened. In dividing the coronary ligaments the knife should be entered at the sides of the joint, and not in front.

The knee is now flexed, and the two crucial ligaments are carefully divided from before backwards.

4. Nothing remains but to divide by a vigorous transverse cut the soft parts still connecting the leg with the thigh, viz. the posterior ligament of the joint, the popliteal vessels and nerves, the popliteus and gastrocnemius muscles, and the semimembranosus or other undivided tendon of the ham.

Before making this final incision, the assistant who is retracting the flaps should compress the popliteal artery against the lower end of the femur.

*Hæmorrhage.*—The popliteal artery and vein are the only vessels of any size requiring ligature. Ligatures will probably be needed for the sural

arteries, the azygos artery, for branches of the superior articular vessels (especially on the outer side), and for the superficial division of the anastomotica magna (on the inner side of the limb).

*Comment.*—This operation provides an excellent and complete covering for the condyles of the femur. When the edges of the flaps are brought together, the wound looks directly downwards as the patient lies in bed. The stump, therefore, is admirably provided for in the matter of drainage.

The cicatrix lies in an antero-posterior direction between the condyles, and in process of time occupies the intercondyloid notch. Into this depression it sinks, and the prominent condyles serve to effectually protect it from pressure. Both the patella and the semilunar cartilages are left in the stump.

**2. Disarticulation by elliptical incision** (*Bauden's operation*).—The *instruments* required and the *position* of the patient and of the surgeon are the same as in the previous operation.

The interarticular line having been made out, the antero-posterior diameter of the limb at this line is estimated. The elliptical incision is so planned that its lowest part crosses the crest of the tibia, at a distance below the joint-line equal to the antero-posterior diameter of the limb. The highest part of the ellipse reaches the median line posteriorly at a distance of half a diameter below the same line. The incision is inclined at an angle of about 30 degrees.

The incision is carried through the integuments, which are then well freed along the whole extent of the wound.

The skin on the anterior aspect of the limb is turned up in the form of a cuff, while that upon the posterior side of the leg is displaced upwards by gliding merely.

By the employment of these two methods the integuments are retracted as far as the patella, the knee-joint being kept extended during the process.

The limb is now flexed a little, the patella ligament is divided, and the articulation is entered by passing the knife between the semilunar cartilages and the head of the tibia, as in the operation last described.

Both the patella and the semilunar cartilages are preserved.

The ligaments having been divided as already described, the soft parts at the back of the joint are severed by a circular cut with the knife, made from before backwards.

The cicatrix resulting from this operation is transverse, and is placed upon the posterior aspect of the limb. A very excellent stump is obtained.

### 3. **Disarticulation by long anterior flap.**—

Both of the flaps are skin flaps, and are somewhat rectangular in outline (Fig. 53, B).

“I feel,” writes Mr. Pollock, the author of the operation, “for the interval between the edges of the outer condyle and head of the tibia, and commence my incision at that point, and immediately behind the edge of the hamstring muscle as it crosses that space. I take especial care never to commence my incision higher than the margin of the condyle. The incision should be carried perpendicularly downwards on the side of the leg till nearly five inches below the lower edge of the patella, then gradually brought across the front of the leg, and when crossing the tibia should be quite five inches below the patella, then carried up the inner side to a point corresponding exactly to that from which the incision commenced. I usually make the posterior flap by cutting from without inwards; it should not be too short, and should consist merely of integument. As soon as the flaps are completed, all

the structures round the joint should be divided at right angles with the limb." The patella is left.

The resulting cicatrix is transverse, and is placed upon the posterior aspect of the stump.

**Comment.**—Of these operations the best is certainly that first described—the disarticulation by lateral flaps. It is simple and is easily performed.

The operation by the long anterior flap was for many years the chief method employed by English surgeons for amputations at the knee-joint. The method, however, does not compare favourably with the two other operations described. The long anterior flap does not in the first place provide so good a covering for the condyles. In the second instance it is of so great a length, and so thin in substance, that it is of necessity ill-nourished and liable to slough.

The operation by the long anterior flap makes, moreover, a great demand upon one particular side of the limb, the wound is not so well adapted for spontaneous drainage, and in the resulting stump the cicatrix is not quite so favourably placed.

## CHAPTER XVII.

## AMPUTATION OF THE THIGH THROUGH THE CONDYLES.

IN this operation the femur is divided at the bases of the condyles, about the level of the tubercle for the insertion of the adductor magnus tendon, or a little above that spot. The patella is removed.

**Instruments.**—Amputating knife five to six inches in length as regards its blade; stout scalpel; Butcher's saw; retractors; six pressure forceps; artery and dissecting forceps; scissors, etc.; lion forceps may be required.

**Position.**—The position of the surgeon and of his assistants is the same as in the last series of operations (page 196).

Three **methods** will be described:—

1. Carden's operation.
2. Modifications of Carden's operation.
3. Gritti's operation.

**1. Carden's operation.**—"This operation," Carden writes, "consists in reflecting a rounded or semi-oval flap of skin and fat from the front of the joint, dividing everything else straight down to the bone, and sawing the bone slightly above the plane of the muscles, thus forming a flat-faced stump with a bonnet of integument to fall over it."

The procedure might be described in detail as follows:—

1. The incision is commenced at the most prominent part of the tuberosity of one condyle, and ends at a corresponding point on the other condyle. The cut over the front of the limb sweeps with an easy curve

between these two points, and crosses the median line about the middle of the patellar ligament. The posterior incision is quite horizontal (Fig. 49, c).

The anterior cut is made first. The points of starting and ending may be marked by the thumb and forefinger. The knee-joint is a little flexed as this incision is being made. In the right limb it is commenced on the inner side, and in the left extremity on the outer side. The assistant rotates the limb as the knife passes across it.

The posterior incision is made by one single transverse sweep. Both incisions should involve at first only the skin and the subcutaneous tissues.

2. The limb being extended, the anterior flap is dissected up, containing all the soft parts down to the patella and the capsule of the joint. The posterior "flap" may be a little freed and allowed to glide up, in order to aid the separation of the anterior flap.

3. The knee being flexed, the joint is opened by cutting through the quadriceps tendon just above the patella. That bone is seized by the surgeon, and the anterior capsule divided on either side. The crucial and lateral ligaments are cut. With one vigorous sweep of the knife the tissues at the posterior aspect of the limb are then divided down to the bone at the level of the hinder skin incision.

A few touches with the knife serve to entirely separate the leg.

4. The soft parts are now retracted so as to clear the bone for the passage of the saw. In dividing the femur the saw must be kept parallel to the articular surface and perpendicular to the shaft.

In young subjects regard must be had for the epiphyseal line.

*Hæmorrhage.*—The popliteal artery is divided close to the bone at its inner aspect. Some muscular branches may require ligature.

On the cut surface of the posterior flap will be found the two superior articular branches from the popliteal (divided close to the femur), and the *anastomotica magna* (on the inner side). Branches of the latter vessel and of the descending portion of the external circumflex may require to be secured in the margins of the anterior flap.

## 2. Modifications of Carden's operation.

A. Sir Joseph Lister writes as follows:—

“I found it advantageous to form a short posterior skin flap, both for the sake of coaptation of the cutaneous margins without puckering, and as a useful addition to the covering for the end of the stump.

“The surgeon first cuts transversely across the front of the limb, from side to side, at the level of the anterior tuberosity of the tibia, and joins the horns of this incision posteriorly by carrying the knife at an angle of forty-five degrees to the axis of the leg through the skin and fat (Fig. 49, D). The limb being elevated, he dissects up the posterior skin flap, and then proceeds to raise the ring of integument as in a circular operation, taking due care to avoid scoring the subcutaneous tissue, and dividing the hamstrings as soon as they are exposed; and bending the knee, he finds no difficulty in exposing the upper border of the patella. He then sinks his knife through the insertion of the quadriceps extensor, and having cleared the bone immediately above the articular cartilage, and holding the limb horizontal, he applies the saw vertically, and at the same time transversely, to the axis of the limb (not of the bone), so as to ensure a horizontal surface for the patient to rest on.”

B. Farabeuf's modification of Carden's procedure is practically a new operation. The femur is divided at the same level, but different flaps are cut. The anterior flap exceeds in length the antero-posterior diameter of the limb at the saw-line by about an inch.



The posterior flap is equal to half that diameter. The lateral incisions which mark out the anterior flap commence just below the joint-line (Fig. 55). The outer cut descends on the fibula, the inner is placed about two inches behind the inner edge of the tibia.

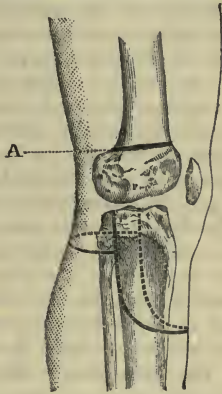


Fig. 55.—Farabeuf's Amputation through the Condyles of the Femur.

A, Line of saw-cut.

The anterior flap, therefore, will occupy more than half the circumference of the limb.

The steps of the operation are precisely the same as in Carden's method. An excellent stump is provided.

The cicatrix in these operations is found upon the posterior aspect of the limb.

3. **Gritti's operation.**—This operation was designed by Rocco Gritti, of Milan, in 1857.

The patella is retained, but its articular surface is removed with the saw. To effect this the bone has practically to be bisected. The femur is divided transversely at the upper edge of the articular surface—*i.e.* about the level of the adductor magnus tubercle.

The two sawn surfaces of bone are brought together, and it is presumed that they will unite, that the patella will form the summit of the stump, and that upon it the weight of the body will be borne.

*Operation.*—The position of the patient, and of the surgeon, is the same as in the preceding operations. In addition to the instruments enumerated, the following are required:—A fine metacarpal saw, or small Butcher's saw, for the patella; a pair of lion forceps to hold the patella; cutting pliers, in the event of the articular surface of the patella being removed by cutting rather than by the saw; a bone-drill; stout catgut or wire sutures or pegs for the bones.

An anterior flap is made which commences on either side at the level of the tuberosities of the femoral condyles, and which reaches below to the lowest part of the tubercle of the tibia. This flap is rectangular in outline (Fig. 48, D). The skin at the back of the limb is divided transversely or by an incision which is inclined a little downwards. The general steps of the operation are the same as those already given.

The anterior flap is dissected up as soon as the ligamentum patellæ has been divided at its insertion. This flap is turned up with the patella in it undisturbed. The knee-joint having been opened, disarticulation is effected, and the soft parts at the back of the limb are divided by a sweep of the knife. The lower end of the femur is removed with the saw. Finally, the articular surface of the patella is sawn off or removed by cutting pliers.

The parts are finally adjusted when all the bleeding points have been secured. The cicatrix is entirely posterior.

The sawing of the patella presents the only difficult step in the operation. The bone should be held vertically by an assistant, who grasps the anterior flap with

both hands, and so holds it that the patella is made to stand out from its surface. Another assistant should steady the bone with a pair of broad lion forceps while the saw is being entered.

During the process of sawing, the surgeon should grasp the ligamentum patellæ with stout forceps, held in the left hand. In order to take advantage of this means of steadying the patella, the ligament should be cut as long as possible.

The bones may be kept in position either by closely suturing the soft parts above the patella to the posterior flap, or by drilling the bones and securing them by wire or catgut sutures or by pegs.

**Comment.**—In commenting upon these various procedures it may, in the first place, be said that the best method of removing the limb about the knee is undoubtedly by disarticulation.

Of the methods described, Carden's is probably the best. If, however, the flaps are cut precisely as Carden directed, they will often be found to provide but a scanty covering for the bones.

Either of the two modifications of Carden's operation is to be recommended in the place of the original procedure. They both give admirable results.

Considerable differences of opinion have been expressed as to the value of Gritti's operation.

## CHAPTER XVIII.

## AMPUTATION OF THE THIGH.

THE operations so named concern amputation through the shaft of the femur, and occupy an intermediate position between disarticulation at the hip-joint on the one hand, and the supracondyloid or transcondyloid operations on the other. For the most part they involve a division of the bone at or below its centre.

The following **methods** of amputating the thigh will be described :—

1. Circular method.
2. Syme's modification of the circular method.
3. By long anterior and short posterior flaps.
4. By lateral flaps.

The comparative value of these different methods, and their applicability to different portions of the thigh, are considered on page 216.

**Instruments.**—Large amputating knives (for the circular operation the blade should be about 7 or 8 inches in length, and for cutting flaps by transfixion about 9 to 10 inches ; these measurements refer to the amputation as applied to the average adult limb ; in marking out skin flaps, in dissecting up the integuments, and in shaping muscular flaps by cutting, a stout knife with a four-inch blade should be employed) ; a full-sized amputation saw ; a small Butcher's saw, to shape the end of the divided femur ; a dozen pressure forceps ; artery and dissecting forceps ; retractors, scissors, needles, etc.

**Position.**—The patient's buttocks rest upon the end of the table. The sound leg is secured out of the way. Means should be taken to prevent the body

from slipping off the table. The surgeon stands to the right of the limb in the case of either extremity.

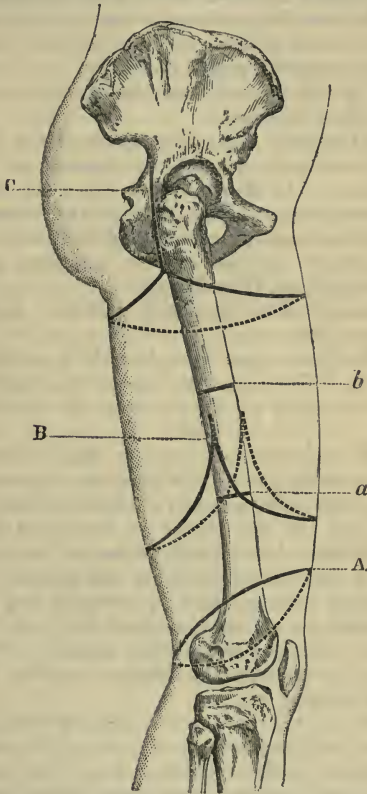


Fig. 56.—A, Circular amputation of thigh—(a) saw-line of same; B, amputation of thigh by equal antero-posterior flaps—(b) saw-line of same; C, disarticulation at the hip by external ratchet incision.

1. **The circular amputation.**—Owing to the unequal manner in which the divided muscles retract, the simple circular operation is not adapted for the thigh. In order to allow for this irregular retraction, the incision must be placed obliquely.

This operation should only be carried out in the lower third of the limb.

On the anterior and outer aspects of the limb the distance between the level of the proposed saw-cut and the incision on the skin should be equal to one-fourth of the circumference of the thigh at the former point. On the hinder and inner aspects of the limb the skin-incision should be made a little less than half this length lower down (Fig. 56, A).

*Operation.*—The proposed incision should be marked upon the skin.

1. The circular cut is made with a sweep of the long knife. The assistant rotates the thigh in an opposite direction to the knife as the blade passes round.

2. The assistant now retracts the skin while the surgeon frees it all round. It must be retracted evenly, so as to preserve the original obliquity of the incision.

3. When the skin has been separated from the deeper parts and retracted as far as required, the superficial muscles on the inner and posterior aspects of the thigh (the hamstrings, sartorius and gracilis) are divided by a vigorous sweep of the knife. When they have retracted, the deeper muscles are severed down to the bone at the highest possible level by another sweeping cut.

In dividing the muscles the obliquity of the original incision is still maintained—*i.e.* the knife crosses the limb parallel to the original skin-cut, and as close as possible to the now retracted margin of the integument.

4. The bone is cleared, retractors are applied, and the femur is sawn through. “In sawing the femur

the position of the thick ridge (*linea aspera*) at its posterior aspect is to be remembered, and the saw, at first horizontal, must be brought nearly vertical so soon as a groove is cut, in order that the *linea aspera* may be divided early, and not left to break and form a projecting spike" (*C. Heath*).

It is well to saw off the superior and inferior margins of the end of the bone obliquely, so as to round it. This may be conveniently performed by a small Butcher's saw.

The cicatrix will be transverse or oblique. In the latter case it will incline from in front backwards and inwards.

*Hæmorrhage*.—The position of the femoral artery upon the face of the stump will depend upon the level at which the tissues are divided.

If the amputation be through the lower third of the thigh, the *anastomotica magna* will be divided. If above this level, the *profunda* will be found to be cut. The descending branch of the external circumflex artery will require a ligature as it lies cut on the antero-external aspect of the stump. One or more of the perforating arteries and many muscular branches may need to be secured.

**2. Syme's modification of the circular amputation.**—By this method the circular operation is simplified. The skin is much more easily dissected up, and the integuments are less roughly handled in the process of separation.

The *operation* consists practically of the usual circular incision, with two lateral cuts to aid the retraction of the skin.

Two very short antero-posterior flaps of semilunar outline and of equal width and length are dissected up. They are composed simply of the integument and subcutaneous tissues, and consist of little more than curved incisions made across the front and the back

of the thigh, each being equal to one-half of the circumference of the limb.

The skin beyond the little flaps is, in its turn, separated—just as in the usual circular method—and is reflected until a point is reached some two inches above the bases of the small antero-posterior flaps.

The anterior femoral muscles are now divided down to the bone by a transverse sweep of the knife at the level of the retracted skin. The posterior muscles are severed in like manner, but at the level at which they were first uncovered in forming the posterior flap.

“The muscles,” as Syme puts it, “should be divided right down to the bone, on a level as high as they are exposed in front, as low as they are exposed behind.”

The muscular tissue after division is further retracted, so as to clear the bone well. The femur is ultimately sawn about two inches above the level of the spot at which the anterior muscles were divided.

**3. Amputation by long anterior and short posterior flaps.**—It is assumed that the femur is to be divided about its centre. The two flaps are U-shaped. The anterior flap is equal in length to one diameter and a half of the limb at the saw-line. The posterior flap has the length of one-half the diameter of the extremity at the same level. The anterior flap is the wider, its base exceeding a little<sup>or</sup> half the circumference of the limb (Fig. 57, A).

*Operation.*—1. The limb is rotated outwards on the right side, and inwards on the left. The anterior flap is marked out first. In the right thigh the surgeon commences with the inner limb of the flap, cutting downwards. He then carries the knife across the front of the extremity, and finishes with the outer limb of the flap, the leg being now rotated inwards. In dealing with the left limb the conditions are reversed, and the cut is first made upon the external aspect. The incision includes the integuments only.



In marking out the posterior flap the surgeon's hand is beneath the thigh, and the knife, being entered at the farther limb of the anterior flap, is drawn

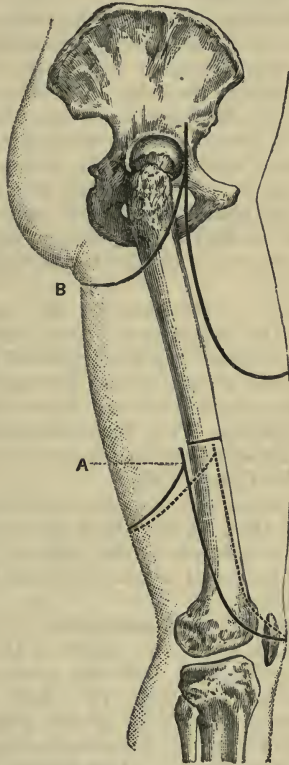


Fig. 57.—A, Amputation of the thigh by long anterior and short posterior flaps ; B, disarticulation at the hip by antero-posterior flaps

across the posterior surface and towards the operator. This cut also involves the integuments only.

The leg is again suitably rotated as the knife passes along its course.

2. The tissues of the anterior flap are now pinched up with the left hand, and the muscles contained therein are divided obliquely from without inwards—*i.e.* from the skin to the bone. The soft parts are so cut that the flap is thinnest at its extremity and thickest at its base. At the latter site it will include the whole thickness of the muscular mass in front of the femur. The tissues are divided obliquely (the edge of the knife being turned towards the bone at the base of the flap) in distinction to the transverse division of parts which obtains in the circular amputation.

The muscles of the posterior flap may be conveniently cut by transfixion. They may, however, be divided in the same way as are those of the anterior flap. Transfixion is better suited for muscular limbs.

The muscles are divided well down to the bone at the bases of the flaps. The femur is bared by further retraction of the soft parts, and is sawn in the manner already described (page 210).

The amputation may be effected by equal antero-posterior flaps (Fig. 56, B). Each flap is about equal in length to the diameter of the limb at the saw-line. They may be fashioned as above described or be both cut by transfixion.

*Hæmorrhage.*—In an amputation by antero-posterior flaps made above the middle of the thigh, the femoral artery, together with the profunda, will be found in the anterior flap. In a like amputation performed below the middle of the limb the main artery will be divided in the posterior flap. In this position, however, there is risk of splitting the artery if the anterior flap much exceed in width one-half of

the circumference of the limb. This is avoided by placing this flap a little towards the external aspect of the limb instead of fashioning it in the median segment. When the amputation is carried out in the middle of the thigh, the anterior flap should be antero-external. This will bring the artery in the posterior flap.

The descending branch of the external circumflex artery will always be found divided in the anterior flap, together with many muscular branches. In the lower third of the limb the *anastomotica magna* will be divided about the inner part of the hinder flap.

In the angle between the flaps, and in the muscular tissue close to the bone, branches of the perforating arteries will be found cut.

It is needless to say that the muscular arteries in the thigh are large and numerous, and that the great veins require to be occluded by ligature.

**4. Amputation by lateral flaps.**—This method is often known as *Vermale's operation*.

The flaps are both of the same size, and include all the soft parts down to the bone. It may be convenient to make the inner flap a little wider than the outer, so as to include as much of the artery as possible in the inner flap.

Each flap should be equal in length to the diameter of the limb at the level of the saw-cut, and should be U-shaped (Fig. 54, B).

Both are cut by transfixion, the knife being entered a little below the point at which the bone is to be divided.

The two flaps having been cut by transfixion should be drawn upwards by an assistant, and an incision made round the bone, fully an inch higher than the place of transfixion. The saw should then be applied in the course of this last cut. In transfixing, the point of the knife should be thrust directly

down to the femur, with which it should be kept in close contact as it is carried round to the opposite surface.

Forcibly elevate the one first made, as the knife is thereby prevented from passing readily across the limb the second time. The surgeon can scarcely, however, be too energetic—after the other is cut—in drawing both upwards, so as to give plenty of room for working the saw without rubbing against the soft parts.

It is well that the inner flap should be made first.

In this operation, when performed in the lower third, the main artery is very apt to be split, even when every precaution is taken.

*Comment.*—Owing to the uneven manner in which the muscles of the part retract, and to the extent of that retraction, a conical stump is not uncommon after any amputation of the thigh.

The modified circular operation (No. 1) and Syme's operation (No. 2) are adapted for the lower third of the limb, especially in cases where a long anterior flap cannot be cut.

The amputation by a long anterior and a short posterior flap (No. 3) is perhaps the best adapted for the thigh and all parts of it. In the lower third of the limb it is certainly an excellent operation. Where the tissues upon the front of the thigh are limited, it may be replaced by the method by two equal antero-posterior flaps (Fig. 56, B), the flaps being cut in the same manner—*i.e.* from without inwards.

Vermale's operation (No. 4) has little to recommend it.

## CHAPTER XIX.

## DISARTICULATION AT THE HIP-JOINT.

**Mode of controlling hæmorrhage during the operation.**

Various methods have been adopted for preventing excessive hæmorrhage during this disarticulation.

1. The femoral artery may be ligatured either before the flaps are cut or during the fashioning of the flaps when the incision crosses the line of the artery, as in the method known as the "anterior racket" (page 222).

The femoral may be compressed in the flap by the fingers of an assistant, who grasps the base of the flap just before the vessels are divided. This method is illustrated in the amputation by transfixion (page 225).

Some surgeons advise digital compression of the femoral or external iliac. This can, however, hardly be carried out except in a child.

2. Lister's aortic tourniquet has been employed. The use of this instrument is now no longer advised by its author.

3. Davy's lever for compressing the common iliac through the rectum has been extensively used in this operation.

4. The elastic tourniquet furnishes an efficient means of controlling bleeding during this operation.

The band may be applied either over the abdominal aorta or around the extreme upper part of the limb.

The following *modes* of performing this amputation will be described :—

1. Disarticulation through an external racket incision.
2. Disarticulation through an anterior racket incision.
3. Disarticulation by antero-posterior flaps (transfixion).

### 1. Disarticulation through an external racket incision.

*Instruments.*—The elastic tourniquet; a stout amputating knife with a blade some six inches in length, and with not too fine a point; a large stout scalpel or resection knife; an amputating saw; lion forceps if the bone is to be divided (*see* Esmarch's operation, page 221); artery forceps; pressure forceps; dissecting forceps; scissors, long needles, etc.

*Position.*—The body is drawn down until the pelvis rests upon the extreme lower edge of the table. The sound limb is secured out of the way. The patient is turned sufficiently over on the sound side to expose the postero-external aspect of the limb to be removed. Some care has to be taken to prevent the patient from slipping entirely off the table. The surgeon stands on the outer side of the thigh—in the case of both the right and the left extremities—and faces the patient.

In the case of the left limb it may be sometimes more convenient to stand on the inner side of the thigh, between the limbs.

*The operation.*—1. The limb being adducted and a little flexed and rotated in, the knife is entered about two inches above the upper edge of the great trochanter, and is carried vertically down the limb along the posterior border of the trochanter for about seven inches. The knife is now drawn across the limb in front and behind in the form of two crescentic incisions, which meet on the inner side of the thigh some little way below the termination of the vertical

incision, and some inches below the genito-crural angle. The whole of this extensive cut should at first involve only the skin and the subcutaneous tissues. At the outer aspect of the limb the incision forms a large inverted Y (Fig. 56, c).

2. The surgeon now turns to the oblique incision encircling the thigh, and separates the skin and subcutaneous tissues all round until these parts have been raised to the extent of about two inches.

3. The thigh being now again adducted, rotated in and a little flexed, the knife is carried well down to the femur along the whole length of the vertical incision.

The muscles attached to the great trochanter must next be divided close to the bone. The anterior, superior, and posterior borders of the trochanter should be cleared in order. The first muscle to be divided is the gluteus medius, attached to the outer surface of the process. The obturator externus tendon is apt to escape division as it dips into the digital fossa. In clearing the process the limb must be kept extremely adducted and well rotated in.

The upper part of the shaft of the femur is now cleared as far as the vertical incision extends. The soft parts must be liberally cut, care being taken that the femoral and profunda arteries are not encroached upon.

In this step the insertions of the gluteus maximus, quadratus femoris, psoas, iliacus, pectineus and upper adductor fibres are divided, together with the superior portions of the triceps femoris. The surgeon is aided by an assistant, who draws the divided soft parts away so as to well expose the bone.

4. The bone has now to be disarticulated. The capsule may be divided transversely at its upper and posterior parts while the limb is in the position of extreme adduction. The anterior part of the capsule can be severed while the thigh is a little flexed.

The limb is now rotated outwards to its utmost, the joint opened, and the round ligament cut.

Everything about the upper end of the femur should now be free and ready for the final sweep of the knife.

Up to this point no vessels of any magnitude have been divided, the chief arteries concerned being the internal circumflex, some branches of the external circumflex and of the sciatic, and a few muscular vessels.

5. Nothing now remains but to cut the muscles upon the inner side of the limb by a vigorous circular sweep of the knife at the level of the already retracted skin. A few touches of the blade, and the limb is removed.

The great vessels are at once secured.

*Hæmorrhage.*—The great vessels are found severed on the anterior face of the wound, close to the divided rectus, sartorius, and adductor longus muscles.

The vessels are placed one behind the other in the following order, from before backwards:—The femoral artery, the femoral vein, the profunda vein, the profunda artery.

The first vessel to be sought for after the main trunks are ligatured is the internal circumflex. It will be found divided in the tissues about the inner and posterior side of the acetabulum. The descending branch of the external circumflex is found cut close to the inner edge of the vastus externus. The transverse branch of that artery will also probably require a ligature.

In the posterior segment of the wound the comes nervi ischiadici is early recognised, and will require ligature.

Bleeding will occur from other branches of the sciatic artery, and from many muscular branches distributed about the surface of the wound.



**Varieties of the operation.**

(a) *Furneaux Jordan's*.—Mr. Jordan gives the following description of his operation:—"A straight incision was made, and the trochanters and upper part of the shaft were freed from their muscular attachments, after which the capsule was opened. Next, the shaft was cleared downwards from all its attachments for a considerable distance, and then a few free sawing movements, with a long-bladed knife, through the thigh, from which the bone had been removed, ended the operation. The integuments were simply drawn upwards, and the soft parts were cut straight through. No bone being left, the muscles quickly retracted, and were easily covered by the skin. Very little blood was lost. . . . The principle of the operation may be thus described:—First enucleate the bone, then cut through the limb at any desired spot—the middle of the thigh, or below, or even near the knee."

(b) *Esmarch's*.—Mr. Barker ("Manual of Surgical Operations," 1887) gives the following account of Esmarch's operation:—

"By a single, strong, muscular sweep of the knife five inches below the tip of the trochanter, all the soft parts of the thigh are divided completely to the bone, and the latter is at once sawn across.

"The vessels are then ligatured.

"The bone is now seized in a lion forceps and steadied, while a second incision is made, commencing two inches above the tip of the trochanter, and carried down along the latter, to terminate in the first circular cut. The two borders of this incision being held apart by an assistant, the bone is cleared of the soft parts by the use of an elevator inserted under the periosteum, and by the knife where the muscle insertions are too firm for the latter. When the capsule is reached it is divided, and the head is dislocated in the usual way."

## 2. Disarticulation through an anterior racket incision.

This method is also known as the anterior oval method.

The same *instruments* are required as are used in the previous operation. In addition to those mentioned, an aneurysm needle and a small scalpel will be needed. Retractors are occasionally employed.

The *position* of the surgeon and of his assistants is the same. The patient is so placed that the pelvis rests upon the extreme end of the table, and the trunk evenly upon the back.

*The operation.*—1. No tourniquet is applied. The incision is commenced at the centre of Poupart's ligament, and is carried downward along the course of the femoral vessels for about three inches. It is then made to curve inwards so as to cross the adductors about four inches below the genito-crural fold. The knife then sweeps over the posterior aspect of the thigh, crosses the outer side of the limb a little way below the base of the great trochanter, and is carried obliquely across the anterior aspect of the thigh to meet the vertical incision about two inches below its point of commencement (Fig. 58).

This incision concerns at first only the skin and the subcutaneous tissue. It cannot be made with one sweep of the knife, and the limb must be so held and so rotated as to make the tissues meet the knife.

2. The common femoral artery is now ligatured in two places close together, and is divided between the ligatures. The femoral vein is secured in the same manner, and then cut across at the same level as the artery.

3. The skin is freed all round the whole length of the incision, and is allowed to retract a little. The integuments, however, are not especially dissected up.

4. The stout scalpel is now taken, and is carried

through the muscles in the outer flap. In this way are divided the sartorius, the rectus, and the tensor vaginae femoris. The retraction of these muscles will expose the external circumflex artery, which is secured between two ligatures and divided.

Carry the knife backwards, rotate the limb in, and divide the insertion of the gluteus maximus. Rotate

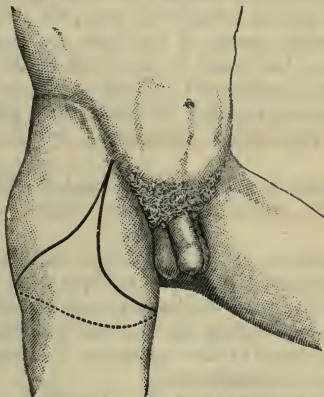


Fig. 58.—Disarticulation at the Hip-joint by an Anterior Racket Incision.

the limb out and divide the psoas muscle. At this point the internal circumflex artery is exposed, secured, and divided. Retractors are of use at this stage of the operation.

5. The muscles in the inner flap are now cut at the level of the retracted skin. These include the pectineus, the gracilis, and the superficial adductors. Any divided vessels are secured.

6. Adduct the thigh, and rotate it inwards so as to expose the great trochanter. Divide the insertions of

the muscles attached to this process, notably the gluteus minimus and medius.

7. Abduct the limb and rotate it out. Incise the capsule transversely. Disarticulate. Divide the round ligament and also the obturator externus tendon, if it has up to the present escaped division.

8. The limb being still more rotated outwards, the head of the femur is dragged forward, and the longer knife being passed behind the bone, all the soft parts at the posterior aspect of the limb are divided with one sweep of the blade at the level of the retracted skin. These tissues will include the hamstrings, the great sciatic nerve, and the undivided parts of the adductors, principally represented by the adductor magnus.

When the wound is approximated, there should be no strain upon the sutures, which are deeply applied.

*Hæmorrhage.*—It is a feature of this operation that the vessels are ligatured as they are exposed, the surgeon dealing with the hæmorrhage according to the method adopted during the removal of a large tumour. In my experience of this operation the loss of blood has been quite insignificant.

### 3. **Disarticulation by antero-posterior flaps (transfixion).**

The great feature of the operation consists in the rapidity with which it can be performed.

No tourniquet of any kind is employed. Even the elastic band would be in the way, and would probably slip during the somewhat vigorous movements to which the limb is subjected. The main vessels are secured in the flap itself by the fingers of an assistant, who compresses them during the actual cutting of the flap.

*Instruments.*—A pointed amputating knife, having a length equal to one and a half times the diameter of

the limb at the level of the hip ; artery forceps ; ten or fifteen pressure forceps ; scissors, needles, etc.

*Position.*—The patient is supine, and the buttocks rest upon the extreme edge of the table. The sound limb is secured out of the way. The surgeon stands to the outer side of the limb in the case of both the right and the left extremities.

1. The limb is a little flexed and a little abducted. The knife is entered midway between the anterior superior iliac spine and the top of the great trochanter, is thrust through the limb parallel with Poupart's ligament, and is brought out at the inner side of the thigh behind the adductor longus, about one inch in front and one inch below the tuber ischii, and some three inches from the anus.

The knife should graze the head of the femur in its passage, and just open the hip capsule. It is passed, therefore, as deeply as possible.

If reasonable care be not taken, the knife may slice the femoral vessels, or may be arrested by the femur, or may enter the thyroid foramen, or may have its point driven into the testicle or the thigh of the opposite side.

The surgeon now cuts, by a sawing movement of the knife, a U-shaped anterior flap some eight inches in length.

This flap will end about the junction of the upper with the middle third of the thigh (Fig. 57, B). It should include as much of the soft parts as possible.

It will be noticed that the knife is placed obliquely at the commencement of the cutting of the flap, and that it becomes transverse at the termination. More tissue has to be divided on the outer than on the inner side of the limb. If the flap be carelessly cut, it is apt to be too pointed at its extremity.

As the knife is carried downwards, the first assistant slips his fingers under the cut surface of

the flap and compresses the main vessels against his thumbs, which are placed upon the skin. It thus happens that before the femoral is divided at the end of the flap the upper part of the trunk is well secured.

As soon as the flap is made this assistant draws it upwards out of the surgeon's way, while he still grasps the great vessels.

2. The limb is straightened and is fully extended, *i.e.* the knee is depressed. The surgeon cuts open the capsule.

The thigh is now rotated outwards. The head slips out of the acetabulum, and the round ligament is divided.

The thigh, still extended, is now rapidly adducted and rotated inwards, and the muscles about the great trochanter are cut.

The disarticulation is complete, and nothing remains but to cut the posterior flap.

3. The whole thigh is now lifted directly up in such a way that the free end of the femur is dragged away from the posterior tissues and is forced forwards.

The surgeon passes his knife behind the femoral head and the great trochanter, and, cutting downwards, forms the posterior flap.

This flap is shorter than the anterior, and the skin is divided about the level of the gluteal fold (Fig. 57, B).

The clearing of the great trochanter is, perhaps, the most difficult part of the operation. If not well done, a pocket is left in the flap at the site of that process.

*Hæmorrhage.*—The sciatic artery and branches of the gluteal in the posterior flap should first be secured; then the internal circumflex, close to the inner side of the acetabulum. The superficial femoral is divided near to the free extremity of the anterior flap. The

profunda is usually found severed about the middle of the cut surface of the flap. In the outer part of the same flap the external circumflex will be found and will require a ligature.

The femoral and profunda veins should be ligatured.

**Comment.**—Of these various operations those by the *racket method* may be considered to be the best.

Of the two methods involved, that which employs the anterior incision appears to me to be the more useful.

In *Furieux Jordan's* operation the muscles may be divided low down, *i.e.* about the middle of the thigh or near the knee.

*Esmarch's* method has the advantage of being rapid, and is moreover easily performed. The vessels are divided and secured at an early stage of the operation.

The operation by *antero-posterior flaps cut by transfexion* has the advantage of great rapidity of execution. Before the days of chloroform, this was an advantage of the prime value.

## Part II.

### OPERATIONS ON THE BONES AND JOINTS.

---

#### CHAPTER I.

##### OSTEOTOMY.

By osteotomy is understood the division of a bone in its continuity for the relief of deformities of various kinds.

*Linear osteotomy* implies the division of the bone in its continuity in a single transverse line, the subcutaneous method being, if possible, carried out.

*Cuneiform osteotomy* is the term applied to the cutting out of a wedge-shaped piece for the relief of such deformity as that represented by the curved tibia met with in rickets.

In both forms the operation may be performed by means of a saw, or a chisel, or an osteotome.

**The instruments employed.**—The following are the instruments required in these operations:—1, An ordinary scalpel; 2, chisels and osteotomes of various sizes; 3, mallet; 4, saws for subcutaneous division of bones; 5, sand-bag; 6, blunt hooks.

The chisel is used for paring, shaving, and cutting out wedges of bone, as in cuneiform osteotomy.

The osteotome is employed for making simple incisions or wedge-shaped openings, but without removal of bone. The chisel, like the ordinary carpenter's chisel, is apt to go awry if a straight section be attempted.



## THE OPERATION.

**1. Linear osteotomy with the osteotome.**

—The limb having been firmly embedded in a sand pillow in a suitable position, a simple incision is made down to the bone. This cut should be of sufficient size to admit the largest osteotome intended to be used. It should be so placed as to avoid structures of importance, should be through the least vascular part of the limb, and should reach the bone by the most direct route.

Before the knife is withdrawn the osteotome may be introduced by its side, the knife acting as a guide.

Some surgeons make the skin wound correspond in direction and position with the intended wound in the bone; others place the surface incision at right angles to the future bone cut (*see* page 240), and turn the osteotome, after that instrument has been introduced. The former method is the better.

The osteotome is driven through the bone with the mallet, cutting in various directions, until the bone is divided. The edge should be directed from any neighbouring great vessels. As the cut in the bone becomes deeper, finer osteotomes may be used.

The osteotome should be grasped firmly in the left hand, steadied by the inner border resting on the patient's limb. The surgeon ought to cut to, instead of from, himself; thus, if the surgeon is operating on the inner side of the left limb, he ought to stand on the left side of the patient, and cut towards himself.

This operation should never be attempted until the surgeon has gained quite an extensive experience by operating upon animals' bones, which should be quite fresh, and be embedded upon a sand-bag, and by performing osteotomies upon the cadaver.

**2. Linear osteotomy with the saw.—**

This operation differs but little from the last, except

in the main element that the saw is used in the place of the chisel.

The same care is taken that the procedure is subcutaneous, and that as little damage as possible is done to the soft parts.

The best situation for dividing the bone having been selected, and the part being firmly held, a narrow-bladed knife is passed through the skin down to the bone. The tissues are so divided that the bone is laid bare along the line which the saw must travel. The knife employed should be shaped like a tenotome, must be long enough to cover the whole distance in the case of a deep-seated bone, and the cutting edge should not extend along the whole length of the blade. While the knife is being manipulated in the depths of the limb, the non-cutting part of the blade should then be in contact with the skin. The knife is employed to make a space for the passage of the saw, and the deep incision should not be so incomplete that the saw has to be forced through the tissues. The skin wound should be as small as possible, and should be made at right angles to the surface to be sawn.

Before the tenotome is quite withdrawn, the saw should be carefully introduced by the side of it, so as to reach the part of the bone which has been incised. When the saw is in position, the knife is withdrawn. A suitable pattern of the Adams' saw is employed.

The saw must be used with short strokes, and care must be taken that its tip is not ruthlessly thrust into the tissues upon the opposite side of the bone.

Especial care should be taken to see that the saw is perfectly clean, and that the composition with which it has been brightened has been brushed out from among the teeth.

**3. Cuneiform osteotomy.**—In this form of the operation a cuneiform or wedge-shaped piece of

bone is removed to remedy an abnormal curve or angular deformity. It has been applied in the treatment of the curved femora and tibiae resulting from rickets, in some cases of bony ankylosis at an unusual angle, and in a few examples of angular deformity produced by mal-union after fracture.

The exact size and shape of the wedge must be

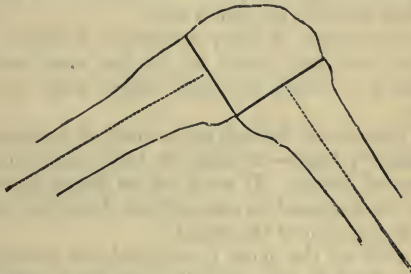

Fig. 59.—Diagram to show the Lines of the Chisel Cuts in Cuneiform Osteotomy for Angular Deformity after Fracture, etc.

carefully determined, and must obviously depend upon the position and extent of the deformity.

In general terms, it may be said that the sides of the wedge should be at right angles to the axis of the bone respectively above and below the seat of the operation (Fig. 59). In actual practice, however, so large a wedge-shaped piece of bone is very seldom removed. If the curvature in the bone be not extreme many surgeons content themselves with a mere linear osteotomy, leaving a gap between the divided ends when the limb has been adjusted, which gap appears to fill up without complication.

In the severer kinds of deformity a wedge may be removed much smaller than is necessary to entirely overcome the deviation, a gap of moderate size being

left when the limb has been brought into its normal position upon a splint.

The wedge, moreover, need not extend through the entire thickness of the bone. It may involve possibly three-fourths of the diameter of the bone, the remaining fourth being bent or broken.

In performing this operation a chisel will be found to be more convenient than a saw.

In some forms of bony ankylosis of joints, however, the saw may prove to be the more suitable instrument, or both saw and chisel may be used together.

The incision in the soft parts must of necessity be comparatively large—as large at least as the base of the intended wedge. It need be no larger, since the skin can be displaced in one or other direction according to the position of the chisel.

As soon as the bone is exposed, the periosteum must be divided and carefully separated with the elevator.

In dividing the bone the chisel should be employed and not the *ostéotome*.

The instrument must be so held that the straight edge is towards the bone to the left, and the bevelled edge towards the portion to be removed.

If a large wedge has to be removed, it should be dealt with in sections. A small wedge-shaped piece should first be taken out, and then thin slices of bone should be shaved from each side of the exposed bone until a cuneiform cavity of the desired size and shape has been produced.

If an attempt be made to remove a large wedge at once, it will be found that the chisel is apt to go awry, to incline towards the straight edge, and in consequence an uncertain division of the bony tissue is made.

It is not well to attempt to prise out the wedge

of bone with the chisel. The bone so treated is apt to split, or the chisel may be broken. The wedge can be removed better with forceps aided by an elevator.

After the bone has been dealt with, the periosteal flaps may be brought together by a few fine catgut sutures. The skin wound should not be too completely closed, but room left for drainage.

## CHAPTER II.

OSTEOTOMY FOR FAULTY ANCHYLOSIS OF THE  
HIP-JOINT.

THIS measure is carried out in certain cases of rigid ankylosis of the hip-joint.

A. **Through the neck of the femur.**

This operation may be performed either with the saw or with the osteotome.

*Operation.* 1. *With the saw (Adams' operation).*—The left thumb is placed so as to compress the soft tissues solidly against the bone, at a point situated at the centre of the top of the great trochanter and the breadth of one finger above it.

At this point a narrow-bladed knife is pushed in till it reaches the neck of the femur, at a right angle across the front of which it is then carried (Fig. 60, A). The operation is completed in the manner already described (page 230).

2. *With the osteotome.*—The patient lies upon the sound hip, and the surgeon stands to the outer side of the limb. An assistant steadies the thigh and pelvis.

A longitudinal incision about three-fourths of an inch in length is made just above the great trochanter, and in the axis of the neck of the bone. The knife is carried well down to the bone. The osteotome follows the knife, and on reaching the femur is turned on its axis, so that its cutting edge is at right angles to the axis of the neck.

A few blows from the mallet will suffice to divide the bone.

B. **Through the shaft of the femur below the trochanters.**

The operation most usually carried out in this situation is that known as Gant's. Either the saw or the osteotome may be employed. The latter should be the instrument selected.

*Operation.*—The osteotomy is carried out precisely as in the procedure just described.

The incision is longitudinal, is placed over the

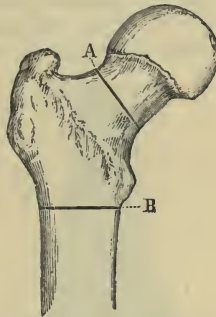


Fig. 60.—Osteotomy for Faulty Anchylosis of the Hip.

A, Intracapsular; B, extracapsular.

outer aspect of the femur and about at the level of the lesser trochanter.

The osteotome is introduced, is turned upon its axis in order to render the operation as completely subcutaneous as possible, and the bone is divided immediately below the lesser trochanter and in a line at right angles to the shaft of the femur (Fig. 60, B).

*Comment.*—In these situations the bone should be divided completely. It should not be partially cut through and then fractured, lest dangerous splinters of bone be produced.

In severe and old-standing cases the mere division

of the bone may possibly not suffice to correct the deformity, and it may be necessary to cut contracted tendons or contracted bands of fascia. The tendons most usually in need of tenotomy are those of the adductor longus, rectus, and sartorius.





## CHAPTER III.

## OSTEOTOMY FOR GENU VALGUM.

**Anatomical points.**—In the severer forms of genu valgum—and it is in these only that osteotomy is practised—there is a great increase in the size and

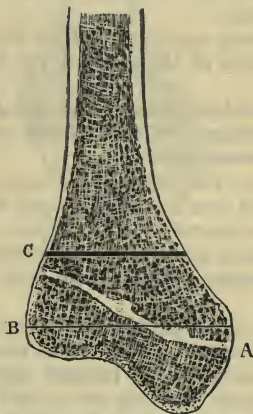


Fig. 61.—Vertical Section of the Lower End of a Deformed Femur, from an Extreme Case of Genu Valgum.

A, Line of epiphysis; B, transverse line drawn at level of adductor tubercle; C, line of Macewen's operation.

depth of the internal condyle. This is due—as has been shown by Mickulicz—to an increase in the diaphysis of the bone rather than in the epiphysis (Fig. 61).

It should be noted that the epiphyseal line is about on a level with the tubercle for the adductor magnus

tendon. The trochlear surface of the femur belongs to the epiphysis.

A transverse section of the femur about the epiphyseal line will show that the outer part of the bone is much more extensive than the inner part, and this disproportion is continued for some little distance upwards in the less expanded part of the bone. The medullary canal ceases some way above the point at which the shaft of the bone widens out to form the condyloid extremity. Indeed, none of these operations concern the canal.

The following *operations* will be described :—

1. Osteotomy of the shaft of the femur from the outer side.

2. Macewen's supracondyloid operation.

**1. Osteotomy of the shaft of the femur from the outer side.**

*Operation.*—The patient lies upon the back, with the knee flexed over a sand-bag, upon which the limb is made to rest securely. The surgeon should stand to the inner side of the limb, *i.e.* between the patient's legs. An assistant standing opposite to him steadies the limb.

The thigh being adducted so as to expose well the outer surface to the operator (as he stands to the inner side of the knee-joint), an incision about one inch in length is carried down to the bone at a point about two inches above the external condyle. The incision is made upon the outer side of the thigh, is transverse—*i.e.* at right angles to the long axis of the femur—and may be made in one cut. The knife passes through the ilio-tibial process of the fascia lata, and runs in front of the biceps muscle.

When the knife is withdrawn, the osteotome is inserted, and the limb—no longer adducted—is firmly planted upon the sand-bag. The osteotome is made to traverse the shaft transversely. As the outer

part of the bone is here thicker than the inner part, it will be found that when two-thirds of the shaft have been divided the bone can usually be readily fractured. It is essential that the division be extensive enough,

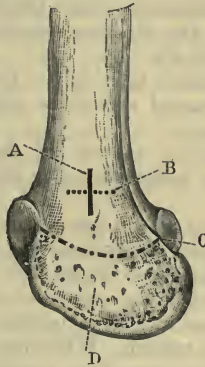


Fig. 62.—Macewen's Operation for Genu Valgum.

A, Skin incision; B, osteotome incision; C, epiphyseal line; D, inner condyle.

and that no premature and violent attempts be made to complete the division of the bone.

## 2. Macewen's supracondyloid operation.

*Operation.*—The patient lies upon the back, close to the edge of the table. Both hip and knee are flexed; the thigh is abducted and rests upon its outer side. The knee is well fixed upon the sand-pillow. The surgeon places himself upon the outer side of the limb.

A sharp-pointed scalpel is introduced on the *inside* of the thigh, at a point where the two following lines meet—one drawn transversely, a finger's-breadth above the superior tip of the *external* condyle, and a longitudinal one drawn half an inch in front of the adductor magnus tendon. The scalpel here penetrates at once to the

bone, and a longitudinal incision (Fig. 62, A) is made, sufficient to admit the largest osteotome. Before withdrawing the scalpel, the osteotome is slipped by its side until it reaches the bone.

The scalpel is withdrawn, and the osteotome, which was introduced longitudinally, is now turned transversely in the direction required for the osseous incision (Fig. 62, B).

The osteotome is then driven through the bone in various pre-arranged directions until the division is nearly complete.

After a certain amount of the bone has been divided, a finer instrument may replace the one first employed.

It is desirable to complete all the work intended by any one osteotome before removing it from the wound.

When the operator thinks that the bone has been sufficiently divided, the osteotome is laid aside and a sponge saturated in 1-40 carbolised watery solution is placed over the wound. While the surgeon holds the sponge, he at the same time employs that hand as a fulcrum; with the other he grasps the limb lower down, using it as a lever, and jerks if the bone be hard, or bends slowly if the bone be soft, in an inward direction, when the bone will snap or bend as the case may be.

Neither sutures nor drainage-tubes are required.

*Comment.*—The highest part of the articular surface of the femur is a good guide to the level of the lowest part of the incision.

Great care must be taken that the line of the bone-incision is appreciated and accurately followed.

For a short distance above the condyles the femur has a much thicker outer than inner border; in many instances the outer is twice as thick as the inner.

If the form of the bone be not borne in mind, the surgeon may think that he has divided it sufficiently, and

yet he may find that it will not yield, owing, in most cases, to the posterior and outer part remaining intact.

In young subjects up to fifteen or sixteen, the division of the internal two-thirds of the bone will usually suffice, the remainder being broken; but in adults, especially when the bone is hard and brittle, the section should be more complete, and as little fracturing should be attempted as is possible.

In children one osteotome will suffice for the division of the bone.

If care be not exercised, it is possible for the femur to be split longitudinally.

The incision employed is above the level of the articular ligaments.

The cut in the soft parts may be made transversely, and be so placed as to correspond to the intended bone incision. By this means the osteotome is more readily introduced and more easily re-inserted should it be accidentally removed during the operation. The transverse incision spares the soft parts from a certain amount of bruising and disturbance, but it does not favour so complete a subcutaneous method.

Although the synovial pouch of the knee-joint reaches as high as the level of the bone incision, it is not in the way of the actual wound itself, since it tapers to the middle line as it ascends. A certain amount of fat intervenes between the synovial pouch and the bone, and the osteotomy cut is posterior to the pouch.

The wound is above the superior internal articular artery, and below and anterior to the anastomotica magna. Bleeding from this vessel has, however, been reported as occurring during the operation.

## CHAPTER IV.

## CUNEIFORM OSTECTOMY FOR INVETERATE CLUB-FOOT.

IN this operation a wedge-shaped piece of bone is removed from the outer side of the foot at the site of the medio-tarsal joint.

The cases selected for this method of treatment are examples of very extreme and intractable club-foot, which have resisted treatment by tenotomy, manipulation and apparatus, which are associated with distinct changes in the shapes of the tarsal bones, and in which it is evident that no step short of the removal of osseous tissue can alter the shape of the foot.

**The size of the wedge.**—The dimensions of the portion of bone removed must, of necessity, depend upon the degree of the deformity. In talipes equino-varus the base of the wedge is at the outer side of the foot, and is mainly represented by the cuboid; the apex will be at the scaphoid bone, the distal side of the wedge will be represented by a line at right angles to the metatarsal bones, and the proximal side by a line at right angles to the long axis of the os calcis.

In some instances the wedge is composed of portions of the astragalus, os calcis, scaphoid, and cuboid—the last-named bone predominating.

In talipes equinus the base of the wedge is on the dorsum of the foot and its apex in the sole. The bones represented in the wedge are portions of the os calcis, astragalus, scaphoid, and cuboid; and, in severe cases, portions of the bones anterior to the two last-named may find their way into the wedge.

In removing a wedge of ordinary dimensions no

important muscular attachments are concerned. Slips from the tibialis posticus will have to be severed, and the origin of the flexor brevis hallucis detached from the cuboid. The latter muscle will probably be represented by atrophied tissue.

**Operation for talipes equino-varus.**—The patient is placed upon the back, with the hip and knee a little flexed, and the sole of the foot resting upon a sand-pillow on the table. The surgeon stands to the outer side of the limb, and an assistant opposite to him grasps the foot and leg, and steadies the extremity or moves it as required. The operation is usually carried out as follows:—

The outer surface of the foot having been well exposed, and the cuboid defined, a horizontal incision is made on the outer border of the foot, in its long axis, and so placed as to extend from the neck of the os calcis to the base of the fifth metatarsal bone.

The foot is now firmly fixed so as to bring the dorsum well into view, and with a Farabeuf's ruginé and elevator the tendons and all the soft parts are raised from the dorsum of the tarsus. The elevator is introduced through the incision, and the surgeon works from without inwards. The instrument must be kept close to the bone, and the area to be represented by the wedge must be laid entirely bare.

A slender metal spatula is now introduced between the bones and the soft parts which have been raised from the dorsum. This instrument is used for the purpose of protecting the soft parts while the bone is being divided.

The wedge is most conveniently cut out by means of a fine chisel. Great care must be exercised as the chisel approaches the tissues of the sole.

The wedge is now seized with lion forceps, and is loosened. As the surgeon drags upon it with the left hand, he clears the plantar surface of the bones to be

removed with a narrow scalpel or with curved scissors. The wedge can usually be lifted out in one piece. Any hæmorrhage having been dealt with, the portions of the foot are brought together; and if the deformity be not fully corrected, a little more bone may be removed with the chisel from one or other side of the wedge-shaped gap.

The wound is closed with sutures, and a drain may be introduced into the lower part of the incision.

It is not necessary that the bones be sutured together.

The limb is treated as if it were the seat of a compound fracture of the foot.

**Operation for talipes equinus.**—The operation in this form of club-foot differs but very slightly from that just described.

The medio-tarsal joint having been defined, a suitable incision is made on the dorsum of the foot over the base of the wedge.

The soft parts are cleared from the dorsum, and the wedge is cut out with the chisel with the same precautions and in the same manner as have been already described.

The wedge may be extracted in one piece in the form of a bony key-stone.



## CHAPTER V.

## EXCISION OF JOINTS AND BONES.

## GENERAL CONSIDERATIONS.

By the term "excision of a joint" is implied the removal of the articular extremities of the bones entering into the formation of the joint, together, necessarily, with the cartilage and synovial membrane, the procedure being carried out with the least possible amount of injury to the surrounding soft parts.

This definition, while it applies precisely to the excisions of the knee and elbow, is allowed also to include the usual excisions of the hip and shoulder in which only the articular extremity of the long bone forming the joint is removed.

The excision of a bone may apply either to the complete removal of a bone together with its articular extremity, *e.g.* the inferior maxilla; or to the removal of a portion of a bone, *e.g.* the diaphysis of the humerus, or the acromial end of the clavicle.

**The instruments employed.**—The following is the list of the instruments that may be required in an excision operation:—

Scalpels. Bistouries (blunt- and sharp-pointed).  
Dissecting and artery forceps. Pressure forceps.

Scissors. Bone forceps. Sequestrum forceps.  
Probes; directors; special directors.

Excision knives.

Ivory or metal spatulæ. Retractors of various kinds.

Lion forceps.

Periosteal elevators. Rugines.

Saws of various kinds.

Chisels and mallet.

Bone gouges. Sharp spoons.

The excision knife should have a large handle and a short but stout blade.

The most convenient rugines are those of Farabeuf.

Retractors play a very important part in excision operations. The most serviceable are of steel and are rectangular.

Good ivory spatulæ are of great service to protect the soft parts during sawing.

Blandin's director is of value in protecting the soft parts when the saw is being applied. It is, indeed, made to act as a director for the saw.

**The general conditions of excision operations.**—In performing excision of a joint, the following general points are to be observed :—

1. The whole of the diseased tissue must be removed.

2. The amount of the bone removed must be limited by such common surgical requirements as are necessary to ensure the prospect of a useful—or, at least, not utterly useless—limb.

3. The soft parts must be as little disturbed as possible:

4. Care must be taken in young subjects that the active epiphysis be not destroyed, lest a greatly shortened limb result.

5. The bones must be so divided as to be adapted to the purposes of the new articulation, or be favourable for ankylosis in a good position.

**The open method and the subperiosteal method.**

The excision of a joint may be carried out by either of the two methods just named.

*The open method.*—In the open method the bones

are exposed through the simplest and most direct incision; the soft parts are disturbed as little as is possible; any tendons which may be attached to the bones to be excised are not cut through, but are peeled off or separated from their point of attachment. The ligaments of the joint, or certain of them, can hardly escape division.

The bones are projected, and are sawn off, but no care is taken to separate and preserve the periosteum which is attached to them.

*The subperiosteal method.*—In the subperiosteal method the articular ends of the bones are exposed, probably through a similar incision to that observed in the open method. The great object of the operator, however, is to save the whole of the periosteum of the involved district, and at the same time to preserve the capsular ligament intact.

The osseous tissue to be removed is shelled out from within this investment of periosteum and ligament. The capsule, and the periosteum into which it extends above and below, are divided in one vertical incision. The gap made is enlarged; the bones are decorticated; they are stripped of periosteum, but at the same time the connections between that membrane and the capsule of the joint are not disturbed.

The subperiosteal operation is excellent in theory, but it is only excellent in practice in selected cases. Although it is the procedure which should be adopted whenever possible, it can never become a routine method of performing excision. It is, indeed, of somewhat limited application. A partial subperiosteal resection may often be carried out in instances where the complete operation is impossible, and there must be few cases in which it is not desirable to take every precaution to preserve the connections of ligaments and the periosteal attachments of tendons.

## CHAPTER VI.

EXCISIONS OF THE FINGERS, THUMB AND  
METACARPUS.

THESE operations are but seldom required, and can but very rarely be carried out upon precise and systematic lines.

Most of the so-called excisions of bones consist of removing large necrosed fragments, such as that formed by the unguis phalanx after whitlow, or as may be produced in the diaphysis of a metacarpal bone.

1. **Terminal phalanges.**—The unguis phalanx may be conveniently excised through a U-shaped palmar incision, which will circumscribe the pulp of the digit. The curved extremity of the U is brought close to the nail. The base of the little bone should be preserved if possible, as it forms the epiphysis and gives attachment to the flexor profundus digitorum.

2. **Interphalangeal joints.**—A single lateral incision is made upon one or other side of the joint in the long axis of the phalanx. If the cut be placed opposite to the centre of the digit—as regards its width from dorsum to palm—the vessels and tendons will be avoided (Fig. 63, B).

The lateral ligament being divided, the bones are made to protrude, are carefully cleared of soft parts, and are then removed with a very fine saw. To safely effect this section a grooved curved director should be introduced to receive the saw.

If two lateral incisions be employed, the operation is rendered much easier.

**3. Metacarpo-phalangeal joints.**—Precisely the same method is employed as in the above case. If a single lateral incision be made use of, it should be placed externally in the case of the thumb and index finger, internally in the case of the little finger, and to one or other side of the dorsal aspect of the

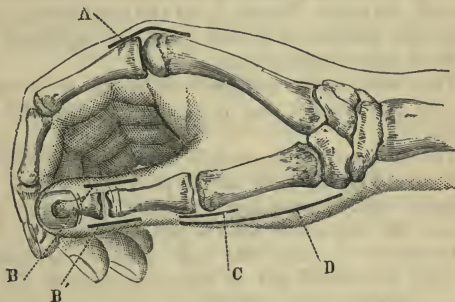


Fig. 63.—A, Excision of metacarpo-phalangeal joint of index; B, excision of interphalangeal joint of thumb; C, excision of metacarpo-phalangeal joint of thumb; D, excision of first metacarpal bone.

joint when the other metacarpo-phalangeal joints are concerned (Fig. 63, A and C).

**4. Metacarpal bone of the thumb.**—In this little operation the subperiosteal method should, whenever practicable, be very precisely carried out.

The hand is held firmly upon a table, with the radial side uppermost.

An incision is made along the outer side of the metacarpal bone, and is so placed as to lie over the lateral border of the bone and to be upon the anterior or palmar side of the extensor tendons. The incision is carried in one direction over the metacarpo-phalangeal joint, and in the other over the trapezium (Fig. 63, D).

In dividing the soft parts, care is taken to avoid

the branch from the radial nerve to the outer side of the thumb.

The bone is exposed, and the separation of the periosteum is commenced at the centre of the shaft. Small rugines are required, the surgeon using at first a straight one and afterwards a curved instrument. The soft parts are cleared up to the head of the bone, where the structures of the joint are separated and the head of the bone is made free.

This end—quite stripped—is made to protrude through the wound, and is seized and held by lion forceps.

The surgeon then proceeds to decorticate the rest of the bone as far back as the proximal joint. The muscular attachments are separated with the periosteum, and the whole bone is removed.

It will be obvious that this subperiosteal method can only be carried out in quite exceptional circumstances, and in young subjects.

Whether the subperiosteal method be pursued or not, the steps of the operation will be the same.

**5. Metacarpal bones of the fingers.**—An incision is so made along the dorsal aspect of the metacarpal bone as to avoid the extensor tendons. The bone is exposed, and the centre of the shaft is well cleared. Around this portion of the bone—when entirely freed—a much-curved director is passed, and the bone is divided by means of cutting forceps. Each divided end can now in turn be seized with lion forceps, be freed of its soft parts, and be removed. The bone is therefore excised in two segments.

## CHAPTER VII.

## EXCISION OF THE WRIST.

THIS operation, when complete, consists in the removal of the whole of the carpus, the lower ends of the radius and ulna, and the articular extremities of the metacarpus.

**1. Ollier's operation (by two dorsal incisions).**

*Operation.*—The patient lies upon the back, and the hand is placed on a small table by the side of the operation table, and is allowed to rest upon a large sand-bag covered with macintosh. The surgeon sits facing the patient. Such adhesions as prevent a moderate degree of movement should be broken down. It is better that an Esmarch's tourniquet should not be used.

(a) The incisions.—Two landmarks are taken, viz. the centre of a line uniting the two styloid processes and the tendon of the extensor indicis, or, in default of it, the base of the second metacarpal bone. The radial incision commences opposite to the centre of the shaft of the second metacarpal bone, and is continued obliquely upwards along the outer side of the extensor indicis tendon to a point corresponding to the centre of a line uniting the two styloid processes. From this point the incision is carried vertically upwards in the line of the long axis of the limb (Fig. 64, A).

In a large hand the whole incision will measure about  $4\frac{1}{2}$  inches—3 inches of the length being below the line of the articulation, and  $1\frac{1}{2}$  inch above it.

Having divided the integuments, the surgeon

brings the extensor indicis into view, but without opening its sheath.

It is drawn gently outwards by means of a hook, and the insertion of the extensor carpi radialis brevis is sought for. The knife is now carried well down to the bones along the whole length of the incision. This cut will commence to the inner side of the tendon last named, and will fall upon the base of the third metacarpal.

The capsule of the joint is opened, the posterior annular ligament is divided, and the upper part of the deep incision falls in the interval between the extensor indicis and the extensor secundi internodii pollicis.

The former tendon is, with the extensor communis, drawn inwards, the latter outwards.

The ulnar incision is now made. It extends from a point one inch and a quarter above the tip of the ulnar styloid process to a point one inch and a quarter above the base of the fifth metacarpal bone. It is placed to the inner side of the extensor carpi ulnaris.

The incision is carried down to the bones, and falls upon the ulna, the cuneiform, and the unciform.

In making these incisions care should be taken not to cut the dorsal branch of the ulnar nerve to the little finger, or the internal division of the dorsal branch of the radial nerve.

(b) The removal of the carpus.—Starting from the incisions already made, the surgeon proceeds to strip the carpal bones of their ligamentous and periosteal coverings. Small rugines of various shapes are used for this purpose. The decortication may be most conveniently commenced on the radial side, and the dorsal aspect of the bones be exposed before the palmar. As each bone is freed, it should be seized with forceps and removed. Diseased bone is removed by means of the gouge. The bones of the ulnar side will be removed through the ulnar incision.



The pisiform bone may usually be left. The unciform process may be cut through and removed subsequently if found diseased. The trapezium should be saved whenever possible.

This is the most tedious part of the operation, especially if the subperiosteal method be strictly adhered to.

(c) The removal of the ends of the radius and ulna.—The hand is now loose. The lower ends of the bones of the fore-arm are bared of periosteum as high up as is necessary. They are made to protrude through the wound, and are divided by means of a fine saw. If very little disease exists, a liberal gouging of the parts may meet the needs of the case.

(d) The removal of the ends of the metacarpal bones.—This may not be necessary. As little of these bones is removed as is possible, and the section will probably extend no farther than the limits of the carpal synovial sacs.

The bones are made to project through the wound, and are severed as required by means of a fine saw.

(e) The wound is united, a drainage-tube is introduced, and the hand is adjusted upon a special splint.

*Comment.*—This operation must be subject to very considerable modification. It may be impossible to carry out the subperiosteal method completely.

By the open method the tendons of the two radial extensors of the carpus, the tendons of both the extensor and the flexor of the ulnar side of the carpus, the flexor carpi radialis tendon, and possibly that of the supinator longus, may be sacrificed. The two first-named tendons are, indeed, cut through.

The steps of the operation may be altered. The radius and ulna may be sawn through first, and, the carpus being exposed in the wound, the bones may be removed one by one as they are reached. By this means

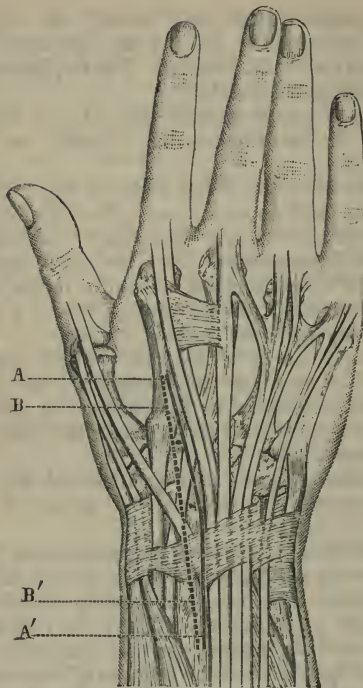


Fig. 4.—Excision of the Wrist.

A A', Ollier's incision for radial side; B B', Boeckel's incision.

the palmar surfaces of the carpal bones can be more easily freed of their periosteoligamentous covering.

## 2. Other methods.

(a) *Boeckel's operation*.—This is sometimes described as *Langenbeck's operation*, the two procedures being practically identical. A single dorsal incision

is made upon the radial side. This incision is straight, is placed in the interval between the extensor indicis and the extensor secundi internodii pollicis, and is made to follow closely the radial border of the first of these tendons (Fig. 64, B). In a large hand the incision is about four and three-quarter inches in length, extending three and a quarter inches below the joint-line, and one inch and a half above it. In a small hand the cut would be about three and a half inches in length, reaching one inch and a quarter above the line of the articulation, and two and a quarter inches below it.

The tendons of the extensors of the radial side of the carpus are cut, the operation is carried out subperiosteally, and in the manner already described.

The incision is not quite so conveniently placed in this operation as it is in Ollier's, and the latter procedure is rendered simpler by the introduction of a small ulnar incision.

(b) *Sir Joseph Lister's operation.*—This may be taken as a good example of the open method of excision, as distinguished from the subperiosteal plan.

The operation is thus described by Mr. Jacobson, his account being a little fuller than that given in the original text. The radial incision is made as in Fig. 65:—"This incision is planned so as to avoid the radial artery, and also the tendons of the extensor secundi internodii and indicis. It commences above, at the middle of the dorsal aspect of the radius, on a level with the styloid process. Thence it is at first directed towards the inner side of the metacarpophalangeal joint of the thumb, running parallel in this course to the extensor secundi internodii; but on reaching the line of the radial border of the second metacarpal bone, it is carried downwards longitudinally for half its length, the radial artery being thus avoided, as it lies a little farther out. The tendon of

the extensor carpi radialis longior is next detached with the knife, guided by the thumb-nail, and raised, together with that of the extensor breviar, which is also cut; while the extensor secundi internodii, with the radial artery, is thrust somewhat outwards. The next step is the separation of the trapezium from the rest of the carpus by cutting forceps applied in a line with the longitudinal part of the incision, great care being taken of the radial artery. The removal of the trapezium is left till the rest of the carpus has been taken away, when it can be dissected out without much difficulty, whereas its intimate relations with the artery and neighbouring parts would cause much trouble at an earlier stage. The soft parts on the ulnar side are next dissected up as far as possible, the hand being bent back to relax the extensors.

“The ulnar incision should be made very free, by entering the knife at least two inches above the end of the ulna immediately anterior to the bone, and carrying it down between the bone and flexor carpi ulnaris, and on in a straight line as far as the middle of the fifth metacarpal bone at its palmar aspect. The dorsal lip of the incision is then raised, and the tendon of the extensor carpi ulnaris cut at its insertion, and its tendon dissected up from its groove in the ulna, care being taken not to isolate it from the integuments, which would endanger its vitality. The finger extensors are then separated from the carpus, and the dorsal and internal lateral ligaments of the wrist-joint divided; but the connections of the tendons with the radius are purposely left undisturbed.

“Attention is now directed to the palmar side of the incision. The anterior surface of the ulna is cleared by cutting towards the bone so as to avoid the artery and nerve, the articulation of the pisiform bone opened, if that has not been already done in making the incision, and the flexor tendons separated

from the carpus, the hand being depressed to relax them. While this is being done, the knife is arrested by the unciform process, which is clipped through at its base with pliers.

“Care is taken to avoid carrying the knife farther down the hand than the bases of the metacarpal bones ;

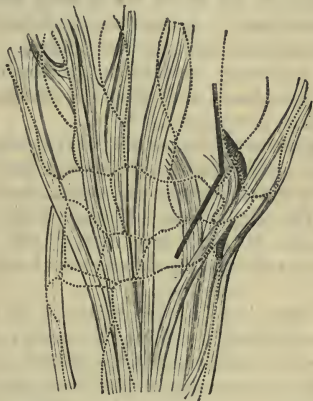

Fig. 65.—Excision of the Wrist. (Lister's incision.)

for this, besides inflicting unnecessary injury, would involve risk of cutting the deep palmar arch. The anterior ligament of the wrist-joint is also divided, after which the junction between the carpus and metacarpus is severed with cutting pliers, and the carpus is extracted from the ulnar incision with sequestrum forceps, and by touching with the knife any ligamentous connections.

“The hand being now forcibly everted, the articular ends of the radius and ulna will protrude at the ulnar incision. If they appear sound, or very superficially affected, the articular surfaces only are removed.

ulna is divided obliquely with a small saw, so as to take away the cartilage-covered rounded part over which the radius sweeps, while the base of the styloid process is retained. The ulna and radius are thus left of the same length, which greatly promotes the symmetry and steadiness of the hand, the angular interval between the bones being soon filled up with fresh ossific deposit. A thin slice is then sawn off the radius parallel with the articular surface. For this it is scarcely necessary to disturb the tendons in their grooves on the back, and thus the extensor secundi internodii may never appear at all.

“The metacarpal bones are next dealt with, each being closely investigated—the second and third being most readily reached from the radial, the fourth and fifth from the ulnar side. If they seem sound, the articular surfaces only are clipped off, the lateral facets being removed by longitudinal application of the pliers.

“The trapezium is next seized with forceps and dissected out, without cutting the tendon of the flexor carpi radialis, which is firmly bound down in the groove on the palmar aspect, the knife being also kept close to the bone to avoid the radial. The thumb being then pushed up by an assistant, the articular end of the metacarpal bone is removed.

“Lastly, the articular surface of the pisiform is clipped off, the rest being left, if sound, as it gives insertion to the flexor carpi ulnaris, and attachment to the anterior annular ligament.”

## CHAPTER VIII.

## EXCISION OF THE ELBOW.

THIS operation consists in the removal of the lower end of the humerus and the upper extremities of the radius and ulna.

**1. Excision through a posterior median incision.**

*Operation.*—The patient lies upon the back, with the body close to the edge of the table. The surgeon stands on the side to be operated upon. The upper arm should be vertical, or at right angles to the surface of the couch, the elbow should be a little flexed, and the fore-arm be carried across the patient's chest, so that the elbow projects prominently outwards. In dealing with the right joint the operator should stand by the patient's loins; and in dealing with the left, well to the outer side of the trunk.

(a) The incision.—The skin incision is about four inches in length, is in the long axis of the fore-arm, and is so placed as to cross the centre of the olecranon fossa of the humerus, and to run along the middle of the olecranon process and then follow the crest or posterior border of the ulna (Fig. 66).

The centre of the incision should correspond to the tip or summit of the olecranon.

The stout short-bladed excision knife may be carried at once down to the bones, cutting on to the olecranon, bisecting the triceps tendon, opening the articulation through the posterior ligament and reaching the back of the humerus.

As the cut will be made from "above downwards," it will be seen that in the position occupied by the

limb the knife will cut first upon the ulna, which is uppermost, and then upon the humerus.

(b) The clearing of the olecranon and the condyles of the humerus.—In clearing the bones for excision, the following rules should be observed:—  
 (1) The surgeon should keep the knife well down

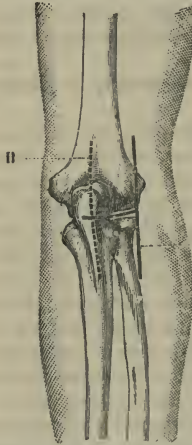


Fig. 66.—Excision of the Elbow.

A, Roux's incision ; B, median vertical incision.

upon the bone, and his incisions should be short and made with force, and the edge of the blade be kept turned toward the bones. (2) The periosteum should be separated to as great an extent as is possible, and all ligamentous connections should be spared. The operator should aim at leaving the bones absolutely bare. (3) The ruginé and the elevator should be freely used, while the knife is employed sparingly. The left thumb-nail must be used with vigour to



retract the tissues as soon as they are separated. Good retractors must also be employed at every step.

The inner part of the wound is first dealt with.

The inner half of the triceps tendon is peeled from the olecranon with as much periosteum as possible. The hollow between the olecranon and the internal condyle is now cleared until that process of bone is reached, and is left bare and projecting.

If the operator keep close to the bones, and observe the three rules just laid down, there is no reasonable danger of wounding the ulnar nerve. The internal lateral ligament is stripped off from both humerus and ulna, and the periosteum is so separated as to carry with it the origin of the flexor muscles.

The surgeon now turns to the outer part of the incision, separating the tissues on that side until the outer condyle is reached and laid bare. In this stage of the operation the outer half of the triceps tendon will be separated and drawn aside without severing its connection with the deep fascia of the fore-arm, the anconeus will be raised from the ulna, the external lateral ligament and the origin of the mass of extensor muscles will be separated from the humerus, and the supinator brevis will be turned well aside. Here, again, strong retractors are of great service. It is during this part of the procedure that damage may be done to the posterior interosseous nerve.

The bones of the joint are now free of one another except upon their anterior aspect.

(c) The sawing-off of the end of the humerus.—The elbow should now be fully flexed, and without much difficulty the lower end of the humerus can be made to project into the wound. The patient's hand should then be placed in the prone position upon the operating-table, close to the patient's head upon the affected side. In this attitude it can be firmly held, the lower ends of the radius and ulna being fixed

rigidly upon the table. The assistant who grasps the upper arm should project the lower end of the humerus upwards. This portion of bone is now cleared of its few attachments in front, and is bared as high up as is necessary.

The surgeon then grasps the bone with lion forceps held in the left hand, and maintained vertically, as if he would draw the bone directly upwards.

A narrow saw with a movable back is applied horizontally to the lower extremity of the bone so fixed, and the excision of the humerus is completed.

The saw-line generally crosses the bone at right angles to its long axis, and just below the tips of the condyles.

In using the saw a metal retractor or spatula should be employed to hold back and retract the soft parts.

(*d*) The sawing-off of the ends of the radius and ulna.—While the limb is in the same position the assistant who is fixing the fore-arm relaxes his hold, and forcing the bones of that part of the limb upwards, makes them in turn protrude prominently in the wound. The ulna is grasped with the lion forceps, which are again held vertically, as if to draw the bone directly upwards; and the metal spatula having been applied, the saw is applied horizontally to the base of the process, a slice of the upper end of the radius being removed at the same time.

The wound is washed out, is adjusted with sutures, and a drainage-tube is inserted.

The method above described may be considered to follow the open method, although as much periosteum and ligamentous tissue is preserved as is possible, and the operation is of wide application.

## 2. The subperiosteal method.

*Operation.* (*a*) The incision.—Precisely the same incision is employed as in the last operation. The

arm is placed by the patient's side, the elbow is extended, and the hand prone. The elbow rests upon a small, hard, round cushion, which is placed upon the table by the side of the patient's body.

The incision is carried well down to the bones, so as to divide the periosteum both of the humerus and olecranon, to open the joint capsule, and bisect the triceps tendon.

In the position the limb now occupies, the external or radial lip of the wound will be superior, and the internal lip inferior or the nearer to the cushion.

(b) Decortication of the postero-external parts.—Commencing with the superior or external part of the wound, the surgeon exposes the depths of the original cut, and draws the soft parts well aside by means of proper retractors.

With a ruginé and elevator he then proceeds to lay bare the outer part of the olecranon, pressing forwards with the ruginé until he has reached the articular surface of the olecranon, and has separated (with the periosteum) the external lateral and annular ligaments and some part of the posterior ligament.

He now turns to the humerus and pares the periosteum from the outer part of the olecranon fossa, and continues the peeling process until he has bared the postero-external part of the humerus and has reached the external condyle. The elbow is now a little flexed, to bring this process better into view, and it is stripped entirely of its periosteum, and of its muscular and ligamentous connections.

With the periosteum the outer part of the posterior ligament will have been elevated and displaced outwards.

(c) Decortication of the postero-internal parts.—The position of the limb is now changed. The hand is carried upwards beyond the head; the arm is thus close to the face, and the hand, which is supine, is

beyond the upper end of the table. The limb is extended, and the cushion again supports the elbow-joint. The wound is now reversed, and the inner lip is uppermost. With the ruginé the operator bares the inner surface of the olecranon, clearing off the rest of the triceps and of the posterior ligament. The separation is carried to the inner margin of the articular surface, and the internal lateral ligament is thus peeled off with the periosteum.

The postero-internal surface of the humerus, including the inner part of the olecranon fossa and the internal condyle, are now laid entirely bare. To clear the condyle the joint must be a little flexed.

(*d*) Division of the humerus.—The joint can now be dislocated, the position of flexion is assumed, and the lower end of the humerus is made to protrude in the wound. The anterior surface of the bone, including the coronoid fossa, is cleared of periosteum, with which is removed also the anterior ligament of the joint.

The extremity of the humerus, being now entirely bare, is seized with lion forceps and sawn through.

(*e*) Division of the radius and ulna.—It only now remains to clear the anterior part of the ulna, including the coronoid process, and the neck of the radius, and to saw the exposed bones off, with the precautions already described.

### 3. Other forms of the operation.

The incision most usually employed when the operation was first introduced was the *H-incision of Moreau* (Fig. 67, B).

Roux omitted the inner vertical limb (Fig. 66, A). In all the early operations the triceps tendon was cut entirely through.

Subsequent experience has condemned every form of transverse incision in this operation.

*Ollier's operation by the bayonet incision.*—The

upper part of this incision is vertical, is opposite the interval between the triceps and the supinator longus, is commenced  $2\frac{1}{4}$  inches above the joint-line, and runs down to the tip of the outer condyle.

It is then directed obliquely downwards and inwards to the base of the olecranon, and is finally made

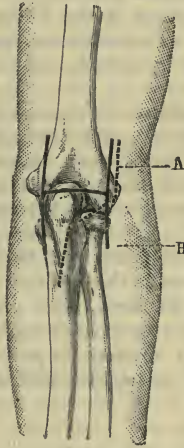


Fig. 67.—Excision of the Elbow.

A, Ollier's incision; B, H-shaped incision of Moreau.

to follow the posterior border of the ulna for  $1\frac{1}{2}$  to 2 inches (Fig. 67, A).

A vertical incision about one inch in length is made over the internal condyle. Through this small lateral incision the point of the condyle is bared and the attachment of the internal ligament separated.

Turning to the main wound, and using the rugine rather than the knife, the operator decorticates the

external condyle, separating the external lateral ligament, exposes the head of the radius, detaches the triceps tendon together with the periosteum, denudes the olecranon and the margins of the sigmoid cavity, and detaches the insertion of the brachialis anticus.

The bones of the fore-arm are now luxated forwards, and are divided with a fine saw.

The inner segment of the humerus is in the next place freed of all its attachments, and, the bone being now bare, the saw is applied, and the required section made.

**After-treatment.**—After the operation the limb must be placed upon a suitable splint, and the bones so adjusted that the greater diameters of the bony surfaces correspond and do not cross. The hand should be in the mid-position between pronation and supination, and the elbow be very slightly bent—so slightly that the fore-arm will be nearer to the extended posture than to the position it occupies when at right angles to the arm. The precise angle recommended by most surgeons is an angle of  $135^{\circ}$ .

Mason's splint answers its purpose well, and also permits the joint to be exercised without the splint being removed.

## CHAPTER IX.

## EXCISION OF THE SHOULDER.

THE operation known by this name consists really of an excision of the upper end of the humerus. The shoulder-joint is not excised—or, in other words, that portion of the scapula which supports the glenoid fossa is not sawn away with the articular segment of the humerus. Portions of bone may be gouged from the glenoid fossa, but more than that is seldom done.

To the greater tuberosity is attached the supraspinatus, infraspinatus, and teres minor; to the lesser process the subscapularis.

**1. The operation by an anterior incision.**

The method here described is the "open method."

*Operation.*—The patient lies upon the back, close to the edge of the table, with the shoulders well raised.

The elbow is flexed, and is carried a little from the side. The assistant who holds the limb sits or stands by the patient's loins. The surgeon takes up a position to the outer side of the shoulder and faces the subject. A second assistant stands behind the shoulder, facing the operator. The bony points about the joint should be defined.

(a) The incision.—The incision, which is three and a half to four inches in length, commences at the outer side of the tip of the coracoid process, and is carried downwards and a little outwards to follow the inclination of the anterior margin of the deltoid muscle (Fig. 68, A).

The knife is carried straight down to the joint, the coraco-acromial arch is exposed, and the capsule

of the joint laid bare in the line of the incision. The biceps tendon is next sought for, and the capsular ligament is opened vertically just to the outer side of the tendon. It is most conveniently incised from below upwards.

(b) The separation of the outer margin of the wound.—The operator now proceeds to clear the tissues from the bone upon the outer side of the wound.

The parts are well retracted with the left thumb, aided when required by retractors. The surgeon uses a blunt-pointed knife, and separates the soft parts from the upper end of the humerus by cutting on to the bone.

The instrument should be kept as close to the bone as possible. As the separation proceeds, the assistant rotates the humerus inwards, while at the same time he depresses the elbow, and forces the head of the bone forwards.

The surgeon clears the capsule from the outer part of the bone, and on reaching the external tuberosity severs the insertions of the supraspinatus, infraspinatus, and small teres muscles.

(c) The separation of the inner margin of the wound.—The limb is restored to the position it originally occupied, and the surgeon proceeds to clear the bone upon its inner aspect in the manner just described. The humerus is rotated outwards as he proceeds; and when the lesser tuberosity is reached, the subscapularis insertion is divided and the attachment of the capsule beyond it.

In this stage care must be taken of the biceps tendon, which should be drawn aside.

(d) The clearing of the neck of the bone.—The biceps tendon is displaced inwards. The elbow is flexed, and the arm is held vertically (*i.e.* at right angles to the table), and is thrust upwards so that the



head of the bone is made to project through the wound. The posterior part of the neck of the bone is cleared and the parts are prepared for the passage of the saw.

(e) The excision of the head of the humerus.—The head of the bone is seized with lion forceps held

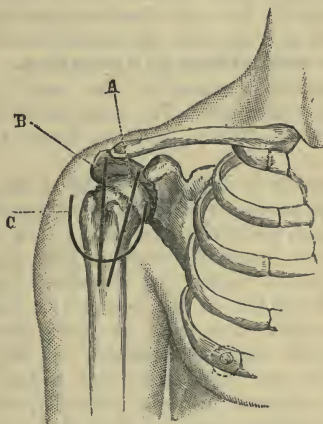


Fig. 68.—Excision of the Shoulder.

A, Anterior incision; B, vertical incision of Langenbeck; C, deltoid flap.

in the surgeon's left hand, and the bone is sawn through with either a small Butcher's saw or a thin saw with a movable back. The saw-cut should incline from without very slightly downwards and inwards, so that no sharp end may be left which might press upon the axillary vessels or nerves.

(f) The glenoid cavity is examined, the skin incision is closed with sutures, and the limb placed in position.

*Comment.*—This procedure can claim to be the best and the most generally adopted method of excising the shoulder.

Langenbeck's incision is placed more to the outer side, and has for its starting-point the acromio-clavicular joint (Fig. 68, B). No especial advantage appears to have been claimed for a skin wound so placed, while it has the disadvantage of inflicting more serious damage upon the deltoid muscle.

## 2. **The subperiosteal operation.**

The patient is placed in the same position as in the last operation. The same incision is made. The capsule is exposed, and the biceps tendon discovered.

The capsule is incised vertically to the outer side of the biceps tendon, and the incision is carried downwards through the periosteum on the neck of the bone as far as the intended saw-cut. The knife is now laid aside for the rugine and elevator. Commencing at the outer segment of the wound, the surgeon separates all the soft parts from the bone, detaching the periosteum, the capsular ligament, and the muscular insertions in one continuous and unbroken layer. The arm is rotated inwards gradually, and is at the same time abducted, and the head of the bone pushed upwards and forwards. The greater tuberosity is reached and cleared, and the bone freed as far as possible beyond it.

The next step consists of clearing the lesser tuberosity, and the inner part of the neck of the bone. Like measures are adopted.

The head of the bone is now thrust out of the wound, and the neck is cleared of any remaining ligamentous or periosteal attachments.

The excision of the head is carried out in the manner already described.

The *deltoid flap* which was once so much made

use of is shown in Fig. 68, c. This form of operation has the advantages of being easy of performance and of well exposing the parts of the joint. It has the overwhelming disadvantage of destroying the function of the deltoid muscle.

## CHAPTER X.

## EXCISION OF THE CLAVICLE AND SCAPULA.

**The clavicle.**—The subclavian vessels lie between the collar-bone and the first rib. Between these structures and the bone is interposed the subclavius muscle and the dense fascia that surrounds it. This muscle is of great service in the operation, and affords a substantial protection to the parts beneath.

Behind the clavicle the following structures may be noted:—The innominate, subclavian, and external jugular veins; the subclavian, suprascapular, and internal mammary arteries; the cords of the brachial plexus; the phrenic nerve and nerve of Bell; the thoracic duct; the omo-hyoid, scalene, sterno-hyoid and sterno-thyroid muscles; the pleura and the apex of the lung.

*Operation.*—The patient is placed in the position advised in ligaturing the third part of the subclavian artery, and the surgeon stands upon the affected side. The excision-knife should be small and blunt-pointed.

An incision is made along the whole length of the bone—when entire excision is intended—and extends beyond it over the sterno-clavicular and acromio-clavicular joints.

The bone is carefully cleared of all its soft parts upon the superior and anterior aspects.

If the case be suited for the subperiosteal method, the rugine may be employed to lay the bone bare.

A way should be made immediately behind the bone at the junction of the outer with the middle thirds, and at this point a chain-saw should be passed around the clavicle with the usual precautions.

When the bone has been divided, the inner end of the acromial segment is seized with lion forceps, and is drawn forwards with the left hand, while with the right the surgeon clears it upon its inferior and posterior aspects. When the acromial part has been removed, the sternal segment is seized and dealt with in like manner. It is the removal of this portion of the bone that involves the chief element of risk in the operation.

Throughout the whole of the excision the greatest care must be taken to keep the knife close to the bone, to cut always on the bone, to be equally cautious with the rugine, and to use spatulæ and retractors, so as to protect the soft parts in the event of the instrument slipping.

After the excision the wound is closed with sutures, and the limb is adjusted as in the treatment of fracture of the clavicle.

**The scapula.** *Operation.*—The patient lies close to the edge of the table, and upon the sound side. The back of the scapula is well exposed. The following incisions are made:—One follows the vertebral border of the bone from the superior to the inferior angle; it is to the outer side of the border, and is parallel with it. A second incision commences over the acromio-clavicular joint, and is carried along the acromion and spine to meet the first incision at a right angle.

Two flaps are thus formed—an upper and a lower one. The operation is carried out in the following steps:—

1. The upper flap is first turned up, and the trapezius muscle is divided along its line of attachment to the bone.

2. The lower flap is turned down, and the deltoid muscle is in like manner divided at its insertion.

3. The patient's hand is drawn as far as possible

over the shoulder of the sound side, to bring into prominence the vertebral border.

All the muscles attached to this border are severed close to the bone. The posterior scapular artery is ligatured.

The free edge of the scapula is dragged towards the operator, and the serratus magnus is cut through.

4. While the limb is still in the same position the superior border of the bone is cleared and the supra-scapular artery is ligatured.

5. The patient's hand is now dragged down towards the hip. The acromio-clavicular joint is opened. Any remaining attachments of the deltoid and trapezius are divided. The conoid and trapezoid ligaments are cut from behind, close to the clavicle.

The limb is so manipulated that the coracoid process is turned towards the operator. The muscles attached to it (biceps, coraco-brachialis, pectoralis minor) and the remaining ligamentous fibres are divided.

6. The capsule is divided with the muscles around it, viz. the supraspinatus, infraspinatus, and sub-scapularis. The scapular heads of the biceps and triceps are cut. The bone is now only connected by means of its axillary border.

7. The muscles of the axillary border—the teres major and minor—are divided near to the scapula.

The subscapular artery is sought for and ligatured.

The scapula is at this last stage in such a position that the muscles may be cut from before backwards, and the trunk of the subscapular artery may be exposed before it gives off the dorsalis scapulæ.

## CHAPTER XI.

## EXCISIONS OF THE TOES, METATARSUS, AND TARSUS.

THE general as well as the detailed observations that apply to the fingers and metacarpus apply also to the corresponding parts of the foot.

The operations upon the various bones and joints

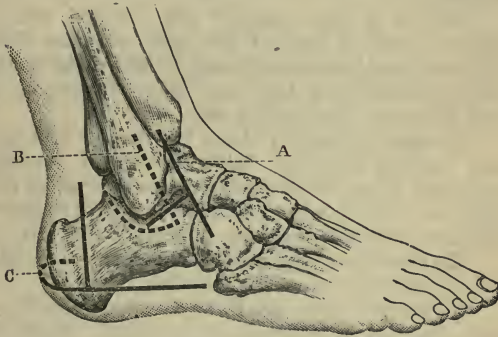


Fig. 69.—A, Excision of astragalus (outer incision); B, excision of ankle (outer incision); C, excision of os calcis.

are carried out in the foot upon similar lines to those already described in connection with the hand.

### 1. The astragalus.

*Operation.*—The patient lies upon the back, and the foot is so placed as to extend beyond the end of the table. It must be held by an assistant, who can manipulate it as directed.

Two incisions, external and internal, are made. The outer incision is about two and a half inches in

length, runs parallel with and just posterior to the tendon of the peroneus tertius, and commences a line or so above the level of the articular margin of the tibia (Fig. 69, A).

A second and much shorter cut starts from the centre of the principal incision, is placed at right angles to it, and ends immediately below the tip of the outer malleolus. The two slight flaps thus defined are turned aside, and the bone exposed in the interval between the peroneus tertius and peroneus brevis tendons.

The foot is well extended and inverted, and the ligaments which connect the bone with the fibula, tibia, scaphoid, and os calcis are divided so far as they can be reached from the outer side. Retractors are used to protect the tendons, etc.

The inner incision is about two inches in length, and, starting from just below the tip of the inner malleolus, is carried forwards and upwards just in front of the anterior margin of that bone. It will be curved, therefore, with the concavity backwards (Fig. 70, A).

The remaining ligaments that hold the astragalus are now divided from the inner side.

The surgeon turns finally to the outer wound, and, while the foot is inverted and extended, grasps the astragalus with lion forceps in a vertical direction, and, as Farabeuf expresses it, "whips it out like a molar."

The wound will need to be drained, and the limb to be firmly secured upon a splint or in plaster of Paris, with the foot at right angles to the leg.

## 2. **The os calcis.**

*Operation.*—The patient lies upon the sound side, the leg is supported upon a sand pillow, and the foot, turned well upon its inner border, is free.

The incision, commencing at the base of the fifth metatarsal bone, is carried horizontally backwards



just above the margin of the sole, and, passing round the hinder aspect of the heel, ends about one inch and a quarter to the inner side of the median line (Fig. 69, c).

This cut is met by a vertical incision two inches in length, which is parallel to and a little in front of the tendo Achillis. The wound is deepened, and two small flaps are formed. Great care must be taken of the peronei tendons, to which the vertical incision is posterior. The bone is exposed behind the peronei tendons, and the periosteum is incised vertically. With a ruginé the periosteum and the associated ligaments are separated from the bone. The outer surface is cleared first, then the posterior surface. The attachment of the tendo Achillis is severed. The foot being placed in the position of talipes varus, the posterior aspect is bared of periosteum as far as it is possible to reach. The anterior portion of the bone is cleared, and the ligaments separated with the periosteum. The same is done with the plantar surface. A certain part of the inner surface can be reached from the posterior aspect.

With care and patience and the use of good retractors the greater part of the bone can be bared through this outer incision, and from this side also the interosseous ligament can be reached and divided.

When the os calcis is as far freed as possible, the head or anterior part must be grasped with lion forceps, and the bone dragged outwards with a repeated rotatory movement, the periosteum and ligaments upon the inner surface being separated with the ruginé as soon as each part of the as-yet-untouched district is reached.

## CHAPTER XII.

## EXCISION OF THE ANKLE.

**Operation.**—The various methods in vogue for performing this operation are for the most part modifications of the original procedure of Moreau. Of the modern forms of Moreau's operation, that by Langenbeck would appear to be one of the best. It may be carried out as follows, if the subperiosteal method be attempted :—

The patient lies upon the back, with the foot and leg supported upon a firm sand pillow. Two vertical lateral incisions are made.

1. *The outer incision.*—The foot being turned over upon its inner side, a vertical incision some three inches in length is made along the anterior part of the fibula to a point a little below the tip of the malleolus. Thence it is made to curve around the malleolus, and ascend for about one inch along its posterior border (Fig. 69, B).

2. *The removal of the fibula.*—The fibula is exposed, and its periosteum divided in the long axis of the bone. The membrane is then separated from the bone by the rugine in an anterior and a posterior direction.

The ligaments attached to the malleolus are separated as encountered. The external lateral ligament is divided vertically, so that its anterior segment will go with the anterior layer of separated periosteum, and its hinder segment with the posterior layer.

With the curved rugine the greater part of the circumference of the shaft of the bone can be bared about the saw-line.

The fibula is then divided with either a chisel or a saw about one inch above its extremity. The divided end is seized with lion forceps, or is drawn outwards with a hook, while its deeper connections are separated with the rugine, aided by the knife.

3. *The clearing of the tibia.*—As much of the anterior and posterior surfaces of the tibia as can be

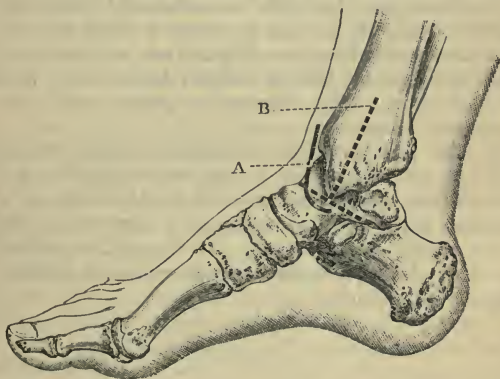


Fig. 70.—A, Excision of astragalus (inner incision) ; B, excision of ankle (inner incision).

reached through the outer cut is bared of periosteum by means of the rugine, the anterior and posterior ligaments of the ankle being elevated with the periosteal layers.

4. *The inner incision.*—The foot is turned upon its outer side, and an incision about three inches long is made along the inner surface of the tibia, and in the long axis of the bone. The cut ends at the tip of the inner malleolus. A curved or transverse incision (Fig. 70, B) may be made to meet the lower end of this wound at right angles.

5. *The removal of the tibia.*—The periosteum of the tibia is incised vertically, and that membrane is peeled from the bone so that it may be continuous with the periosteocapsular layers already separated upon the outer side. The internal lateral ligament is divided vertically in the manner already described with regard to the outer ligament.

As soon as the tibia is sufficiently free, the malleolar end of it is made to project a little through the wound, and while the soft parts are well protected with retractors, the bone is divided horizontally with a keyhole saw. The fragment is grasped with lion forceps and removed.

6. *The sawing of the astragalus.*—The surgeon finally turns once more to the outer incision, and through that wound removes with the saw as much of the upper part of the astragalus as is necessary. The section should be horizontal. If thought necessary, the whole of the astragalus may be removed through the external incision.

## CHAPTER XIII.

## EXCISION OF THE KNEE.

THE upper limit of the femoral epiphysis will be represented by a horizontal line drawn across the bone at the level of the tubercle for the adductor magnus. If the whole of the trochlear surface be removed in the excision, the whole of the epiphysis will have been taken away. The epiphyseal line is intracapsular.

The limits of the tibial epiphysis are represented behind and at the sides by a horizontal line that just marks off the tuberosities.

It includes, therefore, the depression for the insertion of the semi-membranosus, and also the facet for the fibula.

In front the epiphyseal line slopes downwards on either side to a point on the upper end of the shin, so as to enclose the whole of the tubercle of the tibia.

The epiphyseal line is extra-articular. Farabeuf estimates that in a child of about eight years of age it is impossible to remove more than 1 c.m. of the tibia, or  $1\frac{1}{2}$  c.m. ( $\frac{7}{12}$  of an inch) of the femur, without approaching dangerously to the epiphyseal lines.

After puberty (*e.g.* in a youth of seventeen years) it is possible to remove  $1\frac{1}{2}$  c.m. of the tibia, and  $2\frac{1}{2}$  c.m. (1 inch) of the femur, without compromising the epiphyseal lines.

**Operation by a curved transverse anterior incision.**—Of the many methods that have been described and adopted, this appears to have substantial claims to be regarded as the most suitable.

*Position.*—The patient lies upon the back, with the limb close to the margin of the table. The lower part of the leg should project a little beyond the table,

so that when the knee is bent at a right angle the foot may be able to rest, flat upon the sole, upon the end of the table.

The surgeon stands upon the side to be operated on.

At the commencement of the operation the limb is held with the knee a little flexed. Later, the joint is bent at a right angle.

1. *The skin incision.*—A curved incision, convex downwards, is made across the front of the knee below the patella.

The incision commences and terminates at the posterior margin of one of the femoral condyles, while its lowest point in front corresponds with the insertion of the patellar ligament.

During the making of this wound the knee-joint is held a little flexed, and the skin and subcutaneous tissues are alone divided at the first sweep of the knife.

2. *The dividing of the ligaments.*—The knee is now flexed a little more, and with another sweep of the knife the anterior part of the capsule and the patellar ligament are cut through, and the joint opened below the knee-cap.

The patella, with its attached aponeurosis, is turned upwards, the joint is still more flexed, and the surgeon proceeds to divide in order the lateral and the two crucial ligaments.

3. *The sawing of the femur.*—The joint is now bent at a right angle, and the limb held firmly in that position, with the sole of the foot planted upon the table.

The femur is cleared with the knife at the future saw-line.

The bone is sawn from before backwards, and with regard to the plane of the section these two points must be observed:—

The plane of the saw-cut in the antero-posterior

direction must be at right angles to the long axis of the shaft of the femur, and in the transverse direction it must be parallel with the plane of the free surface of the condyles.

During the sawing process the condyles may be grasped and steadied with lion forceps, although, if the limb be firmly held, this is not necessary. The femur rests upon the tibia. The tissues of the ham must be protected by means of an ivory spatula held behind the femoral condyles.

4. *The sawing of the tibia.*—The upper end of the tibia is now held forwards, the foot is still pressed firmly against the table, the shaft of the bone is maintained in the vertical position, and in consequence the articular surface will be quite horizontal. The bone is cleared with the knife for the passage of the saw, and a thin slice is removed by sawing from before backwards, the saw being kept precisely parallel to the articular surface, and therefore at right angles to the shaft. The popliteal tissues must be protected in the manner already described; and if the movements of the saw be slow and deliberate, there is no danger of wounding the structures of the ham.

The two bony surfaces should now be parallel, and should fit accurately when brought together.

5. *The treatment of the patella and synovial membrane.*—The most tedious part of the operation remains. The patella must be dealt with according to the practice of the individual surgeon. It may be removed, whether healthy or diseased, by dissecting it out, with the least possible disturbance of the surrounding tissues; or if entirely sound, it may be left. Or it may be steadied in a vertical position while its articular segment is removed with the saw in the form of a thin layer; or its tissue may be so scraped and cut away that nothing remains but the anterior layer of compact bone.

With the knife and scissors, aided by the sharp spoon, the surgeon now proceeds to remove all the diseased synovial membrane which may remain. The pouch beneath the quadriceps tendon is opened up, and is carefully cleared out by means of the sharp spoon.

Any existing sinuses are opened up and scraped, and by one means or another a careful and determined attempt is made to rid the operation area of every trace of diseased tissue. The part is now well washed with a carbolic solution—1 in 40—and carefully dried.

Nothing remains but to close the wound with sutures—silkworm gut being the best for the purpose—and to adjust the limb upon the splint which has been prepared for it.

A drainage-tube is introduced into the posterior angle of the wound on each side; or a single tube may be passed behind the bones, and be made to traverse the depths of the wound from one side to the other.

The sutures should not be introduced until after the limb has been fixed upon the splint, so that up to the last moment the surgeon may be able to satisfy himself that the bones are in proper position.

No blood-vessels of any importance are divided. The arteries actually severed will be branches of the articular arteries, of the *anastomotica magna*, and of the anterior tibial recurrent. Continued pressure with a dry sponge will be sufficient to check such bleeding as is usually met with.

**Comment.**—Neither a tourniquet nor Esmarch's elastic band is required in this operation.

In the majority of instances it is possible to leave the posterior ligament undisturbed, in which case a substantial barrier remains that will prevent the spread of suppuration into the popliteal space should pus be produced.



In any case, care should be taken to spare this ligament, and to separate its attachments from the bones rather than to cut it.

The internal limit of the incision should not be carried backwards beyond the point indicated, in case the internal saphenous vein and nerve be wounded.

The utmost care must be taken to respect the epiphysis in young subjects. If damaged, it will lead to a shortened, deformed, and possibly useless limb.

The femur and tibia should be sawn from before backwards.

With regard to the fixing of the bones with metallic sutures or pegs, it must be observed that such a measure effects its object but feebly, that primary healing is apt to be hindered, that the subsequent removal of the wires or pegs may be difficult, and that the presence of these foreign bodies may excite some carious mischief in the bones.

## CHAPTER XIV.

## EXCISION OF THE HIP.

THIS operation usually implies the removal merely of the upper end of the femur, and the scraping away of any diseased tissue which may occupy the acetabulum. As in the case of the shoulder-joint, so here also the excision does not involve the whole joint and the entire articulating surfaces.

## THE OPERATION.

Excision of the hip has been carried out through many incisions and in many ways. The following methods represent those most usually employed at the present day :—

1. By an external incision (Langenbeck's operation).
2. By an anterior incision (Barker's operation).

**1. By an external incision (Langenbeck's operation).**

The patient lies upon the sound side, with the thigh flexed at an angle of 45 degrees, and rotated a little inwards.

The surgeon stands to the outer side of the limb.

(1) *The incision.*—A straight incision, about four or four and a half inches in length, is made in the long axis of the limb, and over the outer surface of the great trochanter. It falls a little behind the middle of that process. Two-thirds of the incision will lie over the ilium, and one-third over the great trochanter and femur.

The upper extremity of the wound will be about

opposite to the superior margin of the great sciatic notch (Fig. 71).

(2) *The opening of the joint.*—The knife is carried directly down to the bone and the capsule of the hip-joint.

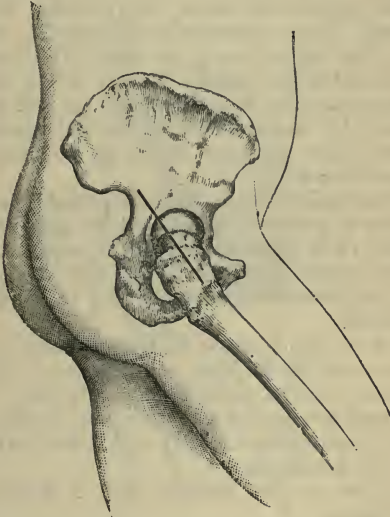


Fig. 71.—Excision of the hip : Langenbeck's external incision.

The capsule is opened in the line of the skin incision. It is also divided transversely, close to the acetabulum, so that the section of the ligament is T-shaped.

By cutting the cotyloid ligament air is admitted into the joint, and the femur becomes separated from the acetabulum.

The muscles attached to the great trochanter are now divided close to their insertion into that bone. The limb is rotated inwards, in order to expose the connections of the posterior muscles, and rotated outwards to reach and divide the anterior muscles.

The ligamentum teres will probably have disappeared; if not, it must now be severed.

(3) *The application of the saw.*—The head of the bone is dislocated backwards, and thrust as far as convenient into the wound. While the soft parts are protected by means of retractors and spatulæ, the surgeon divides the upper end of the femur by means of a narrow saw.

Such arterial twigs as bleed can probably be secured by means of pressure forceps, and the application of a ligature to any vessel will seldom be required.

The surgeon finally removes, with the gouge or chisel, any diseased bone which may be found in the acetabulum.

With the sharp spoon he then proceeds to scrape out the cavity of the joint, and to remove any traces of diseased synovial tissue which may be left. Sinuses are scraped and opened up. The joint is well washed out with a carbolic solution (1 in 40), and is then well dried with the sponge.

The sutures are inserted, and a drainage-tube is introduced.

## 2. **By an anterior incision (Barker's operation).**

The patient lies supine, with both thighs fully extended. The surgeon stands in every case on the right side of the patient.

The incision commences on the front of the thigh, half an inch below the anterior superior spinous process of the ilium, and runs downwards and a little inwards for three inches (Fig. 72). As the knife sinks into the limb it passes between the tensor vaginæ femoris

and glutei muscles on the outside, and the sartorius and rectus on the inside, until it reaches the neck of the femur. When the joint is reached, its contents are thoroughly flushed out with sterilised hot water,

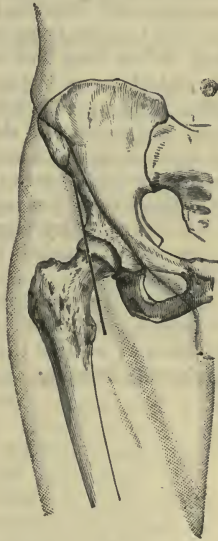


Fig. 72.—Excision of the Hip : Anterior Incision.

at a temperature of between  $105^{\circ}$  and  $110^{\circ}$ , from a suitable irrigator. The neck of the femur is now sawn across with a narrow saw in the direction of the external wound. The diseased head can then be lifted out by means of a sequestrum forceps. Wherever diseased material is felt, it is cut away by Barker's flushing-gouge or scoop, the hot water carrying away the *débris* as fast as it is produced, and with it all

blood, while at the same time it arrests bleeding from the fresh-cut surfaces. When every part of the field of operation has been gouged and scraped clean of all tubercular material, and the water runs away clear, the cavity is dried out with carbolised sponges, one or two of which are left in it until all the stitches are placed in position. Just before they are tied, the sponges are removed, and with them the last traces of moisture. The wound is then filled up with iodoform emulsion, and the sutures are tied, as much of the emulsion being squeezed out at the last moment as will come away. A little iodoform is now dusted over the surface of the incision—in which there is no drainage-tube—and the whole joint is covered with a dry dressing.

After the operation the patient is at once placed upon a double Thomas's splint.

*Comment.*—Of these two procedures, the latter is undoubtedly the better. Out of the first seven cases reported by Mr. Barker, no less than six healed by first intention under one dressing.

## CHAPTER XV.

## ARTHRECTOMY OR ERASION OF A JOINT.

THIS operation, although it is distinct from excision, may most conveniently be considered here.

It consists in fully exposing the interior of a joint, and in removing the whole of the diseased synovial membrane and ligamentous tissue, together with such patches of cartilage or bone as may be the seat of quite limited disease.

This removal is accomplished by means of the scalpel, the scissors, the sharp spoon, the gouge, and, if need be, the actual cautery. The measure aims at removing *all* the diseased tissue, and diseased tissue *only*.

**Instruments required.**—Excision knife ; scalpels ; scissors, both straight and curved on the flat ; sharp spoons of various sizes and shapes ; gouges ; toothed forceps ; dissecting and artery forceps ; pressure forceps ; probe ; retractors.

**The operation** (*as applied to the knee-joint*).—An Esmarch's band is not required, nor is any form of tourniquet needed.

The patient lies upon the back, with the knee a little flexed, and the sole of the foot resting flat upon the table.

The surgeon stands to the outer side of the limb, or he may find it convenient to place himself upon the right side in the case of either limb.

A curved transverse incision is made across the front of the knee-joint, as in performing excision (page 282). The incision may be commenced at the posterior part of one condyle of the femur, be carried across the

front of the limb over the middle of the patellar ligament, and end at the posterior part of the other condyle.

The patellar ligament is divided, the joint fully opened, and the skin flap with the patella turned up upon the thigh.

The knee is now flexed at a right angle, and the interior of the joint well exposed.

The surgeon then proceeds to remove all the diseased synovial membrane, and such of the extra-synovial tissue as is also involved. The latter would include all softened ligamentous tissue. As much as possible should be removed in a continuous layer by means of the scalpel and forceps, or the scissors and forceps. The semilunar cartilages are removed, and probably both lateral ligaments.

The crucial ligaments should be spared whenever possible. They must be stripped, however, of every trace of diseased membrane, must be most carefully inspected, and subjected to a vigorous scraping over all suspicious parts.

The articular surface of the posterior ligament must be exposed, and also freed of all degenerate and pulpy tissue.

This ligament should not be divided, nor should any opening, if possible, be made into the popliteal space.

When the interarticular district has been completed, and the work of the scalpel or scissors followed up by the sharp spoon, until no trace of disease has been left behind, the surgeon turns to the anterior flap.

All the synovial membrane which covers this flap should be dissected off, the subcrural bursa must be fully opened up, and its lining membrane treated in the same way. Every nook and cranny must be patiently explored, and every fragment of tubercular tissue removed.



Finally, the cartilages and bones must be well examined. Patches of softened or eroded cartilage may be sliced off, and points of caries in the bones freely removed with the gouge.

The bleeding is arrested by the pressure of a sponge, which is maintained as long as possible, and by means of pressure forceps. Ligatures are but seldom required.

The articulation is then well washed out with some antiseptic solution (*e.g.* carbolic solution, 1 in 40), well sponged, and dried.

The limb is placed upon the splint prepared for it, and the patellar ligament having been united by many points of chromicised catgut the wound is closed with silkworm gut.

**The operation** (*as applied to the ankle*).—Two vertical incisions are made in front of the ankle, each commencing about 4 c.m. above the line of the joint, and carried down in front of the corresponding malleolus to the level of the medio-tarsal joint. Through these incisions the anterior part of the ankle-joint is dealt with.

Two posterior vertical incisions are then made, one on each side of the tendo Achillis, and through these the hinder part of the articulation is treated.

## CHAPTER XVI.

## EXCISION OF THE MAXILLÆ.

## 1. EXCISION OF THE UPPER JAW.

THIS operation is considered to refer usually to the removal of the superior maxillary bone of one side, but to include also the rarer operation in which both bones—and therefore the whole of the upper jaw—are excised at one sitting.

**Instruments required.**—Gag ; tracheotomy tube ; scalpels ; tooth forceps ; bone-cutting forceps of various patterns ; sequestrum forceps ; lion forceps ; volsella ; metacarpal saw ; chisel and mallet ; rugine ; periosteal elevator ; strong scissors, both straight and curved on the flat ; dissecting, artery, and pressure forceps ; Paquelin's cautery ; hare-lip pins, needles, sutures, etc. ; sponge-holders.

Many operators make a practice of performing tracheotomy, and of then plugging the larynx with a piece of fine Turkey sponge to which a tape is attached ; or they make use of Trendelenburg's tracheal tampon-cannula.

The many different methods described for excising this bone are distinguished from one another by little else than the disposition of the skin incision.

The following operations will be described. The first represents what may be conveniently called the median incision, the second represents the cheek incision, and the third the method of exposing the jaw through a flap :—

1. The operation by a median incision.
2. Velpeau's operation.
3. Langenbeck's operation.

### 1. The operation by a median incision.

This procedure forms without doubt the best measure for excising the superior maxilla.

The patient lies upon the back, with the head and shoulders well raised. The face, if the patient be a male, should have been already shaved. The head is turned to the sound side.

The surgeon stands on the patient's right-hand side in dealing with either side of the jaw.

(1) The incision is commenced at a point half-an-inch below the inner canthus, is carried down by the side of the nose—where the nose joins the face—follows the groove which limits the ala nasi, and, skirting the nostril, reaches the median line of the lip.

While this cut is being made, an assistant may compress the facial artery.

When the lip is reached, the chief assistant grasps each extremity of the lip (at either angle of the mouth) between the finger and thumb, so as to compress the coronary arteries. The incision is then carried through the median line of the upper lip into the mouth (Fig. 73, A).

The superior coronary arteries are at once seized and secured.

(2) A second incision is now carried along the lower margin of the orbit. At its commencement it starts from the point of the first incision, and ends over the malar bone (Fig. 73, A).

(3) The cheek flap thus marked out is now rapidly raised from the bone, and should contain all the soft parts down to the maxilla. No attempt should be made to save the periosteum. In dissecting up this flap the infra-orbital artery is divided.

Throughout the operation sponge pressure is the main means of checking hæmorrhage.

(4) The operator should now separate the nasal cartilages from the bone, and should then divide the

nasal process. This may be done with a fine saw or a chisel. He should next proceed to divide the periosteum along the lower edge of the orbit. With the elevator the periosteum of the floor of the orbit is carefully raised, and in effecting this the origin of the inferior oblique muscle is separated.

With a fine chisel the orbital plate may be divided as far within the orbit as is necessary. The chisel-cut will commence at the point at which the nasal process of the maxilla has been divided, and will end at the speno-maxillary fissure. If it be considered necessary to take away the whole of the orbital plate of the maxilla, then a chisel-cut can scarcely avail, and the bone must be wrenched away from its attachments in the final act of removal.

The last step of this stage of the operation is to divide the malar bone. This may be done with a chisel or a small saw. The malar bone is divided obliquely (from above downwards and outwards) at a point about the centre of the bone, and the saw or chisel is so applied that the section will extend into the speno-maxillary fissure, the exact site of which should have been previously defined.

(5) The palate part of the bone alone remains with its connections undisturbed. The mouth having been well opened, the central incisor tooth on the diseased side is removed, the muco-periosteal covering of the hard palate is divided in the median line, and a knife is drawn along the floor of the nose from before backwards, and as near as possible to the septum. By means of a transverse incision made through the mouth, the soft palate is loosely separated from the hard.

A keyhole saw is now introduced through the nose, and the bony palate divided as near to the median line as is possible. This step of the operation should be rapidly performed, as there is often much

bleeding from the palatine arteries, which are necessarily divided.

(6) The surgeon finally grasps the bone with lion forceps, holding the instrument with its blades opened

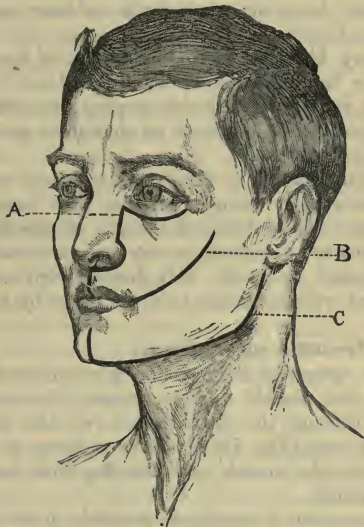


Fig. 73.—Excision of the Upper Jaw.

A, By a median incision; B, by Velpeau's method; C, excision of the lower jaw.

vertically. One blade takes hold of the orbital plate, and the other of the alveolus. The maxilla is then wrenched from its few remaining attachments. These will, in part, concern the orbital plate, and in part the attachment existing between the maxilla and the pterygoid process. The separation of the bone from the last-named process may be aided by bone-cutting

forceps bent at an angle, and introduced behind the maxillary tuberosity.

Care must be taken at this stage that the soft palate is freed completely from its connections with the hard.

Without bringing much force to bear upon the forceps the bone is finally removed.

(7) Any bleeding from the depths of the cavity should now be checked so far as is possible.

It will usually be desirable to plug the cavity with gauze. Carbolised iodoform or alembroth gauze may be employed.

The skin wound is finally united very carefully with silkworm-gut sutures, especial care being taken to accurately adjust the red margin of the lip. No hare-lip pins are necessary in any ordinary case.

The wound is finally well dusted with iodoform, and dressed with a sponge held in place by a flannel bandage.

### 2. **Velpeau's operation.**

In this operation the incision is commenced at the angle of the mouth, and is carried, in a curved direction, through the cheek to end over the centre of the malar bone (Fig. 73, B). The incision is carried directly into the mouth, and the flap thus formed is turned inwards.

The operation is completed precisely in the manner already described.

### 3. **Langenbeck's operation.**

In this method the skin incision commences at the side of the nose, at the junction of the nasal cartilage with the nasal bone. It then passes with a downward convexity to the junction of the upper lip with the cheek, and is finally carried upwards and outwards to end over the middle of the malar bone. In this way a large U-shaped flap is formed. The incision is carried down to the bone, and the flap reflected

upwards and outwards. The operation is completed in the manner already described.

## 2. EXCISION OF THE LOWER JAW.

A large number of the operations are partial, and only in a few instances is it necessary to remove the entire bone, *i.e.* both the right and left portions of the maxilla.

**Instruments required.**—The same as for excision of the upper jaw, with the addition of a small saw with a movable back, or a small Butcher's saw, and a needle in a handle for securing the tongue if necessary.

**Operation.**—The patient lies upon the back, with the head and shoulders raised, and with the trunk close to the edge of the table. The surgeon stands on the side to be operated upon. Some find it more convenient to stand on the patient's right in dealing with either side of the maxilla.

The head is turned to the sound side.

In male subjects the chin will have been already shaved.

1. A vertical incision is made through the tissues of the chin, in the middle line, starting just below the lip, which is not divided. From the lower end of this another incision is carried along and just below the inferior border of the jaw for its entire length, and is then directed upwards along the posterior margin of the ascending ramus, to end opposite to the lobule of the ear (Fig. 73, c).

The incision is carried throughout down to the bone, except in one place, *viz.* where the knife crosses the facial artery. Here the wound is only skin deep.

After the incision has been made, the surgeon returns to the spot indicated, exposes the facial artery

by dissection, secures it between two ligatures, and divides it.

With a periosteal elevator or rugine the muscles attached to the external surface of the maxilla are rapidly separated from the bone, and are turned up with the integuments in the form of a flap. The separation is commenced at the symphysis, and carried backwards. The buccinator and masseter are peeled off from the bone in this part of the operation. The mental and masseteric arteries, together with some smaller branches, are divided at this stage.

It is desirable that the operator should keep close to the bone.

The cavity of the mouth is now opened by dividing the buccal mucous membrane at its junction with the alveolus.

2. The surgeon now extracts one of the incisor teeth—the lateral incisor as a rule—and with a key-hole saw divides the jaw vertically in the line of the gap.

3. The anterior extremity of the divided maxilla is now drawn outwards, and with a blunt-pointed knife kept close to the bone the surgeon divides the attachment of the mylo-hyoid muscle. The internal pterygoid muscle is reached, and may be conveniently separated from the bone by means of a periosteal elevator. The lower border of the maxilla is twisted outwards, in order that the whole of the attachment of the internal pterygoid muscle may be dealt with.

The inferior dental artery and nerve are exposed and divided. In this part of the operation care must be taken to avoid injury to the sublingual and sub-maxillary glands.

4. The anterior part of the jaw is now forcibly depressed, in order to bring the coronoid process into view in the posterior part of the wound.

The tendon of the temporal muscle is divided, with



scissors curved on the flat, as each part of the fibres of insertion is successively reached.

Some surgeons divide the coronoid process with a chisel and mallet, and subsequently dissect out the fragment of bone thus isolated.

The jaw is still further depressed, in order that the condyle may be brought into view.

The external pterygoid muscle is reached, and is detached with the elevator or divided with scissors. The capsule of the joint is severed, the articulation is opened and the condyle freed. Throughout this stage of the excision the jaw should be merely depressed. It should not be twisted. If it be much everted or rotated out, the internal maxillary artery may be brought into contact with the neck of the bone, and may be accidentally divided, or even torn.

It only remains now to cut the bone free of its few surviving attachments, which are represented by the internal lateral, stylo-maxillary and pterygo-maxillary ligaments, together with more or less fascia and the remaining fibres of the outer pterygoid muscle.

All bleeding having been checked, the wound is united with silkworm-gut sutures. The chin part of the incision should be adjusted with especial care. A drainage-tube may be introduced into the hinder part of the wound, and retained there for twenty-four hours.

A dressing composed of a sponge dusted with iodoform, and kept in place by a layer of wool and a supporting bandage, will be found efficient.

OPERATIONS FOR THE RELIEF OF CLOSURE OF THE JAW.

### 1. **Esmarch's operation.**

In this operation a wedge-shaped piece of bone is removed from the horizontal portion of the maxilla, with the intention of establishing a false joint.

The *wedge* of bone to be removed must be taken

from the horizontal ramus of the jaw, anterior to the masseter, and in front of the contracted tissues. The base of the wedge will be below, and in an ordinary case in an adult should measure one inch and a quarter. The apex is at the alveolar border, and should be about three-quarters of an inch in width.

An incision, some two inches in length, is made along the lower border of the jaw at the spot at which it is intended to remove the wedge. The bone having been well exposed and the periosteum divided, a wedge of bone is removed with a keyhole saw, aided by the chisel and a periosteal elevator. After all bleeding has been checked the wound is closed by sutures.

## 2. **Excision of the condyle of the jaw.**

This operation is identical with the so-called excision of the temporo-maxillary articulation.

A vertical incision is made over the site of the joint and condyle. It is placed anterior to the temporal artery, starts at the lower margin of the zygoma, and ends below, just short of the transverse facial artery. The temporal artery may be considered to run about a finger's-breadth in front of the tragus, while the transverse facial artery is a little less than a finger's-breadth below the zygoma.

This incision may be joined by a second cut, which, starting from its upper extremity, follows the lower margin of the zygoma for about one inch.

The triangular flap thus marked out is reflected forwards. Care is taken not to damage any branches of the facial nerve nor any lobe of the parotid gland.

Such fibres of the masseter as come into view are separated from the zygoma, the capsule of the joint is exposed and opened, and the condyle brought well into view.

The neck of the condyle is now steadied by means

of a small blunt hook, and is divided either with a chisel or a keyhole saw.

The condyle is then seized with forceps, and is twisted out with the left hand, while the surgeon severs any remaining connections with a scalpel held in the right. Throughout the whole operation it is important that all instruments employed should be kept close to the bone.

## Part V.

### TENOTOMY.

---

INCLUDING OPERATIONS FOR THE DIVISION OF CONTRACTED MUSCLES, LIGAMENTS, AND FASCIAE.

THE tendon or band of fascia to be divided is usually unduly prominent, or can be readily made distinct. The tendon should, if possible, be so cut as to avoid opening a synovial sheath.

The tenotome should be lightly held, as one would hold a pen. The sharp-pointed instrument is carefully introduced close to the tendon, and makes a way for the blunt-pointed instrument.

The sharp tenotome is withdrawn, and the blunt instrument introduced, with the blade "flat"—that is, in a line with the line of the skin wound.

As the tenotomes are being introduced the tendon should be only stretched to such an extent as is necessary to render its position distinct. The tendon is divided with a sawing movement; it cuts with a creaking sound or sensation, and yields finally with a snap.

The left forefinger should be kept upon the skin at the site of the operation, in order that the movements of the tenotomes beneath the integument may be followed and guarded.

The operation is practically bloodless, and the only dressing needed is a pledget of wool dusted with iodoform. In forty-eight hours the little puncture may be considered to be healed.

The sickle-shaped tenotomy knife is seldom used in Great Britain, and figures in but few English catalogues.

PARTICULAR OPERATIONS.

**Tibialis anticus tendon.**—This tendon is usually divided as it crosses the scaphoid bone, and consequently about one inch above its insertion. At this point it should be free of its synovial sheath.

*2nd. Curved form +  
1st. Not a lineal*

In cases of congenital club-foot the tendon is displaced inwards, and is nearer to the malleolus.

The surgeon stands on the outer side of the limb in the case of either tendon. The assistant, who takes his place opposite to him, grasps the foot with one hand and the leg with the other. The foot is held in the position of extension and abduction, and the tendon is defined. The sharp tenotome is then entered vertically upon the outer side of the tendon, and is pushed downwards until it has reached a point below the level of the tendon. The tendon is put on the stretch. The sharp tenotome is withdrawn, and the blunt-pointed one inserted in its place. After it has reached the depth acquired by the first instrument (whose track it exactly follows) the foot is relaxed, and the blunt point is pushed nearly horizontally beneath the tendon, and may be felt on its plantar side. The tendon is once more put upon the stretch, and is divided by cutting upwards towards the skin. The left forefinger lies upon the skin over the edge of the knife, and forms a certain check to its movement. The surgeon cuts, indeed, upon the left finger, the skin intervening.

**Tibialis posticus tendon.**—The tendon is usually divided above the point of commencement of its synovial sheath, *i.e.* about the level of the base of the malleolus, and therefore above the inner annular ligament.

The surgeon stands to the outer side of the limb

in the case of either tendon. The assistant faces him, and grasps the foot with one hand and the leg with the other.

The position of the tendon is made out, and the foot is held a little extended and abducted, and is so turned as to lie upon its outer side.

The surgeon seeks for that point on the inner surface of the tibia where the malleolus joins the shaft of the bone. He reaches this point by following the posterior margin of the malleolus. The spot in question will be about a finger's-breadth above the tip of the malleolus in the infant, and about one and a half to two inches above that process in the adult. It is really on the shaft, and is above what would be called, anatomically, the base of the malleolus.

The surgeon fixes his left thumb-nail upon the margin of the bone, and enters the sharp tenotome vertically between the tibia and the tendon, using the nail as a guide. The instrument should be kept as near as possible to the bone. If properly inserted it will remain fixed, without any support of the hand. The tendon should not be too tightly stretched at this stage of the operation.

The fascia about the tendon should be freely divided by moving the point of the instrument to and fro, but without enlarging the skin-wound. Unless this be done, a proper way may not be made for the blunt-pointed instrument.

As the sharp tenotome is withdrawn the blunt one is introduced—the edge is turned towards the tendon, the tendon is put upon the stretch and is divided by cutting from the bone. The left forefinger, placed over the site of the tendon, forms a guide and a guard. The tendon of the flexor longus digitorum is usually cut at the same time and is often divided unconsciously.

**Plantar fascia, muscles and ligaments of the sole of the foot.**

These operations are concerned principally with cases of congenital talipes varus, and notably with such examples as are associated with considerable

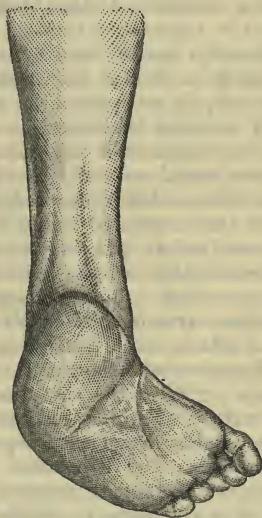

Fig. 74.—Sole of the Foot in Talipes Varus, to show the Creases on the Skin.

incurving of the sole. In the practice of some surgeons these plantar operations constitute the sole operative treatment of club-foot, if exception be made of tenotomy of the tendo Achillis.

*Simple division of the plantar fascia.*—The sole of the foot is well exposed, and the limb is firmly held by an assistant. The resisting bands of the plantar fascia are made out by putting the parts upon the

stretch. The part usually divided will be a little in front of the attachment of the fascia to the os calcis, or close to the transverse markings near the heel, which are conspicuous in severe talipes varus (Fig. 74).

A very fine narrow and short-bladed tenotome is employed, and is introduced between the fascia and the skin. The edge having been turned towards the resisting band, it is divided by cutting towards the depths of the sole, *i.e.* away from the skin.

The depth to which the cutting is continued must depend upon the thickness of the contracted tissue.

The surgeon would naturally avoid points where the fascia has become closely attached to the skin.

As a rule the contracted tissue will need to be severed at several points, and these multiple punctures are more efficacious than one single incision.

*Parker's operation—syndesmotomy.*—In cases of congenital talipes varus in children Mr. R. W. Parker is disposed to attach much more importance to the division of ligaments and the plantar fascia than to pure tenotomy. "With the exception of the tendo Achillis," he writes, "I think tenotomy in club-foot might be almost abandoned as a separate and independent operation. The two other tendons most frequently cut are the tibials, anterior and posterior. I believe, if it is necessary to divide them, that it should be done simultaneously with the ligaments with which they are closely associated, and this is most advantageously done at or near their insertions."

The site chosen for this combined section of ligaments and tendons is a spot a little below and in front of the tip of the inner malleolus, over the site of the astragalo-scapoid joint and in the situation of the transverse mark near the heel which is to be observed in severe talipes (Fig. 74). Two tenotomes



are needed—an ordinary sharp-pointed tenotome, and a curved one of sickle shape with a cutting edge about half an inch in length.

*The operation.*—The foot is so placed as to fully expose its inner border, and is firmly held; the position of the tendons and the arteries is made out so far as is possible.

At the spot above mentioned the sharp tenotome is entered. It should enter in front of the bifurcation of the posterior tibial artery, and behind the posterior tibial tendon. The knife is pushed forwards and outwards under the skin until a spot on the dorsum is reached just internal to the anterior tibial artery. The sharp instrument, which has made a track merely, is withdrawn. The curved tenotome is now inserted flat-wise under the skin, and follows the subcutaneous course already made until its point can be felt over the tibialis anticus tendon. The edge is turned towards the tendon, and is made to cut to the bone. It severs the tendon, and as it is withdrawn is made in like manner to cut the dense ligamentous tissue already described. Just as it is being withdrawn it is made to sever the tendon of the tibialis posticus.

During the introduction of the instruments the foot is relaxed. During the cutting of the tissues it is put upon the stretch, and the yielding of the divided ligaments and tendons is made very evident.

Although the internal saphenous vein must lie across the incision, the bleeding is usually quite insignificant.

The parts to be severed might be exposed by turning up a small flap of skin, which could be replaced and secured by sutures after the division had been completed.

**Tendo Achillis.**—This very powerful tendon, in the adult some four and a half inches in length, three-quarters of an inch in breadth, and a quarter of an

inch thick, is best divided at its narrowest part, *i.e.* about one inch above its insertion.

The patient may lie upon the back, with the body a little rolled over towards the affected side.

The foot is so turned as to lie entirely upon its outer side, and a small cushion placed beneath the lower part of the leg will carry the heel off the table.

The surgeon stands to the outer side of the limb, in the case of both the right and the left foot.

An assistant standing by his side holds the foot. Another assistant may steady the leg.

The tendon, having been defined, is rendered a little tense, but is not fully stretched. The sharp tenotome is entered vertically at the inner margin of the tendon, and is pushed downwards—in the present position of the foot—until it has reached the outer side of the tendon, where its point can be indistinctly felt. The sharp-pointed instrument is now replaced by the blunt, which follows the track already made until its point can in turn be detected through the skin. The tendon is now put well upon the stretch, and the cutting edge having been turned towards the surface, the tense cord is divided with a sawing movement, the left forefinger resting upon the skin over the site of the operation.

**Peroneus longus and brevis.**—Both tendons are usually divided together at a point about one inch and a half above the tip of the malleolus. The section if made here will be above the synovial sheath. The patient is rolled over upon the sound side, and the foot is so placed that it rests upon its inner surface, with the outer aspect uppermost. A firm cushion is placed under the lower part of the leg, and the foot is extended over it. An assistant steadies the foot and leg. The tenotome is introduced at the spot mentioned, is inserted close to the fibula, between the bone and the tendons, and has to be carried a little obliquely.

The peronei are rendered slack when the instrument is being introduced.

When the blunt-pointed tenotome is in position, the foot should be so held as to put the tendons upon the stretch, and they are divided by cutting from the bone, the skin being guarded in the usual way.

The short saphenous vein and nerve are posterior to the tendons at the place of election, and will not be endangered if the tenotome be kept close to the bone. The vein may be damaged if the whole operation be carried out with a sharp-pointed instrument.

If it be necessary to divide one tendon and not the other, the two structures should be exposed through a small incision, and the selected tendon drawn forwards and divided. The elaborate methods given for the subcutaneous division of a single tendon behind the malleolus are of no practical value.

**Extensor longus digitorum and peroneus tertius.**—The extensor tendons can be conveniently divided in front of or just below the ankle. In the latter situation there is greater risk of injuring the dorsalis pedis artery.

The patient lies upon the back, with the foot extended. The surgeon places himself to the inner side of the limb. An assistant grasps the leg and foot. The tenotome is entered upon the inner side, between the tendon of the extensor proprius pollicis and the tendons to be divided.

The usual precautions are observed. The blade is guided beneath the tendons, and the operator cuts towards the skin. The assistant should take more care to prevent the foot from falling suddenly after the tenotomy than to put the tendons upon the stretch during the section.

The knife must be kept close to the tendons, and as superficial as possible.

**Hamstring tendons.**—These tendons are most conveniently severed just above the line of the knee-joint, and on a level with the most prominent part of the condyles of the femur.

*Biceps.*—The patient should lie as far as possible upon the face, so that the popliteal space may be well exposed.

The surgeon may stand upon the inner side of the limb in the case of either the right or the left tendon.

The leg is steadied by an assistant. With a sharp-pointed tenotome a puncture is made directly over the tendon, and the instrument is passed vertically downwards on the inner side of the tendon, and is withdrawn when it has passed a little way beyond it.

The blunt point is now introduced, and, following the same line, is passed vertically between the tendon and the nerve. When it has just passed beyond the tendon, the blade is turned outwards, the handle brought as nearly horizontal as possible, and the point passed beneath the biceps until it may be felt upon the outer side.

The tendon is then divided by cutting towards the skin, which is guarded with the left forefinger in the usual way. During the introduction of the tenotomes and the cutting of the tendon the biceps should be kept upon the stretch. As the knife is withdrawn the limb should be flexed.

If care be not taken, the knife may slip through the skin when the tendon gives with a snap.

In the conditions for which this operation is usually performed the contracted biceps tendon is drawn away from the nerve, and a wider interval than the normal separates the two structures.

After the tenotomy the nerve may spring into view, and may be mistaken for an undivided portion of the tendon.

*Semi-tendinosus* and *semi-membranosus*.—The same observations as have been applied to the biceps apply generally to these tendons. They are most conveniently divided exactly opposite the spot selected for tenotomy of the biceps.

The tenotome is introduced upon the outer side of the tendon, and is passed beneath it. The steps of the little operation need not be repeated.

#### DIVISION OF THE STERNO-MASTOID MUSCLE.

This muscle, or a portion of it, is divided just above its origin in certain cases of wry-neck. Sometimes division of the sternal tendon of the muscle suffices.

The tenotomy is best carried out about one-fourth of an inch above the upper border of the clavicle and sternum.

The sterno-mastoid is in this situation covered by the cervical fascia, and is crossed by the suprasternal nerve. The anterior jugular vein passes behind it, just above the clavicle, and is in danger of being wounded. This vein is, moreover, subject to considerable variation. The external jugular vein is in close relation with the posterior or outer border of the muscle.

The head and shoulders are well raised and the trunk is brought close to the head of the table. The operation will be described as it would apply to the muscle of the *right* side.

The surgeon stands upon the affected side, facing the patient. An assistant placed at the opposite side of the table so holds the head as to place the muscle upon the stretch.

The sternal and clavicular portions of the muscle should be divided separately.

With a sharp-pointed tenotome a very small

vertical incision is made along the inner or anterior border of the muscle (the sternal tendon). The fascia is divided, and the tendinous margin is clearly reached. A blunt-pointed tenotome is now introduced, passed down to the tendon and then behind, and thrust along horizontally and on the flat, until its point can be felt in the gap between the clavicular and sternal portions of the muscle. It must be kept as close to the muscle as possible.

The edge is now turned towards the tendon, which is divided by cutting towards the skin.

The surgeon's left forefinger is placed as a guard over the integument covering the site of the tenotomy.

The sharp tenotome is in like manner entered at the posterior or outer border of the muscle, and the blunt instrument introduced and manipulated in the same way. The clavicular part of the muscle is then divided in the same manner as was the sternal portion. It will be noticed that, to divide the former, the knife is introduced from without in, and to divide the latter from within out. If more convenient, the puncture for the clavicular portion may be also made on the inner side, but this procedure involves a little more risk to the external jugular vein.

The surgeon may be disappointed to find that after the operation he is still unable to entirely correct the deformity. This will depend rather upon coincident contractions of the cervical fascia and the scalene muscles than upon an insufficient section of the sterno-mastoid.

In dealing with the *left* muscle, the operator will find it convenient to stand beyond the upper end of the table and lean over the patient's head to operate (*i.e.* he will face the patient's feet); or he may take up a corresponding position to that described in

dealing with the right side, and may cut both portions of the muscle through punctures made on the outer or posterior side of the part to be divided, commencing with the clavicular head of the muscle.

## Part VI.

### PLASTIC OPERATIONS.

#### CHAPTER I.

#### OPERATIONS FOR HARE-LIP.

##### SINGLE HARE-LIP.

**The instruments required.**—A fine, narrow, sharp-pointed scalpel or a small tenotome (for the less simple methods a slender double-edged knife is useful); slender-bladed dissecting forceps with toothed points; small sharp-pointed scissors curved on the flat; straight blunt-pointed scissors; artery forceps; sequestrum forceps with broad ends protected by india-rubber; needles and sutures; needle-holder; special "hare-lip forceps" to compress the lip; a gag and tongue forceps may be useful; properly prepared plaster; small fine sponges.

**The operation.**—The infant is wrapped up in a towel or sheet, so that the head alone projects.

The patient lies supine, with the head well raised and supported upon a sand-bag or firm cushion.

The surgeon faces the patient, or stands to the right-hand side. An assistant places himself behind the child, and steadies the head, while at the same time he compresses the facial arteries against the lower jaw. The administrator of chloroform will stand upon the left of the table.

*First step.*—Grasping the upper lip, the surgeon proceeds to separate it—upon each side of the gag—



from the maxilla. This can best be effected by means of small sharp-pointed scissors curved on the flat. The detachment should be sufficiently free to allow of the margins of the cleft coming together readily and without the least tension.

*Second step.*—The edges of the cleft are pared. The lower angle of one flap of the lip is seized with fine-toothed dissecting forceps, is drawn upon, and the margin is then pared with the narrow scalpel. The incision for paring the edge should commence above,



Fig. 75.—Operation for Single Hare-lip.

at the upper angle of the gap, and, descending obliquely, should curve inwards, when the red margin or lower angle of the flap is nearly reached (Fig. 75).

When one side has been treated, the other is dealt with.

The paring must be freely, liberally, and evenly carried out. The raw surface should be as wide as possible, especially below.

*Third step.*—The gap is now closed. The assistant who holds the head presses the cheeks together with his fingers, so that the two raw surfaces are approximated. The approximation must be exact. The margins are then united by means of silkworm-gut sutures carried on straight needles.

The first suture should involve the middle of the lip, the next the lower portion, and the third the

segment near the nostril. These are the three main sutures. They should include the whole thickness of the lip, excluding the mucous membrane only; and the first or median suture, if properly introduced, should command the coronary arteries when it is finally drawn tight.

It is well to pass the three needles one after the other, and to leave them in the tissues until it has been ascertained that the best possible approximation of the raw edges has been obtained.

The three stitches are introduced about one-third of an inch from each side of the cleft.

Two, three, or more sutures are now inserted at the free margin of the new lip, especially upon its inner or alveolar aspect. These are composed of fine catgut or fine silk, and are passed by means of slender curved needles held in a needle-holder.

Some of these fine stitches may be required along the main wound, and one will usually be needed for the margin of the nostril.

The wound having been well dried with small pieces of fine sponge, the surface is dusted with iodoform, and is covered with a strip of soft gauze. It is well that the wound be supported with strips of strapping.

#### OTHER OPERATIONS FOR SINGLE HARE-LIP.

**Mirault's operation.**—When the edges of the flap are very unsymmetrical, and when they diverge considerably, the following operation gives admirable results:—

A flap is cut from the shorter or more vertical margin of the cleft. It is free above, and is attached below near to the red border of the lip (Fig. 76, *a*). This flap must be composed of the entire thickness of the lip, must be large and substantial, and not a mere paring from the edge of the cleft.

The longer or more oblique margin of the gap is now freshened by paring, and care must be taken that the raw surface is as wide as possible.

The flap is now drawn down and placed in position, and the wound closed by sutures (Fig. 76).



Fig. 76.—Mirault's Operation.

In this operation it is especially important that the separation of the lip, which has already been insisted upon (page 317), should be very freely carried out. It may be necessary to detach one or both alæ.

**Giraldès' operation.**—This is adapted for severe forms of single hare-lip, where the margins are very

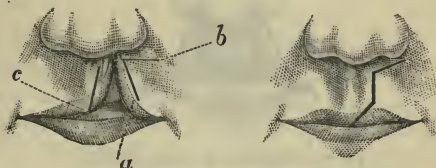


Fig. 77.—Giraldès' Operation.

unequal and divergent, and especially where the cleft enters by a large gap into the nostril.

The tissues on each side of the cleft must be well and extensively freed from the maxilla. From the shorter and less oblique margin of the cleft a flap (Fig. 77, *a*) is cut, as in Mirault's operation. From the upper end of the incision terminating this flap, a

second cut (*b*) is carried outwards, just below the border of the nasal aperture.

From the more oblique or longer side of the cleft another flap is fashioned with its apex or free end (*c*) downwards. The first flap (*a*) is drawn downwards, and forms the new margin of the lip. The other flap is drawn upwards, so that its apex (*c*) is fixed to the extremity of the incision (*b*), and this strip of tissue serves to form the lower boundary of the new nostril.

The somewhat complicated wound produced by the transposition of these flaps is closed by sutures, and the flaps themselves are securely fixed in place.

#### DOUBLE HARE-LIP.

The operation required in cases of double hare-lip is of the same character as that already described.

In many instances the defect is more easily remedied when it is double than when merely a single




Fig. 78.—Operation for Double Hare-lip.

gap exists. In the most favourable forms of double hare-lip the sides of the cleft are symmetrical, and are, moreover, more nearly parallel than is the case in single hare-lip.

A misplaced pre-maxillary bone is the most troublesome complication met with in dealing with this deformity.

*Operation.*—The skin over the pre-maxillary bone

is freed from its deep attachments behind, and its edges are pared so that it receives a U- or V-shaped outline (Fig. 78). The margins of the lip on each side are then pared in the manner already described (page 317). The portions of the lip may or may not need to be freed from their attachments. The raw edges are




Fig. 79.—Operation for Double Hare-lip.

finally united with silkworm-gut sutures. Owing to the small size, and the shape of the central piece the resulting wound is more or less Y-shaped.

In order to avoid the notching which not infrequently occurs in the median line, when cicatrization has taken place after this operation, thick flaps with square ends may be cut from each margin of the main cleft, as shown in Fig. 79. These flaps have their attached ends downwards. They are united to the raw margins of the central segment above, and to one another along, what is now the new margin of the lip. The segments of the lip will need to be freed from their deep connections on each side of the cleft.

## CHAPTER II.

## OPERATIONS FOR CLEFT PALATE.

THE term *staphyloraphy* is applied to the operations upon the soft palate; the term *uranoplasty* to those upon the hard palate.

The union of both parts of the palate should be attempted at one operation.

Mr. Smith makes one proviso. "When the bringing together of the whole cleft in one operation would necessitate so free a division of the soft parts as to endanger the vitality of the flaps, it is advisable to close first that part of the cleft that can be most easily approximated, whether it be the hard or the soft palate. This, if successful, will secure for the remaining portion a large supply of blood in the subsequent operation."

**Instruments.**—The following are the instruments required:—Two sharp-pointed tenotomy knives in long and slender handles for paring the edges of the cleft; a blunt-pointed knife of the same kind for making lateral incisions to relieve tension; two pairs of long slender-bladed forceps, one serrated, and one with tenaculum points; a fine hook; a pair of small sharp-pointed scissors curved to a quarter circle, for dividing the connection of the soft palate with the nasal mucous membrane at the posterior margin of the hard palate; small blunt-pointed scissors, curved on the flat, for the sutures, etc.; plate raspatories curved as an aneurysm needle, and another raspatory very slightly curved (Smith's raspatories, or Ollier's instrument, are admirably suited for the purpose); two needles on long handles, and with eyes at the

point (Smith's pattern), for the fine sutures; Smith's instrument for catching the sutures at the eye of the needle; a tubular needle with a reel at the base for the wire sutures; a wire twister (ordinary torsion forceps make fair wire twisters).

A gag is needed, and Smith's well-known instrument answers in most cases admirably. It is most important that it should fit the patient, and that it should be carefully adjusted. Mr. Smith points out that cases are met with where the continued depression of the tongue causes difficulty in breathing. In such instances Mason's gag may be used, and the tongue be held down by a rectangular spatula.

With regard to the suture material, horsehair answers admirably for the uvula, and for the lower and flaccid part of the velum.

For the principal sutures, well-annealed silver wire or silkworm gut should be used.

**Position of the patient.**—The upper part of the body must be well raised, and the head be placed sufficiently high to prevent the surgeon from stooping. The head should rest upon a hard cushion, or be received in a depression in a sand-bag. It must be thrown well back. The surgeon stands on the right facing the patient.

#### THE OPERATION ON THE SOFT PALATE.

The gag having been introduced, the first step is to pare the edges of the cleft. The tip of one half of the uvula is seized with the tenaculum forceps, and is drawn upon so as to make the palate tense. With a sharp-pointed knife the edge is now pared from below upwards, *i.e.* from the free margin of the velum towards the hard palate. The knife may follow the anterior angle of the cleft (assuming the hard palate to be sound), and may return in the opposite direction

along the other margin of the cleft, that side of the velum being made tense in turn.

The next step is the passing of the sutures. They should be introduced from below upwards. The first suture is passed through the halves of the uvula, and after it has been tied, it is left uncut so that it may be used to make the edges tense, and thus avoid any handling of the palate with forceps. When the next suture has been introduced, the one below (in this case the first suture) may be cut short.

Throughout this stage of the operation the suture last passed is always left uncut, so that it may be used to draw upon the margins of the cleft and steady them while the next stitch is being introduced.

The sutures must be placed at a sufficient distance from the margin of the gap to secure a good hold, and their number and arrangement must depend upon the degree of tension at any particular point.

The sutures should, whenever possible, be passed through both sides of the palate at one transit of the needle. The finer sutures (those for the uvula, for example) are passed by means of the rectangular needle, the others by one of the needles in handles used for carrying wire or silkworm gut. If the edges of the cleft will come together, the sutures should be fastened off at once by tying or twisting, as the case may be.

If the cleft be narrow, the sutures can be passed without difficulty. If it be wide, some especial method may have to be adopted.

The following is the most convenient:—A very long suture has a needle threaded at each end of it. One needle is passed through the left flap of the palate from behind forwards, and the other through the right flap in the same direction. The first needle passed must be held by an assistant while the other is being introduced. This is practically the method



usually adopted in closing an abdominal incision. The needles employed should be small and curved, and must be passed by means of a simple needle-holder. Needles of various curves should be at hand. In no operation is a complex needle-holder more out of place than in this.

“When there is too much tension to admit of the sutures being tied at once, they should all be passed, and being loosely twisted, the long ends may be cut off, and longitudinal incisions may be made on either side parallel to the cleft, and just internal to the hamular process, avoiding the immediate neighbourhood of the posterior palatine foramen. It is well to make this incision with a blunt-ended knife, after puncturing the palate with a sharp-pointed knife. Sufficient relaxation being obtained, the remaining sutures should be quickly fastened off by twisting with torsion forceps” (*T. Smith*).

If after the lateral incisions have been made the tension is not amply relieved, it is well to introduce a slender-pointed raspatory through the incision, and with it to detach the muscular and tendinous structures from the hamular process. I have found such a step always to answer its purpose completely.

#### THE OPERATION ON THE HARD PALATE.

The following is Mr. T. Smith's description of the operation. The procedure, although somewhat modified, is usually known as Langenbeck's operation:—

“If there is sufficient material for closing the palate, the mucous edges of the cleft may be pared. If there is any doubt about this, the proceeding must be dispensed with, as involving a waste of flap. To bring down the muco-periosteum from the bones, a mere puncture should be made down to the bone with a scalpel, midway between the teeth and the margin of the cleft, and opposite the middle of the cleft

(*i.e.* midway between the anterior angle of the cleft and the posterior margin of the hard palate). Through this puncture the least curved of the raspatories should be thrust between the periosteum and the bone, and be pushed onwards towards the middle line until its point appears in the cleft. At this spot one of the more curved raspatories should be inserted, the instrument first used being withdrawn.

“The curved raspatory should now be used to separate the muco-periosteum from the bone, and this is best accomplished by to-and-fro movements, and by careful traction. The periosteum is easily detached until the posterior margin of the hard palate is reached, where the soft palate is firmly attached by fascia, and by its connection with the mucous membrane on the floor of the nose.

“Curved scissors should be used to divide this attachment, the palate being drawn forward with a hook to put it on the stretch while the scissors are passed behind it.

“The scissors may now be used with closed blades, as a raspatory, to draw forward the soft parts at the junction of the hard and soft palate, and complete their separation from the bone. When the hard palate is cleft up to the incisor teeth, there is often difficulty in completely separating the periosteum at the anterior angle of the fissure. Should this be the case, a small rectangular knife can be used to free the soft parts.

“The muco-periosteum being completely separated from one side of the palate, the assistant should thrust a sponge into the cleft, and press the flap firmly against the bone. This will restrain all hæmorrhage, give an opportunity for cleansing the fauces from blood, and allow of the re-administration of chloroform.

“The soft parts being separated from the bone on

the opposite side of the cleft in the same manner, the sutures may be passed as in the soft palate, silver wire being used, and each suture being twisted up as far as practicable without risk of breaking, and cut short, so as to leave about a sixth of an inch projecting.

“Tension should be relieved by prolonging the small incisions made for the introduction of the raspatory forwards or backwards, as the circumstances of the case may require.

“The incisions should go quite through the palate, and they are best made with a probe-pointed knife. All slack sutures should now be twisted up with torsion forceps until the edges of the cleft are in exact apposition. In bringing together this part of the palate, care must be taken to evert the edges of the cleft with a small double hook in passing and twisting up the sutures; this secures the apposition of the raw surfaces of the flaps, and it is especially necessary when the edges of the cleft have not been pared” (Heath’s “Dictionary of Surgery”).

The gaps left by the dragging of the flaps towards the median line are allowed to close by granulation.

## CHAPTER III.

## OPERATIONS FOR RUPTURED PERINEUM.

THE description of the operation given by Dr. Galabin, in his work on "Diseases of Women," has been largely followed in the subjoined account. The two woodcuts which illustrate the operation have been derived from the same source.

## OPERATION FOR PARTIAL RUPTURE.

The patient is placed in the lithotomy position, and the thighs are supported by means of Clover's crutch. The buttocks are brought well up to the end of the table. The surgeon sits facing the perineum. Two assistants stand by the patient's pelvis, and each retracts the labium with one hand, while he sponges and otherwise assists the operator with the other. The extent of surface to be freshened is indicated, to some degree, by the cicatrix left by the laceration. "It is well, however, to go a little beyond the limits of this in all directions, especially up the median line of the vagina, and towards the lower halves of the labia majora, both in order to secure, if possible, a perineal body somewhat larger and deeper than the original one, and to allow some margin, in case the surfaces do not unite completely up to the edges. To put the mucous membrane on the stretch an assistant at each side places one or two fingers on the skin of the thigh, and draws the vulva outwards. The skin just beneath A (Fig. 80), in front of the anus, may also be seized by a tenaculum, and drawn downwards. If still the mucous membrane is not sufficiently on the stretch, from laxity of the vagina, the posterior

vaginal walls, some distance above B, should be seized by long-handled tenaculum forceps, and pushed upwards.

“Incisions are then made through the mucous

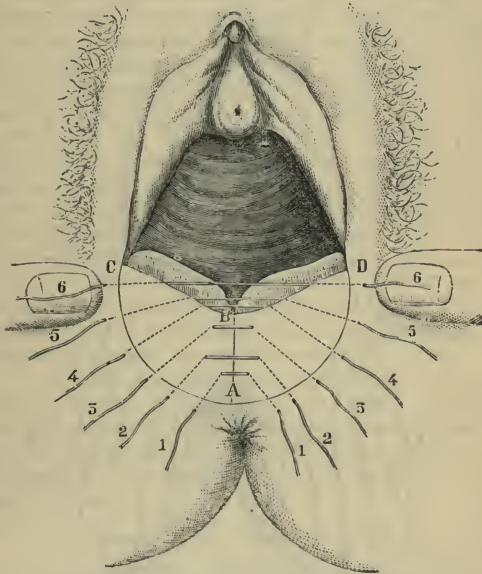


Fig. 80. — Repair of Ruptured Perineum. (Galabin.)

membrane, from B to A, in the median line of the vagina, and from A to C and D, through the junction of the mucous membrane and skin (Fig. 80). These should not be extended in the direction of C and D farther than the lower extremity of the nymphæ at the utmost. There are then two triangular flaps—

A B C and A B D. These are to be dissected up from the apex A towards the base B C and B D, the corner of the mucous membrane at A being seized with dissecting forceps. The dissection should not be deeper

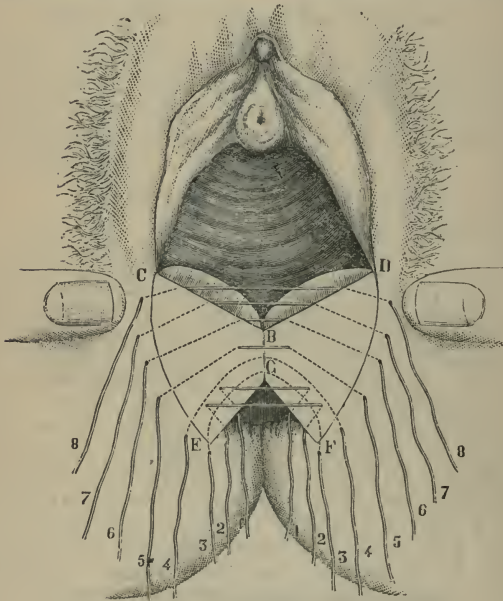


Fig. 81.—Repair of Ruptured Perineum. (*Galabin.*)

than necessary, and if it is done with the knife the surfaces are more ready to unite. If, however, there is much tendency to bleed, scissors may be used. The apices of the flaps are then cut off with scissors, leaving an upturned border along B C and B D. When the

surfaces are drawn together, these borders form a slightly elevated ridge towards the vagina; and if there be any failure of union just along the edge, they fall over and cover it" (*Galabin*).

Silkworm gut forms the best suture material. The sutures may be most conveniently introduced either by means of a curved needle in a handle or by means of a large Hagedorn's needle held in a holder. They should be introduced as shown in Fig. 80, the dotted lines representing the buried parts of the suture. The sutures 1, 2, and 3 may be buried along the whole length of their course. "If, however," writes Dr. Galabin, "they are brought out in the centre for spaces alternately short and long (Fig. 80), the surfaces are more easily brought into contact at all levels without undue tension."

The sutures 4, 5, and 6 are brought out close to the margin along which the folds of mucous membrane, BC and BD, are turned up from the vagina, and are not passed through the mucous membrane itself.

The sutures are tied in order from behind forwards—*i.e.* from No. 1 to No. 6. As they are being secured a stream of some antiseptic solution from an irrigator should be allowed to play over the surface, in order that no blood clot may be enclosed in the depths of the wound.

#### OPERATION FOR COMPLETE RUPTURE.

The preliminary measures, already described, having been taken, the operation is proceeded with as follows:—

"A point (B, Fig. 81) in the median line of the vagina, a sufficient distance above the apex of the rent in the septum, is taken, and an incision through the mucous membrane is made from B to G, and from G to E and F along the edges of the septum, between the rectal mucous membrane and the cicatrix. Incisions

are also made through the skin from *E* to *C*, and *F* to *D*, so that the freshened surface may extend somewhat beyond the limits of the cicatrix, *C* or *D* not to be higher than the lower extremities of the nymphæ. The quadrilateral flap *E G B C* is then seized at *E* by dissecting forceps, and dissected up with the knife from the angle *E*, and afterwards from the angle *G*, towards the base *B C*. While this is done the parts are kept on the stretch by an assistant drawing down the skin below *E* with a tenaculum. The flap is then cut away with scissors, except an upturned border, which is left along *B C*. The flap *F G B D* is treated in a similar manner. If, as is usual, the ends of the sphincter at *E* and *F* have retracted from the margin of the cicatrix, it is well to cut away with the scissors a narrow strip of rectal mucous membrane, generally somewhat everted, a short distance from *E* and *F* towards *G*, so as to bring the freshened surface to the ends of the sphincter.

“Sutures of silkworm gut are then applied in the following manner:—First rectal sutures, either two or three, according to the extent of the rent in the septum, are applied. These are destined to be tied in the rectum, and the ends left projecting through the anus. They are best applied with a half-curved needle, held in a holder. The needle is passed in a little distance from the margin of the rent, and brought out almost at the very edge of the rectal mucous membrane, on the line *G F*. The needle is then threaded at the other end of the suture, and that is drawn through in the same way from without inwards on the margin *E G*. Next, two sutures at least are passed completely round through the remnant of the septum, by means of a curved needle, not too large, mounted in a handle. This is passed unthreaded, and draws the suture back with it on withdrawal. The first of these (3, Fig. 81) is passed in somewhat behind and below the angle *F*,



so as to take up, if possible, or at least go quite close to, the end of the divided sphincter, and is brought out in a similar position near E. Thus, when tightened, it brings together the ends of the sphincter, drawing it into a circle; but it often brings into apposition, not so much the freshened surfaces above as the un-freshened rectal mucous membrane. This serves as a barrier to keep out faecal matter, while the next suture (4) aids the rectal sutures in uniting the freshened surfaces. The remaining sutures (5 to 8) are passed, as shown in the figure, by a slightly curved needle mounted in a handle, in the same way as in the operation for incomplete rupture" (*Galabin*).

When all the sutures are in position they are tied in the order of their numbers, and the operation is completed as in the previous account.

## Part VIII.

## OPERATIONS ON THE NECK.

## CHAPTER I.

## TRACHEOTOMY.

THE operation is said to be "high" or "low," according as the trachea is opened above or below the isthmus of the thyroid body. In the adult the isthmus crosses the second and third rings of the trachea, and sometimes even the fourth. In the child the isthmus is narrow, and is usually somewhat higher up. The high operation is always to be preferred; it alone is described in the account which follows (Fig. 82, v and vi).

**Instruments required.**—Scalpels; dissecting, artery, and pressure forceps; toothed forceps (Liston's artery forceps without the catch answer the purpose); sharp hook; blunt hook; scissors; needles; tracheotomy tubes and tapes. To these may be added a gag and tongue forceps, small wound retractors, and feathers to clear the tube, when first introduced.

A good tracheotomy tube should be of simple construction, should be easy to introduce, should be as large as the diameter of the trachea will admit, should lie exactly in the long axis of the windpipe without touching the tracheal wall with its extremity, should have a movable shield so that it is disturbed as little as possible, and the inner cannula should be capable of being easily inserted and removed.

## THE OPERATION.

1. **Position of the patient.**—The child is enveloped in a thin macintosh sheet, and is placed close to the right edge of the table. The surgeon stands by the same side of the table. The neck is supported on a firm sand-bag of suitable size. When the child is ready the head should be drawn well over the upper end of the table, so that the vertex is turned nearly towards the ground.

The anæsthetist stands at the head of the table, and the important duty should be imposed upon him of holding the head steady, and of keeping the chin most rigidly in line with the sternal notch. If the head be allowed to fall over to one or other side, the position of the middle line is lost.

An assistant stands by the side of the anæsthetist, and will, later, take charge of the sharp hook.

2. **The exposing of the trachea.**—An incision is made with a sharp scalpel very precisely in the median line of the neck. Its length will be about one inch or an inch and a half, and its upper extremity will be at the upper border of the cricoid cartilage.

The skin and the trachea are steadied with the left hand while the cut is being made.

The right hand must be unsupported. If the operator rests his wrist upon the upper part of the child's chest, as he is tempted to do, he will find that the rapid movements of the thorax in laboured breathing render that part no proper place for support.

The surgeon, still fixing the trachea and soft parts with the left hand, cuts deliberately in the middle line through the subcutaneous fat and the anterior layer of the cervical fascia. The sterno-hyoid and sterno-thyroid muscles are reached, and the interval between them is opened up. All this is done by successive clean cuts.

The surgeon now separates the muscles, using the dissecting forceps and the handle of the scalpel for the purpose.

Keeping still to the middle line, and once more steadying the trachea, he divides cleanly, and by cautious cuts, the fascia covering that tube.

At this stage veins will probably be encountered, and may be displaced to one or other side by the handle of the scalpel. The isthmus of the thyroid will be seen, and is by a like means displaced downwards. If necessary, it may be drawn and held downwards by a small blunt hook.

The surgeon now feels for the tracheal rings with his left forefinger. He should be satisfied that the tube is well bared, and he should be able to see the white rings themselves.

**3. The opening of the trachea.**—A small sharp hook is now introduced into the cricoid cartilage, and is given to the assistant to hold who stands at the head of the table.

The hook is kept precisely in the middle line, and is used to fix and draw forwards the cricoid cartilage, and to render the trachea tense. The assistant must give a little play to the hook, as the larynx moves with each inspiration.

With the left forefinger the operator feels the upper rings of the trachea, and with a slender scalpel, held with the edge towards the patient's chin, he stabs the trachea in the median line some three rings below the cricoid, and cuts up on to the hook (v, Fig. 82).

The noisy rush of air entering and escaping through the wound, the coughing of the child, and the expulsion of mucus and membrane bring about a moment of confusion. The hook must not be removed. It remains as an easy guide to the median line of the trachea and the site of the opening therein.

4. **The introduction of the tube.**—The right margin of the cut in the trachea should be lightly seized with the toothed forceps, which are held in the left hand; and while the opening is thus for a moment demonstrated and fixed, the tube and pilot are slipped in. If the forceps be employed as directed, the tube can be introduced with certainty and ease.

It will usually be found more convenient to restore the child's head to the erect position before the tube is introduced. When the tube is in place—and not before—the sharp hook is removed.

The tube is secured in place by tape, and the wound below the tube is brought together by a suture or two of silkworm gut. A piece of lint properly shaped and smeared with a weak iodoform ointment is placed under the shield of the tube, and is made to cover and protect the wound.

#### TRACHEOTOMY BY BOSE'S METHOD.

A vertical incision is made in the median line. It commences opposite the centre of the thyroid cartilage, and is continued downwards for about one and a half or two inches. The incision is carried down to the lower part of the thyroid cartilage and the upper part of the cricoid. The soft parts being held aside by retractors, a transverse incision is made along the upper border of the cricoid cartilage in such a way as to divide the layer of the deep cervical fascia which lies in front of the trachea, and which holds the thyroid isthmus. A blunt director is now introduced through this transverse incision, and by its means the fascia and the isthmus, together with all the veins connected therewith, are fully separated from the trachea. A broad, curved hook is now introduced, and the detached fascia, together with the other soft parts, is drawn downwards, leaving the

trachea quite bare. The cricoid cartilage is now fixed by means of a double-pointed sharp hook, and the tracheal rings are incised in the usual way.

This method has much to commend it. It is simple and easy of performance. It involves some expenditure of time, and some damage may be done to adjacent structures by the director if care be not used.

**Comment.**—As an operation *quâ* operation, tracheotomy must be regarded as an easy and simple procedure. Those who have performed it only upon the dead subject must be at a loss to understand the terrible possibilities with which the introduction of a tracheotomy tube appears to be surrounded. In the adult, the operation is certainly but rarely in any way difficult or complicated; in an infant with a short, stout neck, on the other hand, it may be attended with not inconsiderable difficulties.

The following rules should be observed :—

1. Let the chin be kept rigidly in a line with the sternal notch.
2. Cut only in the middle line.
3. Avoid anxious assistants with retractors.
4. See the white rings of the trachea, and feel them bare before plunging the knife into the windpipe.
5. Avoid hurry.

#### LARYNGOTOMY.

Laryngotomy, or the artificial opening of the larynx through the crico-thyroid membrane, is occasionally performed as a substitute for tracheotomy. The operation has the advantage of being very rapidly and very easily carried out. It is quite inapplicable to children under thirteen years of age, owing to the narrowness of the crico-thyroid space. The great drawbacks of the operation are the proximity of the vocal cords and the difficulty of adjusting a suitable

tube. Laryngotomy is unsuited for cases in which a tube has to be long worn.

The vertical height of the crico-thyroid space in

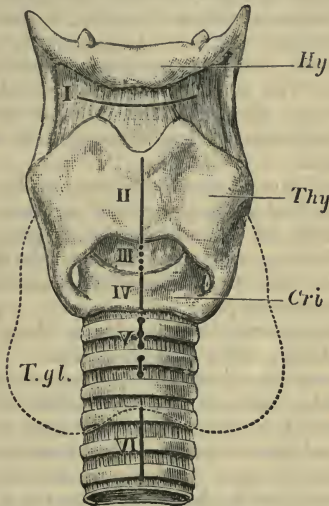


Fig. 82.—Operations on the Larynx and Trachea. (Tillmann's.)  
 I, Subhyoid pharyngotomy; II, thyrotomy; III, laryngotomy; IV, cricotomy;  
 V and VI, high and low tracheotomy; Hy., hyoid bone; Thy., thyroid cart.;  
 Cri., cricoid cart.; T. gl., thyroid gland.

the well-developed adult subject is only about half an inch.

For the general surroundings of the operation, and the instruments required, the reader is referred to the sections on Tracheotomy.

**The operation.**—The head is well extended over a sand-bag or hard cushion, and is kept fixed, with the chin in a line with the sternal notch. The

anæsthetic selected is chloroform. The anatomical details of the part must be made out, and the crico-thyroid space defined (Fig. 82, III).

The larynx is lightly steadied with the left hand, while the surgeon makes a vertical median incision, about an inch and a quarter long, over the lower part of the thyroid cartilage, the crico-thyroid space, and the cricoid. The fascia having been divided, the interval between the sterno-thyroid and crico-thyroid muscles is appreciated, and widened with the handle of the scalpel.

The crico-thyroid membrane is exposed and divided horizontally, just above the cricoid cartilage.

Care must be taken that the air-passage is well opened, as it is not difficult to pass the tube downwards between the crico-thyroid membrane and the mucous lining of the windpipe.

The laryngotomy tube is shorter than that used for tracheotomy, and is oval on section.

Some surgeons advise that the membrane be opened by a vertical incision, on the grounds that the operation can, if desired, be extended by dividing the cricoid cartilage, and that in the horizontal incision damage is usually inflicted upon the crico-thyroid muscles, and possibly also upon the lateral crico-arytenoid muscles.

**Suprathyroid laryngotomy.**—This operation, which is sometimes called subhyoid pharyngotomy, has been on a few occasions employed for the removal of growths situated at the upper opening of the larynx, and particularly of such as are connected with the epiglottis. The operation is simple, but even in the adult it rarely affords sufficient access for the efficient use of instruments (Fig. 82, I).

A transverse incision is made through the thyro-hyoid membrane, parallel and close to the lower border of the hyoid bone. The skin, the fascia, the sterno-hyoid muscles (in whole or in part), the



thyro-hyoid membrane, and the mucous membrane, are divided in order.

The epiglottis is at once exposed, and is drawn through the wound. The growth having been dealt with, and the bleeding checked, the wound is closed. The vessels wounded are few and insignificant, and the incision heals quickly.

#### THYROTOMY.

By thyrotomy is understood the division of the thyroid cartilage in the median line, so as to gain access to the interior of the larynx. The operation is carried out for the purpose of removing certain laryngeal growths, and certain large or impacted foreign bodies, especially such as have found their way into the ventricles (Fig. 82, II).

**The operation.**—The head is extended over a hard cushion or sand-bag, and is firmly held with the chin in a line with the sternal notch. The shoulders are raised. A preliminary laryngotomy or tracheotomy is carried out. The position of the opening for the tube will depend upon the nature of the case, the length of time the tube will probably have to be worn, and upon other circumstances.

If much hæmorrhage is anticipated, as will be the case in dealing with extensive papillomata, the trachea must be plugged. This may be effected by a tampon, such as Trendelenburg's tracheotomy tampon, or by gently plugging the trachea on each side of the tube with a piece of fine sponge properly shaped, and attached to a long silk thread.

The incision is prolonged upwards in the median line, and the skin and subcutaneous tissues are divided down to the cartilage. The incision will extend over the cricoid and thyroid cartilages, the crico-thyroid space, and some part of the thyro-hyoid space.

The thyroid cartilage is divided accurately and

carefully in the median line, the thyro-hyoid and crico-thyroid membranes being also cut if needed.

The division of the cartilage should be effected from above downwards, and from without inwards. In young subjects, and in females who have not passed middle life, the section may be accomplished by a small but stout knife. In aged subjects, in whom the cartilage will be calcified, a fine saw may be needed to effect a division. Bone forceps should never be employed.

By means of two small sharp hooks the two *alæ* are now drawn aside, and the interior of the larynx is exposed. In old subjects it may be necessary to make transverse incisions in the crico-thyroid and thyro-hyoid membranes, close to their respective cartilages, before the fullest view desired can be obtained.

The foreign body may now be extracted or the growth removed.

Finally, the two portions of the thyroid cartilage are united by two or three fine silver wire sutures, and the wound in the skin is closed.

## CHAPTER II.

## EXCISION OF THE LARYNX.

THE term Laryngectomy has been applied to this operation. It involves the removal of either the whole of the larynx (complete excision), or of a considerable portion of it—usually one-half (partial excision).

## COMPLETE EXCISION.

A preliminary tracheotomy should be carried out, if possible, two weeks before the excision is attempted.

**The plugging of the trachea.**—After the patient is anæsthetised, and before the actual excision is commenced, means must be taken to prevent the entrance of blood into the air-passages. This is most surely effected by some form of tampon.

The well-known tampons of Trendelenburg or Hahn are the ones usually employed.

Many surgeons discard all special apparatus and use a simple cannula around which a piece of sponge is so inserted that it acts as a plug.

**The operation.**—The patient lies upon the back, close to the right border of the table. The shoulders are raised, and the head is well extended over a hard cushion or sand-bag. The surgeon stands on the patient's right. An incision is made in the median line from the centre of the thyro-hyoid membrane to the second or third ring of the trachea. At the upper end of this incision a transverse cut is made, which is carried outwards on each side sufficiently far to reach the sterno-mastoid muscles.

The flaps thus marked out are turned back. Some division of the fibres of the sterno-mastoid muscles

may be necessary. The vertical incision should go down to the thyroid and cricoid cartilages and the trachea.

The superior thyroid arteries may, if thought fit, be dealt with at this stage. They should be secured by two ligatures, and then divided between them. The vessels would be sought for at the posterior margin of the thyro-hyoid muscle, close to the upper border of the thyroid cartilage.

The inferior thyroid arteries may be exposed and dealt with in the same manner as they turn forwards at the lower margin of the larynx. They should be sought beneath the posterior edge of the sternothyroid muscle.

The fascia having been well divided in the middle line, a broad periosteal elevator or a rugine is introduced, and by means of it the soft parts can be separated from the laryngeal cartilages without employing the knife.

The muscles are detached on one side, and are, together with the other soft parts, held with a retractor while the larynx is, by means of a sharp double hook, drawn over to the other side. The attachment of the inferior constrictor muscle to the thyroid cartilage can now be severed. The larynx is now pulled forwards as well as to the opposite side, and the tissues are divided about the gap which intervenes between the cut and now separated ends of the superior thyroid artery. The superior laryngeal nerve is also divided. The thyroid gland is pushed aside with the soft parts.

If the larynx be now well drawn over to the other side, the other half of the organ can be stripped of its coverings in precisely the same manner.

The next step is to divide the thyro-hyoid ligaments and membrane, and to cut the extra-laryngeal connections of the epiglottis.

The entire larynx is now pulled forwards by means of sharp hooks introduced into its upper part, and the organ is separated from its remaining connections with the pharynx and œsophagus—at first laterally, and then from above downwards.

The trachea is next secured (unless already adherent) by means of two ligatures, which are held by an assistant, and the excision is completed by dividing the membrane between the cricoid cartilage and the trachea from behind forwards.

One or more rings of the trachea may be removed at the same time if it be considered necessary.

The upper end of the divided trachea, which has been prevented from slipping down by the two ligatures, is now secured to the integument by several points of interrupted suture.

The bleeding throughout the operation will be free, and each small vessel should be ligatured as soon as it is divided. The limited space does not favour the use of many pressure forceps.

#### PARTIAL EXCISION.

This operation is carried out upon the same lines as the complete excision. One-half only of the larynx or of the thyroid cartilage is removed.

The details of the operation are practically the same.

A preliminary low tracheotomy may be carried out some little time before the excision is attempted.

The incision is the same, save that the transverse portion need occupy only the diseased side. A tampon-cannula is introduced.

The larynx is laid bare in the middle line, and the thyroid cartilage is divided so that the interior of the larynx may be inspected. Preliminary ligature of the thyroid arteries is unnecessary.

The thyroid cartilage is now removed. It is

cautiously bared of the soft parts which cover its outer surface by means of an elevator or a rugine. The attachments of the pharynx are separated by like means. The thyro-hyoid and crico-thyroid membranes are divided upon the affected side as close as possible to the margin of the thyroid cartilage. The superior cornu of this cartilage is divided at its base by pliers. The epiglottis is left, and the aryteno-epiglottic fold of the affected side is divided close to the cartilage of Wrisberg. In some cases the epiglottis has been split, and one half removed.

Every care must be taken to avoid opening the pharyngeal cavity.

In partial excision for intrinsic disease there is usually no necessity to remove the cricoid cartilage.

## CHAPTER III.

## EXCISION OF THE THYROID BODY

## COMPLETE EXCISION.

THE method of operating here described is that known as Kocher's. The patient lies upon the right-hand side of the table, with the shoulders well raised, and the head extended over a large sand-bag or hard cushion.

Every preparation must be made for extensive hæmorrhage.

An incision is made in the median line from the sternal notch to the upper limit of the bronchocele. From this point two lateral incisions are made upwards and outwards, one on each side. They are directed towards a point a little below the angle of the jaw, and when the cutaneous cut is complete it will have the outline of the letter Y.

The platysma and fascia are divided. Any veins which are met with are secured.

The sterno-hyoid, sterno-thyroid, and omo-hyoid muscles will need to be divided in whole or in part.

It may be necessary even to cut one or both of the sterno-mastoid muscles. The operator must trust but little to retractors, but must rather aim at obtaining the fullest view of the bronchocele by dissection.

No instrument is more serviceable in this stage of the operation than a broad periosteal elevator. Its point is so blunt that it can do little damage, and its configuration is admirably suited to peel the tissues away from the capsule. This must be done with great care. The elevator is made to work its way beneath the muscles and the fascia, and when the precise

relations are clear the tissues are divided over the elevator as over a director. In effecting this exposure of the goitre a pair of blunt-pointed scissors curved on the flat is more useful than a scalpel, and the handle of the scalpel is of more service than the blade.

A plexus of large, thin-walled veins will usually be found covering the tumour. They must be separately treated, and must be individually divided between two ligatures.

Step by step the surgeon clears the whole of the front surface of the swelling, dealing with every bleeding point as it is met with, and not trusting either to the pressure of the fingers or of sponges, or to artery forceps.

When the anterior surface is cleared, the next step is to approach the lateral margins of the growth, and to secure the thyroid vessels. If the bronchocele is in close contact with the main vessels, some special care may be required in separating the huge internal jugular vein from the capsule. The superior thyroid artery is then sought for at the upper extremity of the tumour. The inferior thyroid artery is more deeply placed, has more numerous veins in relation with it, and is closely connected with the recurrent laryngeal nerve. No pains should be spared to expose it well.

When the whole of the lateral border of the tumour is separated, the mass is turned over towards the opposite side, and the posterior surface of the tumour cleared as far as the posterior median line.

The other lateral lobe is dealt with in precisely the same manner, and in due course the whole tumour is removed, with its capsule still unbroken.

The margins of the skin incisions are united with silkworm-gut sutures, which are not too closely applied; and a large-sized drain is introduced at the lower part of the wound.



## PARTIAL EXCISION.

Excision of one-half of the thyroid, with division of the isthmus, is conducted in precisely the same manner as the above operation.

The incision is vertical, and is placed laterally over the most prominent part of the tumour.

The front of the bronchocele is cleared, and the superior thyroid artery is then secured.

After this vessel has been dealt with, the isthmus is severed. The fascia around it is divided, and the isthmus is then separated from the trachea by an elevator or director, and is well isolated. It may be then transfixed by a needle in a handle—such as is used in ovariectomy—and secured by a double set of ligatures, which are placed upon each side of the spot at which it is intended to divide it. It is treated somewhat like the ovarian pedicle. In cases of very large isthmus more ligatures may be called for. In some instances the isthmus may be more conveniently divided with a scalpel, and ligatures applied as required.

The tumour is now almost completely isolated, and the last step consists in ligaturing the inferior thyroid artery.

## CHAPTER IV.

## EXCISION OF THE TONGUE.

EXCISION of the whole or of part of the tongue is carried out for the relief of many conditions. The great majority of the operations, however, are performed for malignant disease.

Small innocent growths of the tongue or small portions of the organ can be readily excised with the scalpel or with suitable scissors. If convenient, the edges of the wound may be brought together with sutures.

When the extreme tip of the tongue is involved, the part may be excised by a V-shaped incision, the base of the V including the tip of the organ, the apex being at the middle line, some distance from the tip.

The margins of the triangular gap thus left may be approximated by sutures.

In most cases of cancer it is better to remove the entire tongue, and in the following account that operation is described.

**Instruments required:**

1. When the operation is through the mouth—

Mason's or Coleman's mouth gag; curved needle in handle; stout waxed silk; tongue forceps; mouth retractor; tenaculum; blunt-pointed scissors, straight and curved; volsella; artery, pressure, and dissecting forceps; sponges in holders; ligatures, etc.

2. If the lingual is tied in the neck, or glands are removed—

In addition: Scalpel; retractors; blunt hooks; aneurysm needle; needles and sutures. (*See Ligation of lingual artery, page 33.*)

3. If the cheek is split—

In addition : Hare-lip pins.

4. If the jaw is divided—

In addition : Keyhole saw ; Hey's saw ; bone forceps ; bone drill ; stout wire ; wire nippers.

**Position.**—The patient lies close to the right-hand side of the table. The head and shoulders are well raised, and the arms are folded behind the back. The surgeon stands to the right and the chief assistant to the left. The gag is introduced on the left side of the mouth.

The **operations** will be considered in the following order—

1. Whitehead's operation.
2. Excision after ligature of the linguals in the neck.
3. Kocher's operation.
4. Other operations.

#### 1. WHITEHEAD'S OPERATION.

The following description is derived from Mr. Whitehead's latest account of the operation (*Brit. Med. Journal*, May 2, 1891).

A firm ligature is passed through the anterior portion of the tongue for the purpose of traction.

The first step in the operation consists in the separation of the tongue from its attachment to the floor of the mouth and the anterior pillars of the fauces. The two structures principally responsible for the retention of the tongue within the mouth are the frænum and the anterior pillars of the fauces ; and, if these are completely divided in the first instance, the tongue may be so freely drawn from the mouth that the operation is practically converted into an extra-oral incision. "Extended practice," writes Mr. Whitehead, "has made me conduct this part of the operation with less deliberation and more rapidity

than was my habit in my earlier cases. Instead of the cautious snipping I originally advocated, I now boldly cut until I get close to the vicinity of the main arteries, disregarding all bleeding, unless an artery distinctly spurts, when I twist it and proceed. The more profuse the general oozing the more rapidly I proceed, my object being to get as quickly as possible to the main arteries, as I have confidence that all subsidiary bleeding will cease immediately after their division. There is, in reality, no difficulty in determining the actual position of the lingual arteries, as they are practically invariably found in the same situation, and it requires very little experience to seize them with a pair of forceps before dividing them; if this be done there need not be the slightest hæmorrhage from this source. When once the vessels are effectually twisted, the rest of the tongue may be removed without any further anxiety about hæmorrhage. Strong, straight, blunt-ended scissors are employed.

After the tongue is removed, the floor of the mouth is washed with a solution of biniodide of mercury (1 in 1,000), is well dried, and is then painted with an antiseptic "varnish" introduced by Mr. Whitehead.

## 2. EXCISION AFTER LIGATURE OF THE LINGUALS IN THE NECK.

The lingual arteries are ligatured in the neck after the manner already described, and the incisions are closed (page 33).

After the arteries have been secured the gag is introduced and the tongue is removed with scissors in the manner already described.

The operator may ignore the trifling bleeding which takes place, and may complete the excision without let or hindrance. No time is occupied in

securing vessels, or in arresting slight hæmorrhage by sponge pressure.

No excision could be simpler or easier, nor more free from disturbing circumstances. It may, if thought desirable, be carried out with remarkable rapidity.

### 3. KOCHER'S OPERATION.

The patient having been placed in position, a preliminary tracheotomy is performed.

An ordinary cannula is employed, and the pharynx

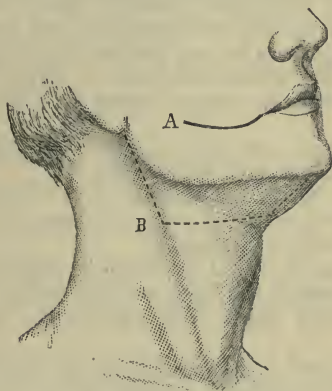


Fig. 83. - Removal of the Tongue.

A, Incision for splitting the cheek; B, Kocher's incision.

is plugged with a clean sponge, to which, as a security, a long silk thread is attached.

Chloroform is administered through the tracheal tube.

An incision is made in the neck. It commences just below the lobule of the ear, and runs along the anterior border of the sterno-mastoid muscle.

When the middle of this border of the muscle has been reached, the incision is carried forwards to the hyoid bone, and thence to the symphysis along the anterior belly of the digastric muscle (Fig. 83, B).

The flap thus marked out is turned upon the cheek.

The facial vessels are ligatured, as is also the lingual artery before it passes beneath the hyo-glossus muscle. The submaxillary fossa is now evacuated, the surgeon working from behind forwards. All the lymphatic glands of the region are removed, and also the sublingual and submaxillary salivary glands, should the diseased tissue be in near association with them. The mylo-hyoid muscle having been cut through as far as is needed, the mucous membrane is divided close to the jaw, and the tongue drawn out through the opening.

The tongue may now be slit in the middle line, and one half removed with scissors.

If the whole tongue need to be removed, the lingual artery of the opposite side must be ligatured through a separate incision.

The skin incision is not closed by sutures, but the whole wound is left open, and its cavity is plugged with gauze or with a sponge wrung out in carbolic lotion.

The wound is allowed therefore to close by granulation, while the freest possible vent is provided for the escape of all discharges.

#### 4. OTHER OPERATIONS.

##### **A. Excision after division of the lower jaw.**

The soft parts are divided in the median line by an incision which bisects the lower lip, traverses the chin, and ends at the hyoid bone. One of the lower central incisors is extracted and the jaw divided as near to the middle line as possible.

The two halves of the jaw are held asunder by assistants, while a stout silk ligature is passed through the tongue, and by means of this thread the organ is drawn well forwards and upwards.

The floor of the mouth is opened up.

The excision of the tongue is carried out with the scissors. The tissues entering the under surface of the tongue are divided in order from before backwards, and all bleeding vessels are at once secured. The operator should endeavour to ascertain the position of the lingual arteries, and each artery may be grasped with pressure forceps before the section is carried beyond the vessel.

The two halves of the jaw are wired together by a stout silver wire.

The wound is closed by sutures, and a drain is introduced into its lower angle.

#### B. **Excision after division of the cheek.**

The incision made in the cheek is a curved one, and extends from the angle of the mouth to the anterior edge of the masseter muscle (Fig. 83, A).

A straight, blunt-pointed bistoury is used in the making of the incision. While the cut is being made, an assistant grasps the tissues of the cheek above and below the line of the incision with the thumb and forefinger of each hand. In this way the bleeding, which is disposed to be very free, is controlled. All the divided vessels must be well secured before the operation is proceeded with.

The two flaps of the cheek are now held well aside, and a gag having been introduced the excision of the tongue is carried out through the large opening which has been obtained.

c. **Regnoli's operation.**—An incision is made in the median line of the neck from the lower margin of the symphysis to the centre of the hyoid bone. Two lateral incisions extend outwards from the upper

end of the median cut, and follow the lower border of the jaw as far as the anterior border of the masseter muscle. The two flaps thus marked out are dissected up. A straight bistoury is thrust from below upwards behind the symphysis, and into the mouth so that the point appears behind the incisor teeth.

The knife is then made to divide the anterior insertions of the genial, digastric and mylo-hyoid muscles, and the mucous membrane of the mouth as far back as the anterior pillars of the fauces. The tongue is now seized, and is dragged forcibly through the opening, and is then excised by means of scissors, the same precautions being observed with regard to the lingual arteries as are described in the account of the operation after division of the lower jaw.

A drain having been introduced, the wound is closed.



## CHAPTER V.

## ŒSOPHAGOTOMY.

THE operation of œsophagotomy is carried out, as a rule, for the removal of foreign bodies that have become impacted in the tube.

**Instruments required.**—Gag ; tongue forceps ; œsophageal bougie and forceps ; scalpels ; blunt-pointed bistoury ; retractors ; sharp hook ; artery and pressure forceps ; dissecting forceps ; long-bladed toothed dissecting forceps ; scissors ; needles ; needle-holder ; periosteal elevator to assist in removing the foreign body.

**The operation.**—The general features of the operation are similar to those which attend a ligature of the common carotid. (*See* page 26.) The gullet is approached from the *left* side of the neck, inasmuch as the tube inclines to that side. Should the foreign body be felt more distinctly upon the right side, then the incision may be made in that quarter.

The shoulders are well raised, the head is a little extended, and is turned to the right or opposite side.

The skin incision will commence opposite to the upper border of the thyroid cartilage, and will be continued downwards along the anterior border of the sterno-mastoid muscle for about three inches.

The first steps of the operation are identical with those for ligaturing the common carotid. (*See* page 26.)

The omo-hyoid muscle is drawn downwards, and must be divided if necessary. The sterno-hyoid and sterno-thyroid muscles must be drawn a little aside, and, in cases where the foreign body is low down, may need to undergo some division of their fibres.

The sterno-mastoid and the large vessels are drawn outwards. The carotid sheath is not disturbed.

The trachea and larynx are drawn over, or rather tilted over, to the inner or opposite side.

The position of the gullet can now be readily made out.

It may be desirable at this stage to pass a bougie or a pair of œsophageal forceps, in order to accurately demonstrate the situation of the tube, and of the impacted body.

The inferior thyroid artery and the superior and middle thyroid veins must be carefully avoided. The last-named vessels will usually need to be ligatured and divided.

All bleeding having been arrested, the gullet is steadied by a pair of fine long-bladed toothed forceps, and is opened longitudinally over the site of the foreign body.

The recurrent laryngeal nerve runs in the groove between the œsophagus and the trachea. The gullet must be opened through its lateral wall, so as to avoid injury to this nerve.

The opening in the tube must not be extended by tearing; it must be cautiously enlarged by a blunt-pointed bistoury.

The removal of the foreign body must be carried out with the greatest care, and a curved periosteal elevator will be found a most valuable instrument in freeing the substance and prising it into the wound.

If the wound in the gullet be a clean cut, if the case be recent, and the foreign body have been impacted for but a short space of time, then the œsophageal incision may be closed; and this more especially applies to the cases of children and young subjects.

If, however, the body has been long impacted, or if the wound in the gullet has been lacerated, and has been exposed to much bruising, then the use of sutures is to be avoided.

## Part VIII.

### OPERATIONS UPON THE ABDOMEN.

---

#### CHAPTER I.

##### ABDOMINAL SECTION.

THE term abdominal section is applied to the opening of the abdominal cavity either for purposes of exploration or with the object of operating upon the abdominal or pelvic viscera.

**The instruments required.**—Scalpels, dissecting forceps, straight probe-pointed bistoury, pressure forceps, large and medium-sized pressure forceps, artery forceps, straight needles; Hagedorn's needles (medium size) for the superficial sutures; two large blunt hooks, scissors (straight and curved on the flat), catgut and silk in various sizes, silkworm gut, india-rubber and glass drainage-tubes.

##### **The operation.**

1. **The parietal incision.**—The surgeon steadies the abdomen with the left hand, and makes a clean cut in the median line from two to three inches in length.

The incision is usually placed midway between the umbilicus and the pubes, and should stop always some two inches above the pubes. In fat subjects the incision will have to be a little longer. The knife should make a clean cut through the skin and subcutaneous tissues down to the aponeurosis. Bleeding is checked by pressure forceps, which are left *in situ*. There is

no linea alba below the umbilicus, and the knife need only follow the median line, avoiding the cutting of muscle as far as possible.

The transversalis fascia is now reached. It is possible to mistake it for the peritoneum, and the subperitoneal fat beyond for omentum. This fascia, and the fat, if any, beneath should be divided by a clean cut of the knife.

Before any attempt is made to open the abdominal cavity all bleeding should have been checked. The peritoneum should be pinched up as a very minute fold with a good pair of dissecting forceps. Normal peritoneum can be so picked up. Thickened and adherent peritoneum cannot be thus dealt with, nor can the wall of the bowel be so minutely picked up, should a piece of gut be exposed and its surface mistaken for the lining membrane. The forceps that grasp the little fold of peritoneum should be moved to and fro and lifted up and down, to ascertain whether the membrane is free or not. The membrane is finally divided by cutting upon or close to the point of the forceps, while they are being drawn away or lifted up.

When adhesions exist, there is difficulty in ascertaining when the abdominal cavity has been really reached, and there is nothing to guide the operator but his surgical intelligence.

The peritoneum should be divided by a clean even cut. It may conveniently be divided by scissors if preferred.

As soon as the abdomen is opened, two fingers can be introduced for purposes of exploration.

If the incision has to be enlarged, it is effected with a straight probe-pointed bistoury, the two fingers being used as a grooved director.

**2. The treatment of adhesions.**—Adhesions must be dealt with according to common surgical principles. The lighter and more slender can be

broken down by the finger or by a sponge in a holder.

The firmer must be clamped, divided, and tied—either with catgut or fine silk. Extensive strands of adhesions should be clamped in sections, cut, and the bleeding points picked up individually with artery forceps, and tied in the usual way.

Oozing from a level surface can very usually be checked by continued pressure with a sponge. Great care should be taken in dealing with deep pelvic adhesions. They can be exposed by the use of ivory spatulæ, and in demonstrating their character and attachments reflected light is very useful.

Adhesions to the bowel and to the bladder must be gently dealt with. When slender, they can be readily stripped off by means of a sponge. When dense and extensive, it is better to clamp the adhesion, to cut it through at some little distance from the viscus, and to ligature it *in situ*. In cases where a portion of cyst wall is firmly attached to the bowel, it is very undesirable to make persistent attempts to separate the two. It is far better to cut away the cyst, leaving the adherent portion still attached to the bowel. Such attached portion may be reduced to the smallest dimensions by peeling off as many laminae as possible, or by the scissors, and be allowed to remain as a permanent appendage to the gut.

It should be borne in mind, that in endeavouring to free the intestine of firm adhesions it is very much more easy to tear the bowel than to tear the false membrane.

Adherent omentum can be dealt with in considerable sections. The adhesions may be peeled off with the finger. Portions, of the thickness of the fore-finger, may be included in one ligature. It is more satisfactory, however, in dealing with omentum, to ligature the individual vessels with catgut whenever

practicable. The method adopted must depend upon the vascularity of the tissue.

Adhesions may in some cases be so dense, so close, and so extensive, that they cannot be dealt with, and may have to be left.

**3. The toilet of the peritoneum.**—In the least extensive exploratory operation some little blood must find its way into the peritoneal cavity. This should be removed. In more complicated procedures not only will much blood find its way into the pelvis and among the intestines, but a collection of pus might possibly have discharged itself during the operation, or fæcal matter might have escaped through a perforation of the bowel, or the abdominal cavity might have been flooded with the fluid from a torn cyst.

It is especially in Douglas's pouch that fluid is apt to collect. Another district is the iliac fossa, and another part that particularly encourages the accumulation of fluid is the renal region. In extensive operations where a large parietal wound has been made, these districts may be sponged out with a larger sponge held in the hand. In dealing with intestine, sponges have to be gently passed among the coils many times and in many directions before the parts can be properly cleansed.

If the wound be large enough, the cavity should be frequently inspected, in order that any visible clots may be picked up and removed.

In cases where there has been a very extensive extravasation of fluid, it may be necessary to wash out the peritoneal cavity. For this purpose boracic lotion, heated to blood heat, or a weak carbolic solution (1 in 100) of the same temperature, should be employed. Many surgeons use plain warm water, or water to which a small quantity of iodine has been added.

The assistant holds up the margins of the abdominal wound while the surgeon pours the water into the cavity. It is best poured from a common jug. Many quarts or gallons may be required. The fluid should be poured in until it escapes clear. The surgeon can assist matters by introducing his hand, or, if the wound be small, a sponge in a holder, and very gently rinsing the parts as the fluid is poured in.

As soon as the fluid poured in comes out clear, what remains may be taken up with a sponge. The patient's shoulders should be raised, so that the fluid lying among the intestines and in the hollows of the loins might drain down into the pelvis.

On completing the intra-abdominal operation, great care should be taken to ensure that no sponge or instrument has been left in the depths of the cavity.

#### 4. **The closing of the abdominal wound.**

—A thin flat sponge of greater length than the parietal wound is placed upon the intestines under the opening. It is retained during the introduction of the sutures. It serves to protect the intestines and to absorb such blood as oozes from the suture points before the sutures are tied. Various suture materials may be used. The best are No. 2 Chinese twist, or a medium-sized silk braid, or silkworm gut.

Straight needles, three inches in length, should be used. The needles must be passed through the whole thickness of the parietes, and it is especially important that they should include the peritoneum. They are most conveniently introduced in the following manner :—

A large blunt hook is inserted into each extremity or angle of the incision, and by exercising traction upon the hooks in opposite directions (precisely in the median line) the edges of the wound are rendered straight and parallel with one another. The incision opening can be made, in fact, a mere chink.

By the use of the hooks the most perfect adaptation of the edges of the wound is ensured.

If silk be used, the suture is about twenty inches in length, and a straight needle is threaded to each end of it. One needle is passed through the right-hand margin of the wound; the other through the left. Both should be passed from within outwards—*i.e.* should be made to transfix the peritoneum first and the skin last. The sutures should be introduced about a quarter of an inch from the margin of the wound, and at intervals of half to three-quarters of an inch from one another.

No suture should be tied until all the threads have been introduced, and until it is seen by traction upon the threads that a perfect adjustment of the edges can be effected.

The sutures should be tied in order from above downwards, traction being maintained all the while upon the blunt hooks. Before the last two, or possibly three, sutures are tied, the flat sponge should be seized with a pair of large pressure forceps and carefully dragged out, the blunt hooks being relaxed the while. By this means the peritoneal side of the incision is wiped dry.

Superficial sutures may now be introduced at any spot along the wound where the skin still gapes between the deep suture points. These are best introduced by a Hagedorn's needle of medium size held in the needle-holder.



## CHAPTER II.

## OVIARIOTOMY.

OVIARIOTOMY, the most frequently performed of abdominal operations, includes not only the procedure for the removal of ovarian tumours, but also of tumours of the parovarium, broad ligament, and Fallopian tubes.

**The instruments required.**—The following special instruments are required, in addition to those already enumerated as needed for the operation of abdominal section (page 359):—

Ovariotomy trocar and cannula with tubing, Nélaton's volsella (two pairs), plain volsella, pedicle needle, simple trocar.

**The operation.**

1. *The incision.*—The abdomen is opened after the manner already described. The incision should be of such a length as to enable the surgeon to extract the tumour with ease. About three inches is the average length of the skin incision when first made.

2. *The exposure and examination of the cyst.*—The cyst is exposed and is recognised by its white shining surface when free. Occasionally the peritoneum is found to be much thickened, or to be adherent to the cyst wall. In attempting to demonstrate the cyst under the latter condition, it should be remembered that to cut prematurely into the cyst is less serious than to strip the peritoneum from the parietes, under the impression that it is the wall of the cyst.

At the earliest possible opportunity the position and state of the uterus should be made out.

3. *The demonstration of adhesions.*—Assuming the

case to be a straightforward one of ovarian cyst, the tumour should be allowed to project into the wound.

The fingers or hand may be passed round the cyst to ascertain if any adhesions exist, and to estimate their character.

During such examination the lighter forms of adhesion may readily be broken down as the fingers pass gently over the surface of the growth. If firmer adhesions are found to exist, they must be left undisturbed. Adhesions of all kinds are more readily to be dealt with after the tumour has been emptied by tapping.

4. *The tapping of the cyst.*—The cyst is steadied by the surgeon's left hand while the trocar is driven into its wall. In order to bring the walls well up to the hooks on the trocar, the plain volsella may be used; or the assistant may drag the cyst wall up within the grasp of the hooks as the tumour becomes more flaccid. The volsella is apt to make holes in the cyst through which fluid may escape. Traction upon the cyst should never be made through the hooks on the trocar alone. After the first cavity has been emptied, a second, a third, and more, if necessary, may be tapped successively, without removing the cannula from its hold, merely by pushing the trocar forward and thrusting it through the septum which separates the emptied from the adjacent full cavity. In this manner the whole tumour may be emptied of its fluid contents, and its bulk so reduced that it may be drawn through the abdominal opening without undue force.

5. *The removal of the cyst.*—As soon as the part of the cyst that has been pierced by the trocar is well free of the abdominal cavity, the cyst wall may be grasped by two Nélaton's volsellæ, and traction upon the main body of the tumour made by means of these instruments.

As the cyst is drawn from without the abdomen, the chief assistant follows it, as it were, from above.

By means of two large sponges—one held in each hand—he keeps the edges of the upper part of the wound together, exercises gentle pressure upon the escaping cyst, and prevents the protrusion of any coil of intestine or of the omentum.

In the case of more solid tumours the abdominal incision must be enlarged. It is much less serious to increase the size of the wound than to run the risk of rupturing the tumour by endeavouring to drag it through too small an opening.

6. *The treatment of adhesions.*—This matter has already been dealt with (page 360).

7. *The treatment of the pedicle.*—The cyst having been drawn without the abdomen, nothing remains but to deal with the pedicle, which, in an uncomplicated case, now occupies the lower angle of the incision. In the majority of cases the pedicle is long, free, and tolerably broad. It is easily recognised by the Fallopian tube, which marks its upper or inner border.

The pedicle is secured by a ligature. It is never safe to trust to a ligature which does not transfix the pedicle, unless this be very long and slender. It should be a rule, therefore, to transfix a pedicle, and, according to its size, to tie it in two or more portions, before the cyst is cut away.

The ligatures are introduced as follows:—The assistant so holds the cyst as to display the pedicle as clearly as possible. The surgeon with his left hand will, at the same time, so hold the margin of the pedicle as to expose its full width. In his right hand the surgeon holds the pedicle needle, armed with fine whipcord. The ligature should be about three feet in length.

The needle is made to transfix the pedicle about its middle, care being taken that no blood-vessel is

damaged in the process. The loop of the ligature is drawn through and cut, and the needle removed. The pedicle is now ligatured in two sections, one including the Fallopian tube, and the other the main vessels. The less tissue should be included in the section bearing the blood-vessels. The knot tied should be a double reef or surgeon's knot, and the threads should be drawn as tightly as possible.

The threads must be cut short, and the pedicle divided with scissors three-quarters of an inch beyond the line of the ligatures.

In examples of very broad pedicle the tissues may have to be ligatured in three or more sections.

8. *The completion of the operation.*—All bleeding having been arrested, the opposite ovary may be examined.

The peritoneum is now well sponged and cleansed in the manner already described. The stump of the pedicle should be drawn up and examined. Sponges should be counted, and the greatest care taken that no sponge or instrument has been left within the abdominal cavity.

Nothing now remains but to close the abdominal wound after the method described in the previous chapter.

## CHAPTER III.

## REMOVAL OF THE UTERINE APPENDAGES.

THE operation conveniently described by this name has been defined as "the removal of one or both of the uterine appendages for any reason excepting the extirpation of what is generally known as an ovarian tumour."

It is known also as "normal ovariectomy," as "Battey's operation," and as "oöphorectomy."

**The instruments required.**—The same as for ovariectomy with the exception of the trocar, the volsella, and the cyst forceps. Two long ivory spatulæ (paper-knives) may be found to be of use.

**The operation.**—The patient having been prepared for abdominal section, a vertical incision about two and a half inches in length is made over the linea alba below the umbilicus. The centre of the cut will be nearer to the symphysis than to the umbilicus.

The cavity of the peritoneum is opened in the manner already described.

All bleeding having been checked, two fingers are introduced into the wound, and the fundus uteri is sought for. The fingers embrace the broad ligament as if they were the blades of very long dressing forceps, and are carried outwards—one on each side of the Fallopian tube—until they are arrested by the ovary.

The ovary is now drawn out of the abdomen by the two fingers, which retain the same forceps-blade attitude.

In the simplest cases the fingers of the left hand may be used to draw forth the ovary, and between these fingers the parts to be removed may be held

while the surgeon applies the ligature with the right hand.

It often happens, even when no adhesions exist, that there is some difficulty in dragging the ovary well out of the wound. In such instances it is necessary that the appendages should be seized by large-elbowed pressure forceps.

The ligature is applied by means of a blunt-pointed needle in a handle, which is made to transfix the pedicle. The pedicle in this operation is secured in precisely the same way as in ovariectomy.

The parts are cut away close to the retaining fingers or the retaining forceps, and at least a third of an inch from the ligature.

The appendages of the opposite side are sought for and dealt with in the same manner.

The surface of the peritoneum is freed of any blood by means of a small sponge in a holder.

The wound is closed in the usual way.

As a result of adhesions, the anatomy of the part may be greatly confused, and a condition be induced which is at first peculiarly puzzling. The appendages may be bound down by adhesions, or be lost in a confused mass of cicatricial tissue. It may be impossible to identify the ovary by the touch. The surgeon may be quite unable to demonstrate any kind of pedicle. The structures to be removed may be adherent to the bowel, or to the bladder, or to the peritoneum lining the floor of the pelvis. They may be the seat of abscess or of some variety of cystic formation, and the removal of the diseased parts without rupturing the abscess wall may be attended with the greatest difficulty.

## CHAPTER IV.

## HYSTERECTOMY.

HYSTERECTOMY, or removal of the uterus, is carried out for myoma, for incurable inversion, and for malignant disease.

The following *operations* will now be described :—

1. Supravaginal hysterectomy for myoma.
  - A. With extraperitoneal treatment of the pedicle.
  - B. With intraperitoneal treatment of the pedicle.
2. Vaginal hysterectomy for cancer.

## 1. SUPRAVAGINAL HYSTERECTOMY FOR MYOMA.

**The instruments required.**—The same as for ovariectomy, with the exception that the trocar and cannula will be replaced by some form of *serre-nœud*. A strong elastic ligature, or very stout whipcord, will also be required, and likewise certain special pins.

**A. Hysterectomy with extraperitoneal treatment of the pedicle.**—The abdomen is opened in the median line, as in ovariectomy.

The hand is introduced into the abdomen, and the tumour and its relations investigated. The abdominal wound is enlarged to the extent necessary to remove the mass with readiness.

Adhesions must be dealt with as their circumstances require.

The tumour is pulled forward out of the wound.

As it is delivered, the exposed viscera should be protected by warm sponges.

It behoves the surgeon now to carefully examine the lower part of the mass, in order to make sure of its relations to the uninvolved portion of the uterus, to the appendages, to the cervix, and to the bladder.

The wire of Koeberlé's, or other *serre-nœud*, is passed round the pedicle. The pedicle is simply the lower part of the uterus, or the upper part of the cervix. Whenever possible, the wire loop should surround the pedicle a little above the level of the *os internum*.

If an appendage be placed too low to be included in the loop, it should be removed, and its pedicle ligatured separately.

Before passing the wire round the tumour, the position of the bladder must be ascertained, and, if necessary, demonstrated by means of a catheter.

The wire loop is tightened gradually. Two pins are then passed through the pedicle, close to the loop, and upon its distal side. They are introduced transversely, *i.e.* at right angles to the line of the wound in the parietes.

The tumour is now cut away beyond the pins, the wire is still further tightened, the abdominal and pelvic cavities are cleared of all coagula, and the area of the operation thoroughly cleansed.

The stump of the pedicle is trimmed up, and reduced to its smallest limits. It is well drawn towards the lower angle of the abdominal wound, which is then closed in the usual way. The pins and the wire loop are without the abdomen.

The wound and the stump of the pedicle are freely dusted with iodoform or some other suitable powder, and the part dressed according to the custom of the individual operator.



**B. Hysterectomy with intraperitoneal treatment of the pedicle.**

*The instruments required.*—The instruments required in hysterectomy have already been enumerated (page 371).

In this method of performing the excision no *serre-nœud* or clamp is needed. Some means, however, must be adopted for securing the pedicle temporarily. This may be effected by an elastic ligature or a ligature of stout cord. A convenient instrument is a large old-fashioned *écraseur* carrying a strand of stout whipcord. The loop of the instrument can be gently tightened and made to act as a temporary compressor.

*The operation.*—1. The abdomen is opened in the median line, and the tumour is exposed. Any adhesions encountered are dealt with. The relations of the mass are investigated, and the possibility of forming a convenient pedicle is considered. Provided that the case admit of it, the growth is delivered, is drawn out of the abdomen, and is lifted vertically upwards by one or more assistants.

2. The next step is to secure the arteries that supply the myoma. These vessels are two in number on each side—the ovarian and the uterine. Their position can be ascertained without difficulty, and they are subject to very little anatomical variation.

The ovarian vessels are defined in the broad ligament, are secured between two sets of ligatures, and divided. The surgeon proceeds to sever the broad ligament—when that structure is still present as a ligament—in a direction that would correspond to a line roughly drawn from the brim of the pelvis to the cervix uteri. It is throughout divided between two sets of ligatures. The veins of the pampiniform plexus are apt to be very voluminous, and may be as large as, or larger than, the thumb. The round

ligament will need to be severed between ligatures. In due course the broad ligament upon either side will have been divided nearly to the uterus, and all the vessels belonging to the ovarian set will have been secured.

3. The uterine artery has now to be secured close to the neck of the uterus. It is best picked up by a large aneurysm needle, which is passed (unthreaded) close to the cervix and then threaded and withdrawn, leaving the ligature in place. In this manœuvre very great care must be taken not to damage the ureter.

When these two arteries have been secured, there remains no known vessel to supply the growth.

4. As a precaution an elastic or cord ligature may be passed around the pedicle before it is divided.

The upper part of the pedicle—about the level of the internal os—is now severed with the scalpel.

The part is so cut as to leave a V-shaped surface; the apex of the V will be in the centre of the divided cervix, and will correspond to its divided canal.

If a temporary ligature be used, the stump must be grasped with volsella before the division is complete. If this be not done, it will slip from the grasp of the ligature.

Blood runs freely from the great tumour, but it is blood which is no longer circulating.

If the vessels have been properly secured, the face of the stump is pale, and the oozing from it is quite inconsiderable, and not comparable to such as may take place from a surface from which thick adhesions have been stripped.

5. The mucous membrane of the divided canal should now be united by a continuous catgut suture.

The divided surfaces of the cervix—the surfaces of the V—are brought together with deep catgut

sutures, which take a good grasp of the tissues. The raw surface is in this way closed in. Finally, the peritoneum covering the part is, if possible, brought together by fine sutures, so as to cover the seam left on the stump.

6. Nothing remains but to unite, as far as is possible, the breaches made in the peritoneum upon each side of the stump. Each breach will follow the line of the broad ligament. The pelvic cavity is carefully cleansed, and the abdominal wound is closed.

## 2. VAGINAL HYSTERECTOMY FOR CANCER.

**The instruments required:**—Clover's crutch; Higginson's syringe; Sims's speculum; volsellæ; scalpels; small sponges in holders; two pairs of long-handled scissors curved on the flat; pressure forceps; broad metal retractor; pedicle needle; needle-holder; needles; ligatures; drainage-tube.

**The operation.**—The following is founded upon Doran's description:—The patient is placed in lithotomy position, and the lower limbs are separated by a Clover's crutch. The buttocks are brought close to the edge of the table. The surgeon sits facing the perineum.

A Sims's speculum is passed along the posterior vaginal wall. The anterior lip is seized by a volsella, and the uterus is drawn down as far as possible.

1. The assistant now takes charge of the volsella, and pulls the cervix backwards and downwards. The surgeon then cuts through the vaginal mucous membrane along its anterior reflection on to the cervix by means of the scissors.

A catheter is passed into the bladder. The anterior part of the uterus is then cut away, with scissors, from its cellular connections with the bladder. The blades of the instrument must be kept close to

the uterus. The peritoneum should not be opened at this stage.

The speculum is now removed, and the cervix completely separated from the vaginal mucous membrane. To effect this the cervix is drawn forwards, so as to bring its posterior aspect into view. The mucous membrane along its posterior reflection on to the cervix is divided with the scissors. This semi-circular incision forms, with the one already made in front, a complete ring around the cervix.

2. The cervix being thus detached, Douglas's pouch is now opened up. Care must be taken not to cut too much laterally, lest the broad ligaments be wounded.

At this stage the uterus will remain connected to the surrounding parts by the broad ligaments and the utero-vesical fold of peritoneum. This fold is at once divided.

In order to do so, the operator slips his left forefinger through the hole in Douglas's pouch over the fundus and front of the body of the uterus, till the point of the finger presses on the reflection of peritoneum from the bladder on to the uterus.

The peritoneum is then divided with scalpel or scissors, the operator cutting close to the uterus, and the finger behind the peritoneum serving as a guide. The catheter should remain in the bladder during this stage.

The broad ligaments now alone remain.

3. In order to secure the broad ligaments, the fundus is pulled through the posterior part of the wound with the aid of a strong volsella. This forcible retroflexion is never easy to effect. The right hand should be pressed on the hypogastrium, whilst the left forefinger is passed through the posterior part of the wound and hooked over the fundus.

When the body of the uterus is pulled down into

the wound, the operator must grasp it with the volsella.

The most dangerous stage of the operation is now reached. It is desirable that the ovaries and tubes should, if possible, be removed entire; but this cannot, as a rule, be accomplished.

The surgeon will usually have to satisfy himself with dividing the ligament on the uterine side of the ovary.

The ligament is secured by ligatures and then cut. The difficulties of even this step will be at once appreciated. The structures to be transfixed can never be brought well into view, and it is scarcely possible to relax the ligament sufficiently while the loop is being tied.

The usual procedure—that, namely, of dividing the broad ligaments upon the uterine side of the ovary—will now be described.

A pair of large straight-bladed pressure forceps is made to grasp the broad ligament close to the uterus. A strongly-curved pedicle needle armed with silk transfixes the broad ligament from behind, external to the forceps. The ligature is then secured as in ovariectomy. As the ends of the thread are being pulled tight the assistant must remove the large pressure forceps. The ends of the other thread are then tied round the opposite side of the broad ligament.

The broad ligament is now cut through between the ligature and the uterus. The ends of the ligature should be left uncut till the vaginal wound has been attended to later. The uterus is then drawn to the ligatured side, and the opposite broad ligament is secured in the same manner.

When the ovary and the fimbriated end of the Fallopian tube are removed, the process will be far more difficult.

The ligature is very hard to apply; the tissues transfixed are upon the stretch, and the possibility of the knot slipping after it has been tied is considerable.

4. The uterus now comes away. Any remaining bleeding points must be secured by ligature.

The vaginal wound may be closed by sutures, which are inserted with a curved needle held in a needle-holder.

Some surgeons leave the vaginal wound open, and trust to packing of the vagina to prevent the prolapse of bowel or omentum through the rent.

Drainage is advisable in most cases. The simplest form of tube is a long glass drainage-tube, which is passed about half an inch beyond the vaginal wound. The vagina is then packed with iodoform wool.

## CHAPTER V.

## SUTURE AND RESECTION OF INTESTINE.

## SUTURE OF THE INTESTINE.

**The qualifications of a good suture.**—An efficient intestinal suture should have the following qualifications:—

1. It should bring into contact two broad surfaces of peritoneum, these surfaces belonging respectively to the bowel above and below the breach to be closed.




Fig. 84.—Dupuytren's Suture.

2. It should effect a complete closure of the wound, the test being that the seam should be water-tight.

3. The mucous membrane should be excluded.

4. The suture should not strangulate the free margin of the intestine with which it is concerned.

5. The suture should not pass through both the mucous and the serous coats. Such a suture—especially when made of silk—would tend to act as a seton, and be apt to conduct the intestinal fluids to the outer surface of the bowel by means of capillary attraction.

6. The suture should be simple, easily introduced, and capable of effecting a rapid closure of the wound.

7. The thread should take so firm a hold of the tissues that there is no danger of its "cutting out" when strain is put upon it, as may be the case if the viscus become distended.

The two chief forms of intestinal suture will now be considered.

**A. The continuous suture.**

*Dupuytren's method.*—The edges of the wound are

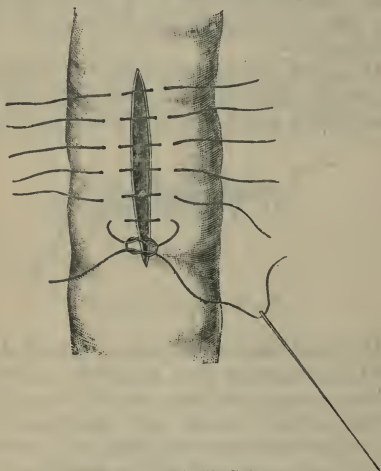


Fig. 85.—Lembert's Suture.

turned inwards, and the opposed folds of serous membrane are then brought together by means of the ordinary continuous suture (Fig. 84). The suture does not involve the mucous membrane. This suture may be very rapidly applied.

**B. The interrupted suture.**

1. *Lembert's suture.*—The needle is passed



transversely to the line of the wound, and at right angles to the axis of the bowel.

A fold is picked up upon one side of the wound; the needle is then carried over to the corresponding spot on the other side of the wound, where a precisely similar fold is picked up (Fig. 85). The margins of the wound are turned in, and the serous coats are brought into close contact (Fig. 86). The needle should pick up more than the serous coat; it should

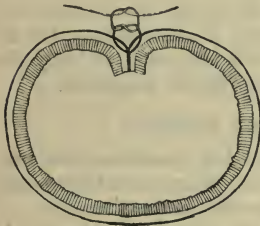


Fig. 86.—Lembert's Suture.

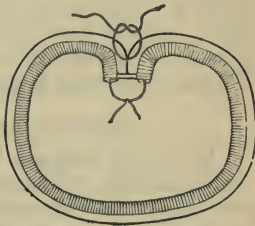


Fig. 87.—Czerny-Lembert's Suture.

include a part or the whole of the muscular coat also. It must on no account trespass beyond the limits of the latter tunic (Fig. 86).

The width of the fold picked up will be from one-tenth to one-twelfth of an inch. The inner row of needle points will be from one-twelfth of an inch to one-eighth of an inch from the edge of the wound. In very small and simple wounds of the intestine the needle may be brought out nearer to the free border of the gap to be closed. The amount of tissue picked up, *i.e.* the width of the fold, will depend upon the thickness of the tissues involved, the amount of strain likely to be brought upon the sutures, and the character of the breach to be closed.

The closeness of the sutures to one another must

vary somewhat according to circumstances. They may be usually estimated at about ten to the inch. It will rarely be safe to apply them less closely than this.

The extremities of each suture are knotted together and the ends cut short. The knots need not be tied with the utmost degree of tightness.

2. *Czerny's suture*.—This is a Lembert's suture with the addition of an inner row of interrupted sutures which unite the mucous membrane only (Fig. 87). The knots of this inner row are turned inwards. The ends of the inner suture are cut short, and the row of knots is inverted as far as possible. The row of knots is then covered in by the muscular coat when Lembert's suture is applied.

#### RESECTION OF THE INTESTINE.

Under this title are included operations that concern themselves in the removal of comparatively small portions of either the small or the large intestine.

Excision, when applied to the lesser bowel is termed enterectomy, and when carried out in the colon, colectomy.

The details of the **operation** will be considered under the following headings:—

1. Enterectomy with circular suturing of the divided ends.
2. Enterectomy with the establishment of an artificial anus.
3. Senn's operation.
4. Removal of the vermiform appendix.

#### 1. ENTERECTOMY WITH CIRCULAR SUTURING OF THE DIVIDED ENDS.

1. The abdomen having been opened, the first step is to isolate the loop of intestine to be excised. This loop should be drawn well out of the parietal wound.

The part to be resected is placed upon a thin Turkey sponge, and the whole wound through which the intestine has been drawn is well and carefully packed all round with fine sponges.

2. The bowel must be occluded above and below the resection area.

A simple clamp, such as Makin's clamp, or the fingers of an assistant, are made use of for this purpose.

3. The portion of diseased bowel is now excised. This is effected with blunt-pointed scissors. The cut must be made about three-fourths of an inch beyond the margin of the clamp.

The scissors cut their way from the free border towards the mesentery.

In most instances the best method of treating the mesentery consists in excising a triangular portion of the membrane together with the gut to be removed. The base of the triangle will be at the intestine, but will be narrower than the length of bowel removed. The margins of the wound in the mesentery are then carefully brought together by a continuous suture.

4. The divided ends of the bowel are thoroughly well cleansed, and all soiled sponges are removed and replaced by fresh ones.

The sutures may now be applied. If it is intended to introduce a double row, then the surgeon proceeds at once to unite the margins of the divided mucous membrane.

The surface sutures will be applied according to Lembert's method, and in the manner already described (page 380).

The clamps are removed, and the sutured loop is allowed to drop back into the abdomen. The abdominal wound is then closed.

## 2. ENTERECTOMY WITH THE ESTABLISHMENT OF AN ARTIFICIAL ANUS.

The early steps of the operation are precisely the same as in the procedure just described.

The removal of a triangular piece of the mesentery facilitates the subsequent operation for the closure of the artificial anus. The gap left in the mesentery should be united by suture, as already described.

After the excision has been carried out, the wound in the parietes is so far closed as to leave only a gap through which the divided ends of the gut project. The two sections of bowel—still clamped—should be brought together by their mesenteric borders, and are united by a few points of suture.


The lower end of the divided bowel is now rapidly united to the parietes. The margin of the bowel is secured all round to the margin of the parietal wound. The serous covering of the intestine must be brought into contact with the serous lining of the abdominal wall. The sutures can be most conveniently passed by means of a large curved Hagedorn's needle.

The main sutures may be passed before the clamp is removed, and may be drawn tight and secured when the clamp is withdrawn.

The upper end of the bowel is dealt with in the same way. Every preparation must be made for a rush of fæcal matter as soon as the upper clamp is removed. The main sutures will be in place before the clamp is withdrawn.

## 3. RESECTION OF INTESTINE BY SENN'S METHOD.

The ends of the divided bowel are entirely and permanently closed, and the continuity of the intestinal canal is then restored by means of "intestinal anastomosis by lateral approximation," bone plates being used.

This procedure is illustrated at page 387. 

## THE REMOVAL OF THE VERMIFORM APPENDIX.

Diseased conditions of the appendix are of very common occurrence, and it would be out of place here to detail the conditions under which an excision of the appendix may be carried out.

**The operation.**—The chief points in connection with the operation itself are the following:—

1. Before the operation the position of the diseased appendix should be made out, if possible. Its position might have been indicated during one of the attacks of typhlitis.

2. The incision should be made obliquely from above downwards and inwards over the cæcal region, its lower extremity ending just external to the epigastric artery. It is, as a rule, most conveniently placed about two fingers' breadth internal to the anterior superior spine of the ilium. The incision should not be always made directly over the appendix or over the dullest region. If it be so placed, a number of adhesions will probably be encountered, and the demonstration of the peritoneal cavity might be difficult. The cæcum or the appendix might be actually adherent to the anterior abdominal wall. The incising of the peritoneum should, therefore, be conducted with the very greatest care. It is well that the parietal cut should open the abdomen at a point just beyond the diseased area, where no adhesions exist.

3. When the appendix and cæcum are exposed, the area of the operation should be cut off from the general abdominal cavity by sponges.

4. All adhesions should be divided by cutting; none should be "broken down." The latter measure is apt to tear the bowel—or, at least, to bare it of peritoneum.

5. The appendix should be lightly clamped close to the cæcum and be divided about half an inch

from that intestine. The mucous membrane should be united by a continuous suture; then the divided outer walls of the process should be brought together by a second row of sutures.

6. The abdominal wound should be closed; no drain is required.

*During the progress of the operation* any adhesions likely to give rise to future trouble might be dealt with; this more especially applies to adherent omentum, or to adhesions binding down coils of small intestine. If the appendix be closely adherent to the ureter, or to a coil of the ileum, or be found deeply attached in the pelvis, its removal may be attended with very considerable difficulties.

## CHAPTER VI.

## INTESTINAL ANASTOMOSIS.

By intestinal anastomosis is understood the establishment of a permanent fistulous communication between the intestine above and the intestine below the seat of some more or less permanent obstruction.

The general procedure may be illustrated by a case of malignant stricture at the junction of the jejunum and ileum. Some obstruction has been produced. It is not considered advisable to excise the diseased segment. To overcome the occlusion, a loop of the lower part of the jejunum is brought to a loop of the upper ileum, and a permanent opening is established between the two.

The segment of bowel which is the seat of disease is thus excluded from the intestinal canal, and the intestinal stream is diverted into a new channel.

This anastomosis can be effected by direct suturing of the bowel (*see* page 379), or it may be performed by the use of bone plates as advocated by Dr. Senn.

**Dr. Senn's method.**—The bone plates are made of decalcified bone from an ox's tibia, and measure two and a half to three inches in length by one inch in width. They are perforated in the centre, and are sold with the sutures attached, as shown in Fig. 88. The sutures threaded upon needles are called the lateral or fixation sutures (Fig. 88, A). Those which end in free knots are called the end or apposition sutures (Fig. 88, B).

1. *Incision of the bowel.*—A loop of the bowel below the obstruction, and another loop above the obstruction, are brought into the wound.

The loops that are to be brought together by anastomosis must be emptied of their contents by drawing the fingers along them, and must be kept

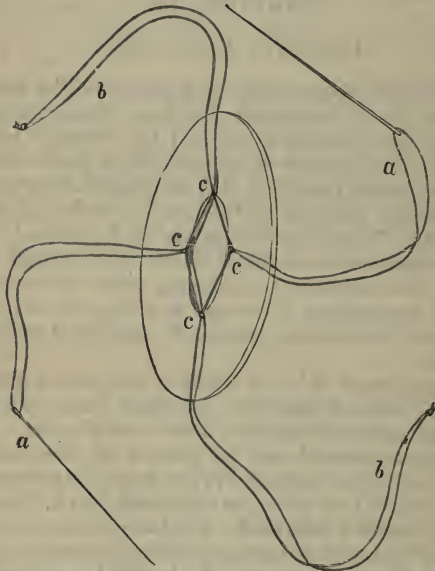


Fig. 88.—Senn's Bone Plate with the Sutures in Position.  
*a a*, Lateral or fixation sutures; *b b*, end or apposition sutures; *c c*, perforations in the plate.

empty—either by digital compression, or by being constricted with indiarubber bands.

An incision is made in the long axis of the bowel, upon its convex or free side, and therefore along a line opposite to the attachment of the mesentery.

The cut must be large enough to admit a bone plate readily without using any force.



2. *Insertion and fixation of the plates.*—The plate is inserted edgewise, and when it is completely in the

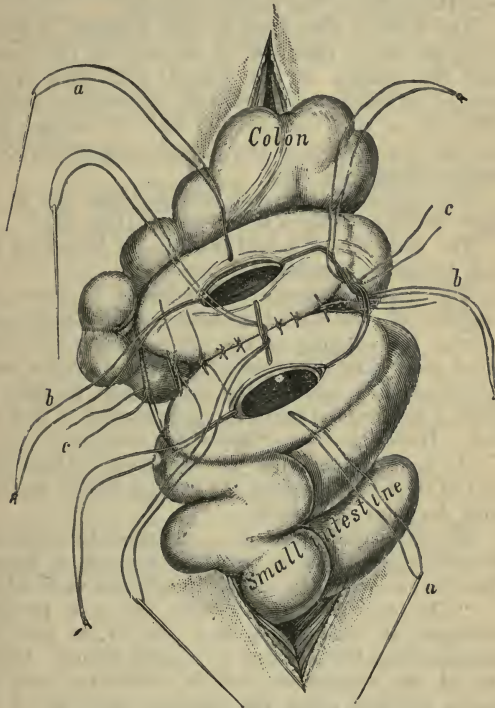


Fig. 89.—Intestinal Anastomosis with Bone Plates.

*a a*, Lateral or fixation sutures; *b b*, end or apposition sutures; *c c*, posterior sutures. (*Seinn.*)

lumen of the bowel, traction is made on the sutures in such a manner that the disc makes half a turn, so

that its upper surface faces the wound. It is now accurately adjusted, so that its ends are equidistant from the angles of the visceral wound.

The plate is then fixed in this position by transfixing the entire thickness of the wall of the bowel, near the margin of the wound, with each of the needles attached to the lateral or fixation sutures (Fig. 88, *a a*). One needle will, of course, pass through one margin of the wound, and the opposite needle through the other.

The apposition or end sutures hang out of the upper and lower angles of the wound (Fig. 89).

The two coils of bowel that are to be united are each treated in precisely the same way.

The lateral sutures are intended to draw the margins of the wound asunder after tying, and prevent the slipping of the plates. They are hence called also "fixation sutures." The end sutures serve to retract the angles of the wound, and to assist in holding the coapted parts in apposition after they are tied. Hence the name "apposition sutures."

3. *Approximation of the intestines.*—The serous coat of the bowel covering the plate is lightly scarified with the point of a needle.

The intestines which it is intended to unite are brought together by an assistant in such a manner that the two wounds are exactly opposite each other.

"The approximation sutures are now properly arranged, so that when they are to be tied, the corresponding threads can be readily found. Before any of the sutures are tied, it is well to unite the serous surfaces along the posterior margins of the plates with a few superficial sutures (Fig. 89, *c*).

"After this has been done, the posterior pair of fixation sutures is tied with sufficient firmness to approximate, but not to compress, the parts between them. Next the pair of end or approximation sutures

away from the operator is tied, and when this has been done the opposite pair is tied (Fig. 89). All the sutures are cut short as soon as they are tied. The last sutures to be tied are the remaining pair of fixation sutures; and while these are being tightened, the margins of the bowel are inverted between the plates with a director or probe. The cut ends of the last knot are pushed with a probe towards the opening.

“Approximation has now been completed, and all that is left is to reinforce the action of the plates by suturing the serous surfaces over the anterior margins of the plates by a few stitches of the continued suture” (*Senn*).

The parts are well and carefully washed and cleansed, and the rubber bands or clamps are removed.

The loop is replaced in the abdomen.

The wound in the abdomen is closed by sutures.

**Varieties of the operation.**—1. *Gastro-enterostomy*. (See chapter ix. upon the Operations on the stomach, page 408.)

2. *Jejuno-ileostomy*.—The union is effected between the jejunum and ileum.

3. *Ileo-colostomy*.—Union of the ileum with the colon. This is especially called for in obstructive conditions involving the ileo-cæcal region.

## CHAPTER VII.

## ENTEROTOMY.

THE term enterotomy is applied to an operation that is carried out in cases of intestinal obstruction, and which consists in opening the distended bowel above the seat of the occlusion and allowing its contents to escape. This involves of course an abdominal section.

The procedure is sometimes known as "Nélaton's operation." It is assumed that the loop of bowel which is opened will belong to the small intestine, and in the majority of instances this proves to be the case. It will be obvious that the term enterostomy would more precisely represent this operation than the term enterotomy, which would imply the mere cutting into the bowel, as in the removal of an impacted gall-stone.

**The operation.**—The abdomen is opened in the right iliac region—if Nélaton's method be strictly followed—by an incision parallel to and a little above the outer part of Poupart's ligament.

The incision is placed to the outer side of the epigastric artery, and its length must depend upon the thickness of the parietes. One inch and a half to three inches will represent the extremes.

As soon as the abdomen is opened, the first distended coil of intestine that presents is seized and drawn into the wound. It will probably belong to the lower ileum.

The convex part of the distended knuckle is drawn well into the parietal wound, but the convex or free border should alone project.

The wound in the abdominal parietes is now partly closed by means of silkworm-gut sutures.

The bowel will occupy the centre of the wound.

The sutures must include all the tissues forming the parietes, together with the peritoneum.

The latter membrane should be brought as near to the cut margin of the skin as is possible.

The wall of the bowel is now rapidly stitched to the margin of the skin, which tightly surrounds it on all sides. Very fine silk, passed by means of a small curved needle held in a holder, is best adapted for this purpose. The stitches should involve the skin and the serous and muscular coats of the bowel. Care should be taken not to open the actual lumen of the gut with the needle.

The gut is now opened by a small puncture.

The small sutures that connect the gut wall with the skin are for the purpose of shutting off the peritoneal cavity. They would not suffice probably to hold the intestine safely in position.

To effect this latter object two lateral sutures of silkworm gut should be introduced, and should transfix the whole thickness of the intestinal wall, and take a firm hold of the integuments.

These sutures should be passed from without inwards, *i.e.* from the skin towards the gut. If passed in the opposite direction, they may carry faecal matter into the tissues.

The opening into the bowel should always be small, and should be upon the free or convex border.

The smaller the knuckle of intestine brought into the wound, and the smaller the fistula, the easier will be any subsequent operation for the closure of the artificial opening.

The incision may be as conveniently made in the median line below the umbilicus.

If the symptoms be not urgent, the operation may

be performed *à deux temps*. The abdomen is opened and the bowel is fixed in place, but its lumen is in no way invaded. After an interval varying from a few hours to three days, the operation is completed by incising the gut and allowing its contents to escape.

## CHAPTER VIII

## COLOTOMY.

By colotomy is understood the operation of establishing an artificial anus in the colon. This may be either temporary or permanent. But for the fact that the term colotomy has become firmly engrafted in the language of medicine, the more precise term colostomy might be advised.

*Lumbar colotomy* implies the opening of the ascending or descending colon through the loin without wounding the peritoneum. This is known also as the extraperitoneal operation, as posterior colotomy, or the operation of Amussat and Callisen.

*Iliac colotomy* implies the opening of the sigmoid flexure, or the cæcum, through an incision in the iliac region which involves the peritoneal cavity. This is known as the intraperitoneal operation, as anterior colotomy, as Littré's operation, as laparo-colotomy, and as inguinal colotomy.

## LUMBAR COLOTOMY.

**Instruments required.**—Scalpels ; straight and curved scissors ; dissecting, pressure, and artery forceps ; tongue forceps to hold the gut ; broad rectangular retractors ; curved needles in handles (right and left) ; Hagedorn's needles, of various sizes, and needle-holders ; catgut ; silkworm gut ; blunt hooks.

**Position.**—The patient should lie upon the sound side and close to the edge of the table. A small hard pillow or sand-bag is placed under the opposite loin, so that the region to be operated upon may be brought well into view, and the space between the crest of the

ilium and the last rib be extended to the utmost (Fig. 90). The surgeon stands upon the side to be operated upon.

**Operation.**—The position of the ascending or descending colon in the loin may be approximately represented by a vertical line drawn upwards to the last rib from a point about half an inch posterior to

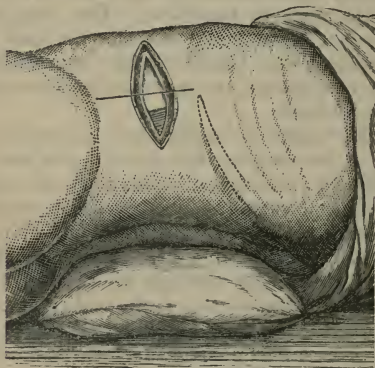


Fig. 90.—Incision in Lumbar Colotomy. (The quadratus lumborum muscle is exposed.)

the centre of the crest of the ilium. The centre of the crest will be indicated by a point midway between the anterior superior and posterior superior iliac spines.

*First stage.*—The incision should be from three to three and a half inches in length. It is placed obliquely, midway between the last rib and the iliac crest. Its centre should correspond to the centre of the line marking the site of the bowel (Fig. 90). It will be about parallel to the last rib, or will follow a line drawn from the anterior superior spine to the



angle between the twelfth rib and the mass of the erector spinæ muscle.

The length of the incision will be mainly influenced by the thickness of the tissues, and this for the most part will depend upon the degree of corpulency.

After the skin and superficial structures have been divided, the external oblique and latissimus dorsi muscles will be exposed. They should be divided by a single clean cut through the whole length of the incision.

The internal oblique will next come into view. This muscle is also cleanly divided through the whole length of the original wound. In the posterior part of the wound the fascia lumborum will probably be seen.

There are now exposed a few of the hindermost fibres of the transversalis muscle, which are nearly transverse in direction, and the fascia lumborum. If the incisions have been made as described, the actual amount of muscle tissue exposed in the depths of the wound will be slight.

The muscle and the fascia are now divided to the full length of the wound.

In the posterior part of the incision the clear anterior border of the quadratus lumborum will be seen (Fig. 90). The fibres of that muscle seldom, if ever, need to be divided. Broad rectangular retractors will be found very useful at this stage of the operation.

The transversalis fascia must be sought for and demonstrated, and cleanly divided.

The subperitoneal fat is now reached, and the first stage of the operation is completed.

*Second stage.*—The gut is now sought for. When great distension of the abdomen exists, the colon very frequently bulges at once into the wound as soon as the tissues around it have been freed by the finger.

Failing such an appearance, the forefinger is

introduced into the subperitoneal tissue and the colon is sought for. The finger follows the anterior surface of the quadratus lumborum, and seeks for the angle which exists between this muscle and the psoas.

It is towards this angle that the non-peritoneal surface of the colon faces in cases where no meso-colon exists. In seeking for this part the lower end of the kidney will be felt, and it must be remembered that the bowel lies on a plane anterior to it.

It is essential that the subperitoneal fat be well opened up with the examining finger or fingers, and that it be further separated by means of two pairs of dissecting forceps. The exposure of the non-distended bowel is impossible unless this be done.

The colon, when brought into view, may be identified by the thickness of its coats, by its non-peritoneal surface, and possibly by the existence of a longitudinal band.

When a distinct meso-colon exists, and the colon is empty, the peritoneal cavity must almost of necessity be opened up and a loop of the intestine drawn through.

*Third stage.*—The bowel is fixed in position and opened.

It should be merely drawn to the level of the skin. It should not be dragged out as a loop or knuckle.

By means of a large curved Hagedorn's needle the two extremities of the parietal wound are closed by sutures. Silkworm gut should be employed, and the needles should be passed very deeply, so as to include all the divided structures down to the fascia lumborum.

When they are tied, the skin should very closely embrace the small dome of protruding bowel which presents in the centre of the incision.

By means of a small curved Hagedorn's needle the skin is in the next place united all round to the

intestine by many points of suture. The needle should only concern the skin on the one hand, and the muscular coat of the bowel on the other. The lumen of the gut should on no account be penetrated.

Finally, an opening is made into the bowel by means of a small scalpel.

By means of a curved Hagedorn's needle of medium size, or a curved needle in a handle, the final sutures are introduced. They concern the whole thickness of the coats of the bowel on the one hand and the skin on the other. Silkworm gut should be the material employed.

The needle is introduced through the skin, and its point is made to appear in the interior of the bowel. A fresh needle and a fresh thread are employed for each suture.

*Colotomy à deux temps.*—When the symptoms are not urgent, the operation may be carried out in two stages. The bowel is sought for, and is fixed to the skin by numerous superficial sutures precisely in the manner described. The part is well dusted with iodoform, and after an interval of some hours, or some days, the operation is completed by opening the colon.

*The closure of the lower end of the colon.*—In cases in which a permanent artificial anus has been established, fæces may collect between the fistula and the seat of the stricture, and severe symptoms, identical with those of intestinal obstruction, may be produced.

To prevent the passage of fæces into the lower segment of the colon the lower end of the bowel may be closed.

#### ILIAC COLOTOMY.

**Instruments required.**—Scalpels; blunt-pointed bistoury; scissors; pressure, dissecting, and artery forceps; blunt hooks; rectangular retractors;

straight and curved needles ; needle-holder ; sutures, etc.

**Position and general arrangements,** as for abdominal section.

**The operation.**—The following description of the operation is founded upon that given by Mr. Harrison Cripps :—As a guide, take an imaginary line from the anterior superior spine to the umbilicus ; the incision, two and a half inches long, crosses this at right angles, one inch and a half from the superior spine. Half the cut is above and half below the line. The peritoneum having been opened, the colon may now at once show itself.

The colon being found, a loop of it from the highest available part of the gut is drawn into the wound. Two provisional ligatures of stout silk are now passed through the longitudinal muscular band opposite the mesenteric attachment.

With a pair of fine forceps the parietal peritoneum is picked up and attached to the skin on each side of the incision, the muscular coats of the abdominal wall not being included. Four sutures are sufficient, two on each side.

The bowel is now fixed to the skin and parietal peritoneum by seven or eight fine ligatures on each side. By turning the bowel slightly over, the lower longitudinal band can be clearly seen, and it is best to pass the sutures for the lower side through this, since it is a strong portion of the gut. The upper longitudinal band, through which the provisional ligatures have already been passed, is seen in the middle line of the wound. The bowel being now turned downwards, the opposite line of sutures are inserted close to its mesenteric attachment.

If the case be urgent, the bowel may now be opened ; if not, the opening may be left for some days. The provisional ligatures form a guide to the gut.

## CHAPTER IX.

## OPERATIONS ON THE STOMACH.

THE position of the stomach, and its relations to surrounding parts, are much influenced by the degree of distension that it exhibits, and are further apt to be modified by the effects of disease, either in its own walls or in the structures that surround it.

The *uncovered area of the stomach* is normally represented by a triangle, the right side of which is formed by the edge of the liver, the left side by the borders of the eighth and ninth costal cartilages, and the base by a horizontal line drawn between the tips of the tenth costal cartilages (Fig. 91).

*Operations.*—The following operations upon the stomach will be described :—

1. Gastrostomy.
2. Gastrotomy.
3. Loreta's operation.
4. Resection of the pylorus.
5. Gastro-enterostomy.

## 1. GASTROSTOMY.

This operation consists in establishing an artificial opening (*stoma*) in the stomach, through the parietes, with the purpose that the patient might be fed through the new "mouth."

**The instruments required.**—Scalpels; blunt-pointed bistoury; dissecting forceps; toothed or "nibbed" forceps; pressure and artery forceps; scissors; metal retractors; blunt hooks; curved needles and needle-holder; straight needles for the parietal

wound ; sponges in holders ; sutures ; ligatures, etc. ; sharp tenotome to open the stomach.

**The operation.**—The operation is described as it is carried out when performed in two stages.

1. *The parietal incision.*—The incision is oblique, parallel with the margin of the left costal cartilages, and about one inch from that margin. Its length

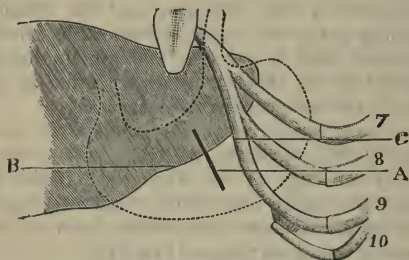


Fig. 91.—A, Incision for gastrotomy ; B, margin of the liver ; C, margin of the costal cartilages ; 7, 8, 9, and 10, seventh to the tenth costal cartilages.

is about two and a half inches, and may be modified according to the thickness of the parietes.

The centre of the incision should correspond to a point from three-fourths of an inch to one inch below the margin of the liver (Fig. 91).

The peritoneum is reached and divided to the full length of the original wound.

2. *The exposure of the stomach.*—Retractors are introduced into the wound and search is made for the stomach. It is recognised by the smoothness and absolute opacity of its surface, by its faint pink colour, and by the thickness and stiffness of its wall, as demonstrated by pinching up a fold between the thumb and finger.

The stomach should be drawn to the wound, and

the spot at which to open it must be determined upon.

This spot should be as near the greater curvature as possible, and at a part free from large veins. It is most important, however, that the new opening should be so placed as to avoid any traction upon the stomach.

As soon as the situation of the "stoma" has been determined upon, the stomach wall may be lightly seized at the centre of the selected area by means of pressure forceps. By means of these forceps the organ can be drawn forwards and held in excellent position while the sutures are being introduced.

3. *The fixing of the stomach.*—This is best effected by means of silkworm-gut sutures and Hagedorn's needles.

The stomach is drawn well forwards into the wound, and each needle is made to take a good hold of the gastric wall. It should penetrate all the coats except the mucous. The needle is then carried through the peritoneum, and ultimately through the muscular layers of the parietes and the skin.

The sutures should be so inserted as to circumscribe an area on the stomach about equal to a shilling-piece. From six to ten sutures will suffice.

The centre of the area circumscribed by the sutures will be represented by that part of the stomach wall to which the pressure forceps are attached. In the place of these forceps a long silkworm-gut suture is passed through the serous and muscular coats. It is left in the form of a long loop, and serves as a sure guide to the spot to be opened when the second stage of the operation is reached.

Before the stitches are introduced into the stomach, the upper and lower extremities of the parietal wound will have been transfixed by silkworm-gut sutures, introduced by means of straight needles passed through the whole thickness of the abdominal wall.

After the stomach has been secured, these sutures are drawn tight and are tied.

This completes the first stage of the operation.

4. *The opening of the stomach.*—This constitutes the second stage of the gastrostomy.

The time that is allowed to elapse before the stomach is opened must depend upon the circumstances of the case. No particular object can be gained by delaying the opening beyond the fifth day.

The guiding suture is drawn upon, and the gastric wall is pierced close to it by means of a sharp tenotome. The knife is withdrawn, and a director introduced; and, guided by the latter instrument, an indiarubber tube, the size of a No. 8 catheter, is passed into the stomach.

## 2. GASTROTOMY.

This term is applied to the operation of opening the stomach for the purpose of removing a foreign body, or for exploration.

**The operation.**—The parietal incision may be made in the same position as is advised in gastrostomy.

The peritoneum is divided and the stomach sought for.

When the surgeon has determined upon the spot at which the opening into the stomach is to be made, two silkworm gut sutures may be passed through the serous and muscular coats of the viscus, one on each side of the area selected for the incision. These sutures are allowed to form long loops, by means of which the stomach can be drawn forwards and held in place.

The stomach wall should be gently drawn well into the parietal wound, and before the opening is made the space between the viscus and the margins of the parietal incision must be plugged with small Turkey sponges.



The incision into the stomach should be transverse to the long axis of the viscus, *i.e.* in the line of the blood-vessels.

As soon as the organ has been opened, the position of the foreign body is made out and steps are taken to remove it.

The next step is the closure of the wound by suture. Fine silk may be used for the purpose. The divided mucous membrane is first of all brought together by means of a continuous suture.

The outer part of the gastric wound is then closed by many points of Lembert's suture.

The parts having been well cleansed, the sponges are removed from the abdomen, and the guiding loops of silkworm gut from the stomach wall.

The parietal incision is closed in the usual way.

### 3. LORETA'S OPERATION.

By this term is understood an operation by means of which digital or instrumental dilatation of the pyloric orifice of the stomach can be carried out.

The stomach is opened by an ordinary gastrotomy incision, and the stricture is dilated by means of the fingers or suitable dilating instruments.

### 4. RESECTION OF THE PYLORUS.

This operation consists in removing the pylorus, together with the adjacent parts of the stomach and of the commencement of the duodenum. After the excision the divided walls of the stomach and the bowel are brought together, and united by sutures.

*The instruments required.*—Scalpel; blunt-pointed bistoury; dissecting and artery forceps; twelve pairs of pressure forceps; large pressure forceps; volsella; blunt-pointed scissors, straight and curved; sharp-pointed scissors; broad spatulæ; rectangular retractors; intestinal clamp; fine toothed forceps; three

dozen rounded intestinal needles; needle-holder; aneurysm needle; blunt hooks; sponge-holders; fine silk; catgut; straight needles and suture material for the parietal wound; sponges, etc.

**The operation.**—The operation may be divided into the following stages:—

- 1st. The opening of the abdomen.
- 2nd. The isolation of the pylorus.
- 3rd. The excision of the diseased parts, and the uniting of the stomach and duodenum.
- 4th. The closure of the parietal wound.

*First stage. The opening of the abdomen.*

—The pyloric tumour having been defined, an incision is made in the skin over it. This incision should follow the long axis of the pyloric end of the stomach, and its centre should correspond to the most conspicuous part of the growth. This parietal wound will, therefore, be more or less transverse. The full incision will be about four or five inches in length, will be above the umbilicus, and will incline from above and from the left downwards, and to the right. The upper third of it will be to the left of the median line.

As soon as the abdomen has been opened, the diseased district is carefully explored, and its relations are noted.

*Second stage. The isolation of the pylorus.*

—The growth is drawn as far as possible into the wound, and a number of sponges are carefully packed around the stomach and pylorus, in order to prevent extravasation into the peritoneal cavity.

The great omentum is now divided close to the greater curvature, and over as small an area as is consistent with the efficient removal of the growth.

The lesser omentum is treated in the same manner.

When the pyloric mass is free, a large flat sponge

is passed beneath it, and the other sponges, packed around the part, must be rearranged.

Some surgeons now clamp both the stomach and the duodenum upon either side of the part to be removed. Others clamp the duodenum only. Various clamps have been devised for this special purpose.

*Third stage. The excision of the diseased parts, and the uniting of the stomach and duodenum.*—The stomach is divided about three-quarters of an inch from the border of the growth—or, at all events, in sound tissue. This is effected by means of strong, straight, blunt-pointed scissors. The cut is made obliquely from above downwards, and from left to right; it divides only about two-thirds of the depth of the organ, and leaves a wide gaping opening in the lesser curvature. If the stomach be not empty, it may now be freed of its contents, and be very gently swabbed out with cotton-wool.

The wound made is at once closed by means of a double row of sutures introduced in the manner already described, *i.e.* a continuous suture for the mucous membrane, and interrupted sutures for the serous coat (page 405).

When all the sutures are in place, the end of the stomach is reduced to about the size of the lumen of the duodenum. The sutures are not cut short at once, but are collected together and held in a bundle by a pair of pressure forceps. They serve to secure and steady the stomach during and after the division of its remaining third (Fig. 92).

The remaining part of the stomach is now divided with the scissors, the cut following the oblique line of the incision already made in the viscus.

The stomach is now free, and its inner surface may be further cleansed if necessary. The growth is grasped by means of the volsella.

The duodenum is now severed by an oblique

incision which runs from above downwards and to the right. It corresponds to the incision in the stomach, and must be entirely clear of the growth.

The margin of the orifice in the stomach is now adapted to that of the freshly-divided duodenum.

Where their borders come together, a series of

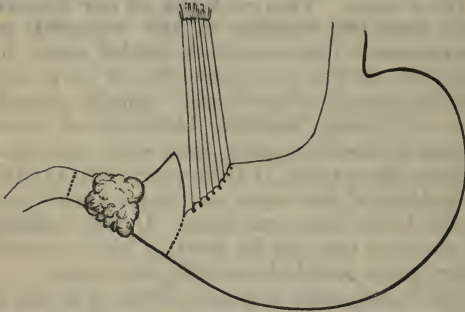


Fig. 92.—Pylorotomy : Third Stage. (Barker.)

close-set sutures are passed across from the one to the other.

These sutures, both deep and superficial, are all tied tightly as soon as they have been inserted.

*Fourth stage. The union of the parietal wound.*—The edges of the omenta are united to the edges of the altered stomach by a few points of suture.

The whole field of the operation is most carefully cleansed, the stomach is replaced, and finally the margins of the parietal wound are united in the usual way.

##### 5. GASTRO-ENTEROSTOMY.

This operation consists in establishing a permanent fistulous opening between the stomach and some part of the small intestine.

The operation is advised in cases of cancer of the pylorus, and was first proposed, and for some time considered, as a substitute for excision of that part of the stomach.

Two methods of performing the operation will be described, namely, the method of Woelfler, and that of Senn.

1. **Woelfler's operation.**—The incision made in the parietes is similar to that employed in excision of the pylorus.

The stomach is exposed, the growth is examined, and the relations of the parts to one another are made out.

The following method of establishing the communication is that advised by Mr. Barker:—

“The first part of the jejunum is caught in the fingers, and a loop drawn out of the incision. The middle of the anterior surface of the stomach is also drawn out and supported all round by warm carbolised sponges. The exposed loop of gut is emptied and clamped at either end. The empty loop of gut is now laid upon the portion of stomach to be opened, and a longitudinal fold of the latter, about one inch and a half from the great curvature, is pinched up between the finger and thumb of the left hand, together with the collapsed gut. These incisions only penetrate through the serous and muscular tunics. Still holding the parts, as before, between finger and thumb, the corresponding posterior edges of the wound are now united by a continuous suture, the needle entering and emerging in each case between mucous and muscular coats, and the threads crossing the cut edges of the muscular and serous coats. In this way the serous surfaces are closely united from end to end before either viscus is opened.

“The moment has now come to open both the stomach and intestine completely, and this is done

with a stroke of the scissors through the mucous coat in each case. After careful cleansing, the anterior borders of both openings are united by a row of interrupted fine silk sutures, introduced according to Czerny's method. When this is completed, the two openings should be securely closed."

The operation is completed as in the procedure for excising the pylorus.

2. **Senn's operation.**—The method of effecting an anastomosis between two more or less distant parts of the alimentary canal by means of perforated bone plates has been already described (page 387).

The following is Dr. Senn's description of the operation as applied to gastro-enterostomy:—

The evening before the operation the stomach is washed out by the syphon-tube, and again just before the anæsthetic is administered. For the last irrigation a five per cent. solution of salicylate of soda may be used.

The incision is made through the median line, and extends from near the ensiform cartilage to the umbilicus. The opening in the stomach is parallel to the long axis of the organ, and at least an inch and a half distant from the margin of the tumour. A continued suture of fine silk is applied around the whole circumference of the opening, both for the purpose of arresting hæmorrhage and preventing bulging of the mucous membrane. In the intestine the opening is made between two rubber ligatures, so as to prevent any extravasation of intestinal contents, and the margins of the wound are sutured in a similar manner.

The opening in the intestine is made first, and the plate introduced and sutures adjusted, and the loop retained in the lower angle of the wound, covered by a warm compress (page 387). The large curvature of the stomach near the pyloric orifice is then drawn

sufficiently forward into the wound to make the incision and introduce the plate. When everything is ready for adjustment, the new openings (wounds) are then brought opposite each other, and the opposed surfaces are united by sutures in the manner already described.

## CHAPTER X.

## OPERATIONS ON THE LIVER.

**Operations upon the liver.**—The following operations will be described:—

1. Cholecystotomy.
2. Cholecystectomy.
3. Cholecystenterostomy.

## 1. CHOLECYSTOTOMY.

This operation implies the making of an incision into the gall-bladder through a wound in the parietes. It is carried out for the removal of gall-stones, and for the relief of dropsy and empyema of the gall-bladder.

By its means various forms of obstruction in the common bile duct have been relieved.

**Instruments required.**—Scalpels; bistouries; dissecting, artery, and pressure forceps; long-bladed dissecting forceps; large pressure forceps for extensive adhesions; rectangular retractors; spatulæ; blunt hooks; scissors; intestinal and other curved needles; needle-holder; needles in handles; sponge-holders; small lithotomy scoops and lithotomy forceps; nasal polypus forceps covered with indiarubber; Lister's sinus forceps; grooved directors; strong needles for breaking up gall-stones; aspirator.

The polypus forceps are used for crushing stones; other forms of forceps may answer equally well.

**The operation.**—The general management of the operation conforms to the lines already laid down in dealing with abdominal section.

The parietal incision is about three inches in length. It is best made vertically over the most prominent



part of the tumour, when one exists, or over the fundus of the gall-bladder when no swelling is evident.

The peritoneum is opened, and the area of the operation is explored with the forefinger. The wound is enlarged as required.

If the gall-bladder be found to be of great size, or very tense from over-distension, it should be carefully aspirated. As the cyst is emptied, its wall is gradually and gently brought into the parietal wound.

If the bladder be but slightly distended, its wall may be brought to the surface without previous aspiration.

The wall of the gall-bladder is best held and drawn forwards by means of pressure forceps. It is then opened by an incision made between the retaining forceps.

The finger introduced through the opening feels for the stones, notes their position, and ascertains the best means for removing them. Loose stones may be removed with the finger, or by means of scoops or forceps of suitable size and pattern. If a stone be discovered impacted in the neck of the gall-bladder, it is well, before attempting its removal, to suture the margins of the wound in the gall-bladder to those of the wound in the parietes.

If the calculus cannot be dislodged, then it may be very slowly and cautiously chipped into fragments by means of forceps; or the disintegration may be effected by the needle, controlled by the finger.

The operation is concluded by completing the suturing of the gall-bladder to the edges of the skin wound. A biliary fistula is thus established.

## 2. CHOLECYSTECTOMY.

The operation for the removal of the gall-bladder has been carried out when it has been found to be impossible to unite the wound in the gall-bladder to

that in the parietes, and in cases in which the walls of the gall-bladder have been too severely damaged by disease or the manipulations of the surgeon to allow suture to be possible.

**The operation.**—Two parallel incisions are made through the peritoneum covering the base of the exposed gall-bladder. The viscus is thus bared, and is rapidly enucleated. The separation begins at the fundus and ends at the cystic duct. The two peritoneal flaps are then united by a continuous suture of fine silk, the cystic duct is secured between two ligatures and divided, and the gall-bladder is removed.

### 3. CHOLECYSTENTEROSTOMY.

By this term is understood the establishment of a fistula between the gall-bladder and the intestine.

The procedure has been carried out in cases in which there is an insuperable obstruction in the common bile duct.

Of the many methods of performing the operation, the following may be selected as the best. This is the method, in three stages, carried out by Tillaux in a case in which the common bile duct was entirely obliterated by a malignant growth springing from the head of the pancreas.

*First stage.*—Laparotomy is performed, and an examination and exploration of the parts concerned are made. The nearest convenient loop of the jejunum is fixed to the gall-bladder by sutures, in such a way as to unite a fairly wide surface of the one to the other. The gall-bladder is now opened and emptied. The margins of the incision in the bladder are united to the parietal wound, and a biliary fistula is established.

*Second stage.*—Some nine days later the bowel is opened into the gall-bladder through the fistula. The

knife, of course, must not transgress the area of adhesion between the two viscera. Means are taken to ensure that the opening between the bladder and the bowel will remain patent.

*Third stage.*—Some eighteen days later the biliary fistula is closed by a plastic operation.

## CHAPTER XI.

## SPLENECTOMY.

SPLENECTOMY, or extirpation of the spleen, has been carried out in cases of injury or prolapse of the spleen, in certain instances of movable spleen, in simple hypertrophy of the organ, and in some cases of tumour of the spleen.

*The instruments required.*—Those required for ovariectomy, with the exception of such special instruments as the ovarian trocar.

**The operation.**—The parietal incision is conveniently made along the outer edge of the left rectus muscle. It is vertical, and may need to be of considerable length. Its upper extremity should lie near to the ribs.

The peritoneum having been opened, the tumour is examined. If any adhesions exist, they must be at once dealt with.

The enlarged spleen is now gently drawn through the wound.

The tumour must be allowed to escape slowly, and as it protrudes the pedicle must be from time to time inspected, lest undue traction be made upon the vessels therein, and especially upon the thin-walled veins.

In the treatment of the pedicle the practice advised by Sir Spencer Wells may be followed. He recommends "temporarily securing all the blood-vessels by pressure forceps as near to the spleen as possible, then removing the enlarged organ, afterwards applying silk ligatures by transfixion behind the forceps, and tightening them as the forceps are

removed. All the ends of the silk should be cut off near the knots."

The ligatures having been all cut short, the peritoneal cavity is well cleansed, and the abdominal wound is closed.

The great risk of the operation is hæmorrhage from the pedicle. In twenty-nine cases collected by Collier, no less than fourteen died directly from bleeding.

## CHAPTER XII.

## OPERATIONS ON THE KIDNEY.

**The operations performed.**—The following operations will be described:—

1. Nephro-lithotomy, or incision of the kidney for stone.
2. Nephrotomy, or incision of the kidney.
3. Nephrectomy, or removal of the kidney.
4. Nephroraphy, or fixation of a movable kidney.

## I. NEPHRO-LITHOTOMY.

**The instruments required.**—Scalpels; bistouries; dissecting, artery, and pressure forceps; toothed forceps; two rectangular metal retractors; metal or ivory spatulæ; syringe. The following special instruments are used in dealing with the stone:—A stout slender needle in a handle; long-bladed tenotome; suitable probes and scoops; steel director; the smallest-sized bladder sound; small lithotomy forceps; Lister's sinus forceps; dressing forceps; nasal polypus forceps.

A. **The lumbar operation.**

1. *The exposure of the kidney.*—The patient lies upon the sound side, as near to the edge of the table as possible. The loin of the affected side is well exposed, and to widen the interval between the last rib and the crest of the ilium a narrow hard cushion may be placed under the loin of the sound side.

The surgeon stands by the patient's back, leaning over the trunk.

The twelfth rib should be definitely recognised and well defined.

An oblique incision is made across the costo-iliac space. The cut commences above, about half an inch below the last rib and close to the outer border of the erector spinæ. It is continued downwards and forwards towards the crest of the ilium. Its length must depend upon the space available and the depth of the tissues of the loin. It will suffice if it be at first three inches in length, and it may be afterwards enlarged to four or five inches as required.

After dividing the skin, superficial fascia, and fat, the outer border of the latissimus dorsi and the hinder border of the external oblique muscles are exposed. The fibres of both are vertical and they are divided to the full length of the skin incision. The sheath of the erector spinæ muscle should not be opened. The internal oblique muscle and the posterior aponeurosis of the transversalis muscle (*fascia lumborum*) are now laid bare. Both muscle and aponeurosis are divided to the full length of the wound. The anterior or outer edge of the quadratus lumborum, and the anterior layer of the fascia lumborum, are exposed. The latter is freely divided. The muscle may be severed in part if it encroaches upon the field of the operation.

The fascia transversalis is now reached and divided, when the peri-renal fatty tissue is exposed.

The retractors are made to take up the whole of the severed structures down to the exposed fatty capsule.

The peri-renal adipose tissue is now opened up with the forceps and finger, and the kidney is reached and laid bare. In order to bring it well into the field of the operation, an assistant should press the anterior wall of the abdomen with the palms of both hands

towards the exposed loin, and endeavour, as it were, to force the kidney into the incision.

2. *The detection of the stone.*—The various surfaces of the kidney are first examined with the finger, whilst the organ is well supported in front by the hand of the surgeon or his assistant.

Should no result follow the examination, the exploring-needle may be used. It is driven systematically into the substance of the kidney from many points. Twelve or more of such exploratory punctures may be made.

Supposing that still no stone is discovered, an incision may be made into the posterior border of the kidney, sufficiently deep to reach the calyces. These cavities may then be explored by the finger, aided by a sound.

3. *The removal of the stone.*—Having detected the stone by one or other of the methods described, “the overlying part of the kidney should be cut into with a narrow straight bistoury; then with a scooping movement of the finger, introduced through the incision, the stone, unless a branched or very large one, can be raised to the surface of the parietal wound on the point of the finger; or a pair of forceps might be passed into the kidney by the side of the finger, and the stone seized and withdrawn. The finger is, however, much to be preferred; and if the incision is small, as it ought to be, the finger serves the purpose of plugging the renal wound, while it lacerates the renal tissue to the necessary extent. By this plan the hæmorrhage is minimised, and the rent made with the finger heals as readily as the cut” (*H. Morris*).

In the place of the forceps a small scoop may be used, and may be made to supplement the action of the finger. Whenever possible, it is most desirable that the calculus be removed entire.



4. *The closure of the wound.*—After the wound has been well washed out, a full-sized drainage-tube should be introduced to the very bottom of the incision.

The wound in the parietes is then closed in the usual way, and the drainage-tube secured in place by a suture. Silkworm gut forms the best suture material.

It is important that the twelfth rib be clearly defined and identified by counting the ribs from above downwards. The last rib is not infrequently rudimentary, and when the pleura descends in such a case below the lower edge of the eleventh rib, it may readily be wounded if the incision be carried upwards.

Rigidity and possible thickening of the muscles in some cases of long-standing disease may raise a difficulty in the way of the operation, and a still more serious obstacle may be due to the matting of the tissues together around the kidney. These inflammatory adhesions and organised deposits of plastic lymph may greatly complicate the operation.

The hæmorrhage from the wound in the kidney may be very severe.

#### B. **The abdomino-lumbar operation.**

The kidney is most conveniently exposed through Langenbüch's incision. The details of this operation are given in the section on abdominal nephrectomy (page 425).

The present procedure is conducted upon the following lines :—The abdomen is opened by Langenbüch's incision over the suspected kidney. The hand is introduced into the peritoneal cavity, and both kidneys and both ureters are carefully examined. The calculus is sought for by the fingers of the hand so introduced, and by means of this hand the kidney is fixed, and the colon guarded during the second step of the operation.

This step consists in cutting down upon the stone from the loin.

The lumbar incision does not implicate the peritoneum, and may be made of much smaller dimensions than the wound usually required. The opening in the abdominal cavity is primarily for the purposes of exploration and diagnosis, and secondarily it allows of the stone being extracted from the loin with greater readiness and certainty.

## 2. NEPHROTOMY.

This term is conveniently applied as well to the mere exposure of the kidney through the loin for the purposes of examination, as to the making of an incision into the organ so exposed for certain therapeutic reasons.

**The operation** is carried out in the manner already indicated (page 418). The general circumstances of the operation, and the instruments required, are considered in the section referred to.

Any abscess or cyst discovered is dealt with according to general surgical principles.

## 3. NEPHRECTOMY.

Nephrectomy may be performed in two ways:—

1. By incision through the loin—lumbar nephrectomy.
2. By incision through the anterior abdominal parietes—abdominal nephrectomy.

### 1. Lumbar nephrectomy.

*The instruments required.*—Scalpels; bistouries; dissecting, artery, and pressure forceps; toothed forceps; large pressure or clamp forceps, straight and angular; broad metal rectangular retractors; metal or ivory spatulae; blunt hooks; stout

aneurysm needle in a long handle; pedicle needle; stout silk ligatures; flat director or periosteal elevator. Sharp spoons and Paquelin's cautery may be of service.

The *position* of the patient and of the operator is the same as has been already described.

**The operation.**

1. *The exposure and isolation of the kidney.*—The incision made is the same as has been already described in the account of nephro-lithotomy (page 418). Through this incision the kidney is exposed, and through it an organ of normal size may be removed.

When the organ is reached and has been superficially examined, it will usually be found necessary to enlarge the original incision. This may be done in many ways.

The oblique incision may be extended to the full length admitted by the conformation of the individual.

Morris advises that to the original cut be conjoined a second incision, running vertically downwards from the first, and starting from it about one inch in front of its posterior extremity. This second incision is left until the kidney has been reached and explored, and is made by cutting from within outwards with a blunt-pointed bistoury, guided by the index finger of the left hand. This vertical incision affords increased facility for dealing with the pedicle.

Some surgeons carry a short transverse incision forwards from the lower end of the oblique one. The actual form of incision is a matter of little moment, provided that sufficient room is obtained and that the peritoneum is not opened.

The fatty tissue around the kidney can readily be detached by means of the index finger of one hand introduced into the depths of the wound, and swept round the organ in close contact with its capsule. In

this manner the gland is readily enucleated and isolated.

When there has been much inflammation, the tissue surrounding the kidney will be found condensed and adherent, and the enucleation of the organ will then be difficult or impossible. In such case the kidney should be enucleated from its thickened and firmly-adherent capsule, and the latter left behind with the pedicle. In effecting this enucleation, a flat hernia director, or a round-pointed periosteal elevator, will be found to be of service. The only guide in such enucleation is the exposed kidney tissue itself.

2. *The treatment of the pedicle.*—The kidney, having been freed, is drawn as far into the wound as possible, and the pedicle is isolated with the fingers.

A suitable aneurysm needle, in a long handle, is passed cautiously between the ureter and the vessels. It is passed naked, and when its point is exposed upon the other side of the pedicle, the eye is threaded with carbolised silk, which is carried through the pedicle in the form of a double loop as the needle is withdrawn. The loop is divided and the needle removed. One ligature should enclose the vessels and the other the ureter. The ligature on the vessels is tied first. It should be carried as deeply as possible, in order that sufficient room may be provided between the kidney and the ligature for safe division of the pedicle.

As the ligature is being drawn tight, all traction upon the pedicle must be taken off.

The more completely the ureter is isolated the better. The ligature that surrounds it may be at once drawn tight, or the ureter may be clamped in the line of the ligature.

The pedicle is now divided with blunt-pointed scissors close to the hilum of the kidney.

The kidney is now removed. Its delivery may be

assisted by pressure exercised upon the anterior wall of the abdomen, and by drawing up the lower ribs.

If the ureter has been clamped, it may be left to be dealt with at this stage of the operation. If it appears healthy, the ligature which surrounds it may be drawn tight and the clamp removed. If it be dilated and occupied with foul or tubercular pus, the stump should be carefully cleansed and then scraped with a sharp spoon. It may, after this treatment, either be ligatured and dropped back into the wound in the usual way, or it may be brought into the parietal incision, and retained there by a few points of suture.

The wound in the parietes is now closed by sutures. These should be of silkworm gut, and should be passed deeply, so as to embrace the various layers of tissue divided. A few superficial sutures will in addition be required. A drainage-tube is introduced into the depths of the wound, and the part is dressed in the usual way and supported by a firm flannel bandage.

## 2. **Abdominal nephrectomy.**

The list of instruments required has already been given (page 422). The operation is conducted upon the general lines observed in other abdominal operations.

The operation here described is that known as Langenbüch's operation.

*The operation.*—The incision—known as Langenbüch's incision—is vertical, is made in the semi-lunar line, is about four inches in length, and is commenced just below the margin of the ribs. The centre of the incision will probably be about the level of the umbilicus. The abdomen is opened, and when all bleeding has been checked the hand is introduced.

As a first measure the hand may be passed across to the opposite side of the body, and the opposite

kidney carefully examined. If this organ be found to be extensively diseased, or if it be discovered that the patient has but one kidney, then the nephrectomy must needs be at once abandoned.

The kidney on the affected side is now examined, its size is estimated, its general characters as regards mobility, consistence, etc., are ascertained, and the condition of its pedicle is demonstrated.

The small intestines are kept aside by means of a large flat sponge, which is introduced into the abdomen.

The colon is made out and pushed towards the median line. The surgeon then incises the outer layer of the meso-colon vertically over the renal region. Into the rent thus made the fingers are introduced and the kidney is laid bare.

If the parts around the gland are in a fairly healthy condition, it is well at once to clear the pedicle and to ligature the vessels. When this has been done, the enucleation of the kidney becomes an almost bloodless procedure. The vessels are reached by stripping off the peritoneum in the direction of the aorta. They may be tied in two segments, the ligatures being passed on an aneurysm needle through the centre of the vascular part of the pedicle. The vessels on the renal side of the ligatures are secured by pressure forceps applied close to the kidney, and between the forceps and the ligatures the vessels are divided with blunt-pointed scissors.

Nothing now attaches the kidney but the ureter. When it is found to be in a fairly healthy condition, it is well isolated and ligatured at the most convenient spot. The ligatured stump is then dropped back into the abdomen and the kidney is removed.

Should the ureter be found to be diseased or be filled with putrid pus, or be in any condition that would probably give rise to further trouble, it may be

turned out through an opening in the loin, as advised by Mr. Henry Morris, and fixed there.

The cavity left by the removal of the kidney is plugged with one or more sponges. Should any bleeding points be detected, they are at once secured with pressure forceps. The sponge will have been some little time in position by the time the ureter has been secured. The sponge is removed and the sac well cleaned out. When the operator has convinced himself that all oozing has ceased, and that the operation area is absolutely clean, the wound in the parietes may be closed in the usual way, and a suitable dressing applied.

If, however, the parts involved have been much disturbed, if there has been much oozing, or if some little oozing still persists, or, above all, if any septic material from the kidney has escaped into the cavity left by the removal of the kidney, then drainage should be employed. The drainage-tube is best carried through the loin at a convenient spot close to the anterior or outer edge of the quadratus lumborum muscle.

#### 4. NEPHRORAPHY.

This operation is practised in cases of floating, movable, or wandering kidney, in which the organ is the seat of frequent, severe, and spasmodic attacks of pain, or of more or less continuous discomfort, and in which all other measures—such as the use of pads and belts—have failed.

**The operation.**—The kidney is exposed through the loin in the manner already described (page 418). When reached, it is well forced into the wound by an assistant, who presses upon it with both hands applied over the anterior abdominal wall. The fatty capsule is well opened up.

Among the many methods that have been employed

to fix the gland, that advocated by Mr. Morris appears to be the most certain. The following is the surgeon's description:—

Three kangaroo tendons are passed through the posterior surface of the kidney—one nearer the upper, the other nearer the lower end, and the third midway between the other two, but nearer the hilum. Each suture is buried for a length of three-quarters of an inch within the renal substance, and penetrates about half an inch into the thickness of the organ. The upper suture passes through the upper edge of the shortened adipose capsule, the transversalis fascia, and the muscles, and is tied to them; the lower suture is similarly passed through and tied to the lower edges of the cut structures; and the intermediate suture is passed through both edges of the divided capsule, fascia, and muscles, and laces all up together. The ligatures are then cut short and buried in the wound; one or two catgut sutures bring the rest of the cut edges of the muscles together, and the skin is closed by silk sutures, one or two of which are made to fix the adipose capsule well up between the edges of the skin.



## Part IX.

### OPERATIONS ON HERNIA.

---

#### CHAPTER I.

##### OPERATIONS FOR STRANGULATED HERNIA.

###### THE OPERATION.

**The instruments required.**—A scalpel and hernia knife; dissecting forceps; fine-toothed forceps; pressure and artery forceps; blunt-pointed bistoury; hernia directors; blunt hooks; needles; needle in handle; scissors; sutures.

The general details of an operation for strangulated hernia will now be described. The special features that belong to the herniæ of particular regions will afterwards be dealt with.

###### 1. **The exposure and opening of the sac.**

—An incision is made over the neck of the sac, and as a rule in the long axis of the tumour. The various layers between the integument and the sac are divided by clean and precise cuts that involve the whole length of the incision. Any vessels that are liable to be divided are secured with pressure forceps.

There is no need to use a director in dividing the tissues that cover the sac.

The various precise anatomical coverings of the sac cannot be identified as they are divided. The subcutaneous tissue can of course be recognised, and in the inguinal region the intercolumnar fascia and the cremasteric fascia can often be made out; but

beyond this the surgeon will be but little reminded of the coverings that are so elaborately displayed in the dissecting-room.

The sac, when well exposed, has usually a distinct capsule-like outline, its walls are tense, and when they are thin, the blood-stained fluid contained therein, or the purple gut, may give to the structure a bluish aspect. In a thick-walled sac, that somewhat characteristic bluish tint may be entirely absent.

The sac is best identified by the fingers rather than by the eyes. As the hernia is laid bare, the surgeon should from time to time pinch up the coverings yet left undivided between the finger and thumb, and estimate their thickness.

The sac, having been identified, is well exposed and its neck well cleared. In most herniæ this is a very essential step; and in cases in which it is intended to divide the stricture without opening the sac, it must of necessity form an important step in the operation.

Before opening the sac, the operator pinches up a minute portion of the wall between his finger and thumb, in order to estimate its thickness and to demonstrate that it is clear from attachments to the contents of the sac. A like fold in the sac wall is then picked up by dissecting forceps and opened by means of a scalpel, the blade of which is held nearly flat. The operator pulls the little fold of sac away from the bowel as he makes the division. When once an opening is made, it is readily enlarged by means of a blunt-pointed bistoury, or blunt-pointed scissors. The sac should be cleanly opened and not torn open.

**2. The division of the stricture and the treatment of the contents of the sac.**—The exposed bowel is carefully examined and its treatment determined upon. The less it is handled the better. If it be in a condition suitable for

reduction, the next step will be to divide the stricture. The neck of the sac is examined with the point of the left forefinger, and the density of the stricture and the best point for introducing the hernia knife are determined upon. The finger must be used gently. There must be no attempt made to dilate the stricture with the finger, or to force the finger through the constricted aperture. The part of the bowel that usually suffers most in strangulated hernia is the part directly embraced by the stricture, and this is the part that will be crushed and bruised if persistent attempts be made to force the finger into the stricture.

The forefinger lies with the nail towards the bowel, and the most the surgeon does is to make clear a point at which the hernia knife can be inserted. The finger is the best director: the hernia knife is passed along it with the blade flat against the finger. The point of the knife at last reaches the pulp of the finger that is pressed against the stricture, while the nail lies against the bowel. The point of the knife is passed, still on the flat, past the finger and into the ring. It is then turned with its edge towards the stricture, and by a slight movement of the blade the stricture is divided.

In many instances the forefinger cannot be entirely relied upon and a director must be used. This especially applies to cases where the neck is deeply placed, where the stricture is narrow and tight, and where a place for the introduction of the hernia knife cannot be made out by the forefinger.

When the director has been passed through the stricture and is in place, it is held in position with the left hand, while the hernia knife is used in the right.

After the knife has been withdrawn, the stricture may be further dilated with the director, which is

forced against the divided fibres and therefore away from the bowel.

It should be a rule to endeavour to make as slight a division of the stricture as possible, such a division as will allow of the gut being reduced, and no more.

The loop of bowel should now be gently drawn down and the constricted part examined.

The next step is to reduce the gut, the fibrous and muscular structures around the hernial orifice being relaxed as far as possible. In inguinal and femoral ruptures this is effected by flexing the thigh upon the pelvis. An attempt is then made to squeeze the bowel by a kind of kneading movement with the thumb and fingers through the opening.

The manipulation must be of the gentlest, and the surgeon must be prepared to exercise considerable patience. If the coil will not return by pressure applied at one extremity, it may yield by pressure applied at the other end of the loop.

After the reduction the finger should be passed through the ring into the abdomen, to make sure that all is clear. The sac is now washed out.

If any omentum exist in the hernia, it must be dealt with as its condition demands.

If it appear healthy, is small in amount, and is quite free from adhesions, it may be reduced. In the majority of cases, however, it will need to be removed. It will be found to be altered in structure, to be inflamed, or to be matted into a granular kind of mass, or to be adherent.

Small portions may be ligatured *en masse* with one catgut ligature, and then cut off. Larger portions are most conveniently dealt with if split up into many strands, often six or more in number, each segment being separately ligatured with catgut, and the whole mass then excised. The ligatures should

be tied as tightly as possible ; but the omentum should not be cut away too near to the knots, lest they slip.

**3. The treatment of the sac and the closure of the wound.**—In very severe cases, in which the patient is already much exhausted, and in which it is desirable to complete the operation with as little delay as possible, the sac may be left as it is, and the wound closed.

In cases of a less extreme degree, in which no complication exists that opposes the measure, the sac may be dealt with according to one of the methods of “radical cure.”

The wound having been well washed out, and any redundant skin removed, the margins of the incision are united by sutures.

**4. When the gut is gangrenous.**—If the bowel, when exposed, be found to be gangrenous, two courses are open to the operator :—

1. The stricture may be divided and the gangrenous bowel resected.

In carrying out the resection, either an artificial anus may be established, which can be closed by a subsequent operation, or the divided ends of the gut may be at once united and returned into the abdomen.

2. The sac having been well opened up, the bowe. is left *in situ* after having been incised, and means are taken to provide the most efficient drainage.

#### THE OPERATION AS APPLIED TO PARTICULAR HERNIÆ.

**1. Inguinal hernia.**—An incision is made over the centre of the tumour and in the long axis of the tumour, and is so arranged that the centre of the wound will about correspond to the external ring (Fig. 93). The cut may at first be some inch and a half in length and be enlarged afterwards.

The sac is exposed ; the only layers of tissue

which will probably be recognised are the intercolumnar and the cremasteric. The superficial external pudic artery will probably be severed in dividing the subcutaneous tissues.

The sac is opened and the contents are dealt with in the manner already described. In dividing the

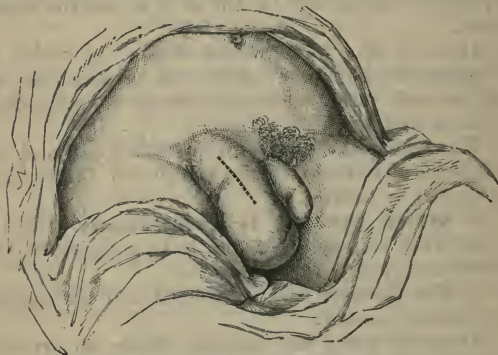

Fig. 93.—Incision for Inguinal Hernia. (After Fergusson.)

stricture, the knife should be made to cut in a direction upwards, *i.e.* parallel with the median line.

To relax the parts about the inguinal ring as the bowel is being reduced, the thigh should be a little flexed upon the abdomen, and should be at the same time a little adducted and rotated in.

In the case of a large scrotal hernia, any redundant skin may be excised.

In dividing the stricture, the only vessel in danger of being damaged is the deep epigastric; and if the incision be kept within proper limits, this danger is very slight. In the oblique form of rupture, an incision directly upwards would quite avoid the artery;

but in a direct hernia, where there is reason to suppose that the vessel is in close connection with the neck of the sac, it is well that the incision be directed a little inwards as well as upwards.

2. **Femoral hernia.**—A vertical incision is made along the inner side of the tumour, and is so placed that the centre of the cut will about correspond to the upper border of the saphenous opening. The wound will be at first about one inch and a half in length, and may be enlarged as required.

As a rule, no vessels of any note are divided in exposing the sac.

The operation is completed in the manner already described (page 430).

The stricture is usually formed by the margin of Gimbernat's ligament, and should be divided by cutting upwards and inwards, *i.e.* towards the median line.

In reducing the bowel the thigh should be a little flexed, adducted, and rotated in.

3. **Umbilical hernia.**—The patient is prepared as for an abdominal section.

Nearly the whole of the skin involved in the protrusion is marked off by means of an elliptical incision, the long axis of which will correspond to the median line. The incision is such as would be made to remove a pendulous tumour of like dimensions situated in the midst of comparatively lax tissues.

The first incision is only skin deep.

The surgeon now deepens the wound upon one side of the base of the mass, and by cutting through the subcutaneous tissue, aims at exposing the aponeurosis of the abdomen a little way beyond, *i.e.* to one side of the neck of the rupture. When once the aponeurosis is reached, it is followed all round the stalk of the tumour by deepening the incision. When this has been done, the hernia, covered by perfectly

undisturbed skin, will be entirely isolated from all the tissues outside the abdomen and be attached only by its neck. The neck must be well cleared, and the aponeurosis which bounds it, and which, therefore, forms the margin of the hernial orifice, must be laid quite bare.

The sac may now be opened at any convenient spot. The contents are exposed, and are dealt with in the manner already described. Adhesions are divided, the bowel is freed and, if in sound condition, reduced into the abdomen. Before this can be done, the hernial orifice will need to be divided; and this can be effected by enlarging the opening above and below the neck of the sac in the median line with a probe-pointed bistoury. This division may be extraperitoneal.

The sac is last emptied, and the next step is to excise the whole of the sac and its coverings, including the elliptical portion of the skin, down to the level of the aponeurosis. This may be effected with the scalpel at one sweep.

The margins of the ring are now freshened, as in plastic operations involving the skin, and the opening in the aponeurotic part of the abdominal parietes is closed by silkworm-gut sutures. They may be introduced on a curved needle in a handle, or by means of a large curved Hagedorn's needle.

The operation is concluded by suturing the skin and subcutaneous tissues.



## CHAPTER II.

THE OPERATIONS FOR THE RADICAL CURE OF  
HERNIA.

THE following methods of operation will be described:—

1. Mitchell Banks's operation.
2. Barker's operation.
3. Ball's operation.
4. Macewen's operation.

## THE RADICAL CURE OF INGUINAL HERNIA.

1. **Mitchell Banks's operation.**—The sac is exposed through the usual incision and carefully separated from the surrounding tissues.

In the case of congenital inguinal herniæ there is always much difficulty in separating the cord. In these herniæ it is necessary to divide the tube a little way above the testicle, so as to make a tunica vaginalis, which ought to be stitched up with fine cat-gut.

The sac having been thoroughly separated and opened, and its contents having been disposed of, it should be well pulled down and tied as high up as possible, whether at the femoral or the inguinal apertures. The great object of the whole proceeding is to restore a uniform surface to the peritoneal wall; and hence the higher up the sac is tied, the better is the chance of this being permanent.

The pillars of the ring are now drawn together by two, three or four sutures of silver wire, silkworm gut, or kangaroo tendon. These are inserted with a curved needle in a handle. Room must, of course, be left at

the lower part of the ring for the spermatic cord to pass through.

These deep sutures are left in position.

The operation is completed by uniting the skin wound with superficial sutures.

**2. Barker's operation.**—This procedure is a modification of that just described.

The sac is exposed, and its neck is ligatured.

The sac is then cut across half an inch below the point of ligature, and the lower scrotal portion is left to take care of itself. One of the threads hanging from the stump of the neck of the sac is now threaded in a Liston's needle, and the latter is passed up the inguinal canal in front of the vas, guided by the left index finger, which pushes the stump of the sac before it, and feels for the inner aspect of the abdominal opening—that is, the internal ring. Here the needle is forced through one border of the ring and out through the external oblique muscle. It is then unthreaded and withdrawn, and is again filled with the other thread hanging from the stump of the sac. This is now carried, in the same way as the first, up the inguinal canal, through the border of the opening opposite to that in which its fellow already lies, and through the external oblique, as before. Both threads being now pulled upon, the stump of the sac is drawn well within the abdomen; and when the threads are knotted securely, the closing of the internal ring is complete.

The inguinal canal is now closed by from 4 to 7 deep silk sutures. Over these the skin wound is united.

**3. Ball's operation.**—The sac having been isolated and emptied, grasp its neck with a broad catch forceps, and gradually twist it up; while this is being done, the left forefinger should be used to free the upper portion of the neck. In ordinary

cases four to five complete revolutions are sufficient ; the twisting should be continued until it is felt to be quite tight, and that any further torsion would produce rupture.

The torsion forceps is now transferred to an assistant, who is to maintain the twist ; a stout catgut ligature is placed round the twisted sac as high up as possible, tied tightly, and the ends are cut off short.

Two sutures of strong aseptic silk are now passed through the skin at a distance of about an inch from the outer margin of the wound, through the outer pillar of the ring, through the twisted sac in front of the catgut suture, and then through the inner pillar of the ring and skin upon the inside. As these sutures effectually prevent the sac from untwisting, it may now be cut off in front of them. If necessary, a point or two of superficial suture may be put in to close the wound completely.

**4. Macewen's operation.**—Space will not permit of a full account of this complex operation. Briefly, it consists of the following method :—The sac is dissected out and separated from its connections. It is then puckered up by means of a suture, and is so drawn upwards as to form a pad upon the abdominal aspect of the hernial opening. The ring and canal are then closed by means of sutures.

## Part X.

### *OPERATIONS UPON THE BLADDER.*

---

#### CHAPTER I.

##### LATERAL LITHOTOMY.

**The instruments employed.**—Grooved staff; lithotomy knife; probe-ended bistoury; lithotomy forceps and scoop; lithotomy tube; sound; probe; pressure forceps; syringe; anklets. To these may be added a petticoated tube or tampon, a lithotrite, and possibly a blunt gorget.

**The placing of the patient in position, and the introduction of the staff.**—The anæsthetic is administered, and as soon as the patient is insensible the anklets and wristbands may be applied. The patient is now brought down to the end of the table until the buttocks are projecting over the actual foot of the table. In this position, and while the legs are hanging towards the floor, the staff may be introduced. As soon as it is in place, the knees are very carefully brought up towards the chest, and the patient is fixed in the lithotomy position.

The assistant who introduces the staff must not take his fingers off the instrument until it is finally removed from the bladder.

The patient being in the well-known lithotomy position, the surgeon seats himself beyond the end of the table, his face being on a level with the patient's perineum.

The presence of the stone should be verified by the staff or by a sound previously introduced.

The position in which the staff is held is of importance.

Two positions are advised. By the older method the staff is held quite perpendicularly, and its concavity is drawn well up against the bony arch of the pubes. It is held rigidly and exactly in the median line. The assistant's thumb is placed upon the rough handle, while his fingers grasp the shaft. The assistant at the same time holds up the penis and scrotum, and sees that the perineal raphe is exactly vertical.

The other position is that advised by Mr. Cadge :— Instead of keeping the handle perpendicular, the staff-holder should incline his hand considerably towards the patient's abdomen, and gently push the convexity of the staff towards the perineum. The staff is steadied against the front of the pubes. This position is assumed only during the making of the first incision. While the second or deep cut is being made, the staff is held in the position first described.

#### **The operation.**

*The first or superficial incision.*—Steadying the integuments of the perineum with the fingers of the left hand, the surgeon makes the first incision. The knife is introduced at right angles to the surface of the perineum, and at a point just to the left of the median raphe, and just behind the central point of the perineum, *i.e.* in the adult about one inch and a quarter in front of the anus. The knife is thrust in the direction of the staff, and its point may just hit the staff. This first movement is of the nature of a stab or a puncture.

The incision is completed as the knife is withdrawn. It is carried downwards and outwards into the left ischio-rectal fossa, and ends at a point between the tuber ischii and the posterior part of the anus,

and one-third nearer to the tuberosity than to the gut.

The incision will in the adult be about three inches in length. It becomes gradually shallower and shallower as it proceeds outwards and backwards from the median line.

*The second or deep incision.*—The left forefinger is now introduced into the wound, and the staff felt for.

The surgeon, keeping his eye upon the staff to appreciate its position in the depths of the perineum, slips the knife along the back of the forefinger until it hits the groove in the staff.

The knife is now pushed cautiously along the groove until it reaches the end of the staff and enters the bladder. The blade should be inclined laterally as it is passed along and be kept parallel with the line of the surface wound.

The incision made in the prostate will therefore be oblique and directed downwards and outwards.

An escape of urine and a sense of abruptly-diminished resistance will announce that the neck of the bladder has been divided.

*The entering of the bladder.*—The left index finger is now introduced along the groove in the staff into the bladder. As soon as the surgeon is sure that he has his finger in the viscus, but not before, the staff is removed. The finger is then employed in dilating the neck of the bladder in all directions, and in ascertaining the size and situation of the stone.

The opening made by dilatation will have to accommodate itself to the size of the stone.

The dilatation must be made in all directions, and not only in the line of the wound.

*The extraction of the stone.*—Without removing the left forefinger the surgeon introduces the lithotomy forceps along the upper or dorsal surface of the digit,

and only withdraws the finger when the forceps are well in the bladder.

The stone is seized and removed. The line of traction in removing the stone should be in the line of the outlet of the pelvis. When the body is in the lithotomy position, therefore, the forceps must be drawn in a direction upwards and forwards.

The bladder is finally explored with the finger for other calculi or for fragments.

The lithotomy tube is introduced, and is secured in place by means of lateral tapes, which are fastened to the two tails of a T-bandage on a level with the perineal wound. The wound is left open and uncovered.

**Lateral lithotomy in children.**—The operation in children is much modified by the anatomical condition of the parts.

The usual incisions are made ; the staff is reached, and a relatively free incision is made into the neck of the bladder. The deep wound is examined with the finger. A pair of dressing forceps is then introduced along the staff into the bladder, and, by opening the blades, the wound in the vesical neck is cautiously enlarged. The forceps are removed, and a probe-pointed director or common probe is then introduced into the bladder along the groove in the staff. The staff is withdrawn, but the probe or director is left in position, as a guide to the bladder, until the operation is completed.

## CHAPTER II.

## MEDIAN LITHOTOMY.

**The operation.**—The method here described is that known as Allarton's.

The patient having been placed in lithotomy position, the staff is introduced, and is held in the same manner as in lateral lithotomy. The surgeon inserts the left index finger into the rectum, and steadies the staff with the point of the finger, which is pressed against it at the apex of the prostate.

The narrow bistoury is now thrust into the median raphe of the perineum half an inch in front of the anus. It is introduced horizontally, and with the cutting edge directly upwards. The groove in the staff is hit at the point where it is steadied by the finger in the rectum. The groove is entered at this point, and by continuing to thrust the knife deeper the apex of the prostate is slightly incised. The membranous urethra is cut through as the knife is being withdrawn, and the external wound is enlarged to the extent of about one inch by cutting upwards as the knife is being removed. As the urethra is incised, the handle of the knife will be pointing almost directly downwards; as the integuments are divided, the handle will be pointing upwards. Special care must be taken to avoid wounding the bulb. A Little's director, or similar instrument, is now introduced along the groove of the staff into the bladder. It is held in the left hand. The staff is withdrawn.

Guided by the director, which is retained in position until the operation is completed, the operator gradually worms his right forefinger into the bladder, dilating its orifice. The forceps are now introduced and the stone is withdrawn.

In ordinary cases no lithotomy tube need be used



## CHAPTER III.

## SUPRAPUBIC CYSTOTOMY.

**The instruments required.**— A scalpel ; probe-pointed bistoury ; scissors ; sharp hook, blunt hooks ; dissecting, artery, and pressure forceps ; broad rectangular retractors ; wound retractors ; rectal bag ; ligature for penis ; syringe ; sound ; lithotomy forceps and scoop ; drainage-tube for bladder ; needles, sutures, ligatures, etc.

The rectal bag should be strong, of oval or pear shape, and of suitable size.

## THE OPERATION.

**The distension of the rectum and bladder.**

—The rectal bag is thoroughly emptied, is smeared with vaseline, is folded in two, and when thus made conical is introduced into the rectum. It should be passed in well above the sphincters, and should lie in the hollow of the sacrum. It should be introduced by someone not otherwise assisting at the operation.

It is better to postpone the filling of the bag until the bladder has been injected. A soft catheter is passed, the urine is drawn off, and through the catheter the bladder is washed out with a warm boracic solution (half an ounce to the pint). This is more conveniently done with an irrigator than with a syringe. The bladder is now filled with a weak warm solution of boracic acid, or a solution of carbolic acid in the proportion of one to eighty or one to a hundred. In children from two to five years of age three ounces will probably suffice. In adults, eight to ten or fifteen ounces may be introduced. The injection should be

carried out by means of an irrigator held a few feet above the level of the table. As the catheter is withdrawn, an indiarubber cord is tied round the penis to prevent the escape of the injected fluid.

The rectal bag is now distended should its use be indicated. It is filled with warm water. For an adult, some ten to twelve ounces may be injected; for a child of five, from two and a half to three ounces. In actual practice the bag is seldom needed in operating upon children, and can very well be dispensed with in such patients. In old and thin subjects also the bag can often be omitted.

**The opening of the bladder.**—An incision about three inches in length is made precisely in the median line above the symphysis. The incision should be extended about half an inch actually over that process of bone. There is no *linea alba* below the umbilicus, and after dividing the skin and subcutaneous tissues, the surgeon may find muscular fibre lying across the line of the incision. If the interval between the muscles is not readily found, the knife should be carried directly through the muscle fibres themselves, the median line being strictly observed.

The wound must be a clean one, and any tearing of the parts with the fingers or forceps, or the handle of the scalpel, to seek for an intermuscular interval, is to be deprecated. When substantial and powerful muscles are met with, it may sometimes be advisable to divide the fibres transversely, to a slight extent, close to their attachment to the bone.

Any bleeding points are secured with pressure forceps. The *transversalis fascia* is reached and divided in the same precise manner in the median line.

The area of connective tissue overlying the summit of the bladder is now exposed. This must be cleanly and precisely divided with the scalpel, and the bladder reached by dissection.

The peritoneum may possibly be made out, and can be readily pushed upwards with the left forefinger. The dissection necessary to expose the bladder should be commenced close to the symphysis, and be continued cautiously upwards.

Wide rectangular metal retractors must now be used in order to extend the width of the wound to the utmost.

The bladder is recognised by its pinkish colour, its rounded outline, and the exposed layer of muscular fibres. The surgeon transfixes the bladder with a sharp hook. This hook should be introduced transversely across the median line and be inserted near the upper part of the exposed viscus.

The scalpel is now thrust vertically into the bladder, exactly in the median line and just below the hook, and is made to incise the organ by cutting downwards towards the symphysis.

The actual opening of the bladder is demonstrated by the escape of the contained fluid. The hold upon the tenaculum should not be relaxed. The cut margin of the bladder on either side of the opening should now be seized neatly and symmetrically with artery or pressure forceps. These enable the operator to maintain a hold upon the organ during the remainder of the operation, and they render the position of the opening perfectly distinct.

When the forceps are in place, but not before, the tentaculum may be removed.

When the bladder collapses, the fold of peritoneum may present at the upper angle of the wound. The tenaculum keeps it out of the way, but it may be noted that the membrane has been inadvertently injured at this stage.

As soon as the bladder has been opened, an assistant may remove the ligature from the penis.

The surgeon holds the right-hand pair of retaining

forceps, while the assistant holds the left; and with the opening thus fixed, the right forefinger is introduced into the bladder.

The opening may be enlarged with a blunt-pointed bistoury as required.

The purpose for which the operation is being executed is now carried out. The stone is removed, the vesical growth is dealt with, or the projecting prostatic lobe is excised.

Before the operation is concluded, the interior of the bladder should be thoroughly explored with the finger. The retaining forceps are removed from the bladder.

Two or three sutures of silkworm gut are introduced into the upper part of the parietal wound, each suture including the whole thickness of the divided tissues.

In certain cases the bladder wound may be closed by suture. These cases are met with in children, and in healthy adults where the viscus itself is healthy, and for the most part concern operations for stone.

#### APPLICATIONS OF THE OPERATION.

**Suprapubic lithotomy** consists in the extraction of a stone from the bladder through an incision made above the pubes.

**Prostatectomy** consists in the removal through a like incision of such part of an enlarged prostate as projects into the bladder cavity. The projecting portion is removed partly by cutting with scissors, and partly by enucleation with the finger. A pedunculated middle lobe is the most readily dealt with. Bleeding is arrested by a stream of hot water. A tube is inserted into the bladder through the wound which is united around it. Masses of prostatic tissue weighing several ounces have been removed by this operation.

**Removal of vesical growths.**—Growths with slender pedicles may be pinched or twisted off. If the pedicle be stout, it may be grasped with one pair of forceps while it is twisted off by another. More sessile growths may be pinched away with Thompson's special forceps, or scraped away with a sharp spoon, or in some instances transfixed at the base and ligatured. The bladder wound is not entirely closed after the operation.

Through a suprapubic cystotomy wound an ulcer of the bladder, such as a tubercular ulcer, may be scraped with a sharp spoon.

## CHAPTER IV.

## URETHROTOMY.

## EXTERNAL URETHROTOMY.

THE operations known by this name include several methods of opening the urethra by an incision in the perineum.

They are carried out in certain cases of stricture of the urethra which have resisted other methods of treatment, and which are, for one reason or another, unsuited for less severe surgical measures.

The following are the operations described :—

1. *Syme's operation*.—In this operation a staff can be passed through the obstruction and upon it the stricture is divided.

2. *Wheelhouse's operation*.—Here the urethra is opened upon the distal side of the stricture. The orifice of the narrowed canal is exposed, a director is passed into it, and guided by this instrument the stricture is divided.

3. *Cock's operation or perineal section*.—In this procedure the urethra is opened behind the stricture and just in front of the prostate. No staff or artificial guide of any kind is used. The operation is applied to cases in which the urethra is practically impermeable.

The term external urethrotomy is also employed in connection with the opening of the normal urethra through the perineum, for the purpose of draining the bladder.

It consists merely in opening the urethra immediately in front of the prostate by cutting upon a staff.

After the incision is completed, the staff is withdrawn, and a perineal tube is passed into the bladder.

The general details of this simple operation are considered in the chapter on Median Lithotomy.

### 1. **Syme's operation.**

*Instruments required.*—Syme's staff; manacles or Clover's crutch; scalpel; probe; director; Teale's probe gorget; perineal tube; catheter.

*The operation.*—The patient is placed in lithotomy position and the staff is introduced. An incision is made precisely in the median line of the perineum, and the knife is so directed that its point shall hit the shoulder of the instrument. The surgeon then engages the point of the knife in the groove of the staff, and, keeping most carefully to the groove, thrusts the knife towards the neck of the bladder until he has divided the whole of the stricture. A director or probe, or Teale's probe gorget, is now introduced along the convexity of the staff into the bladder and the staff is removed. A gum-elastic catheter may then be passed into the bladder through the penis, and be guided into position by the director or probe gorget, aided by the finger inserted into the wound.

### 2. **Wheelhouse's operation.**

*Instruments required.*—Manacles or Clover's crutch; Wheelhouse's hooked staff; two pairs of fine-nibbed forceps; scalpels; catheters; probe; probe-pointed director; Teale's probe gorget; curved needles; needle-holder; artery and pressure forceps; sponges in holders.

*The operation.*—The patient is placed in lithotomy position. "The staff is to be introduced with the groove looking towards the surface, and brought gently into contact with the stricture. Whilst an assistant holds the staff in this position, an incision is made into the perineum, extending from opposite the point of reflection of the superficial perineal fascia to

the outer edge of the sphincter ani. The tissues of the perineum are to be steadily divided until the urethra is reached. This is now to be opened in the groove of the staff, not upon its point, so as certainly to secure a quarter of an inch of healthy tube immediately in front of the stricture. As soon as the urethra is opened, and the groove in the staff fully exposed, the edges of the healthy urethra are to be seized on each side with straight-bladed nibbed forceps, and held apart. The staff is then to be gently withdrawn until the button-point appears in the wound. It is then to be turned round, so that the groove may look to the pubes, and the button may be hooked on to the upper angle of the opened urethra, which is then held stretched open at three points, and the operator looks into it immediately in front of the stricture. While thus held open, a probe-pointed director is inserted into the urethra, and the operator, if he cannot see the opening of the stricture—which is often possible,—generally succeeds in very quickly finding it, and passes the point onwards through the stricture towards the bladder. The stricture is sometimes hidden amongst a crop of granulations or warty growths, in the midst of which the probe point easily finds the true passage. The director having been passed into the bladder, its groove is turned downwards, the whole length of the stricture is carefully and deliberately divided on its under surface, and the passage is thus cleared. The director is still held in the same position, and a straight probe-pointed bistoury is run along the groove, to ensure complete division of all bands or other obstructions. These being thoroughly cleared, the old difficulty of directing the point of a catheter through the divided stricture and onwards into the bladder is to be overcome. To effect this, the point of a Teale's probe gorget is introduced into the groove in the director,



and, guided by it, is passed onwards into the bladder, dilating the divided stricture and forming a metallic floor, along which the point of the catheter cannot fail to pass securely into the bladder. The entry of the gorget into the latter viscus is signalised by an immediate gush of urine along it. A silver catheter (No. 10 or 11) is now passed from the meatus down into the wound, is made to pass once or twice through the divided urethra, where it can be seen in the wound, to render certain the fact that no obstructing bands have been left undivided, and is then, guided by the probe dilator, passed easily and certainly along the posterior part of the urethra into the bladder. The gorget is now withdrawn, the catheter fastened in the urethra, and allowed to remain for three or four days, an elastic tube conveying the urine away" (*Wheelhouse*).

### 3. Cock's operation.

*Instruments required.*—Manacles or Clover's crutch; a broad double-edged knife with a very sharp point; a probe-pointed director in a handle; a perineal cannula; a gum-elastic catheter, to be retained in the bladder through the perineum.

*The operation.*—The operation is thus described in the *Guy's Hospital Reports* for 1866:—

"The patient is to be placed in the usual position for lithotomy. The left forefinger of the operator is then introduced into the rectum; the bearings of the prostate are next examined and ascertained, and the tip of the finger is lodged at the apex of the gland. The knife is then plunged steadily and boldly into the median line of the perineum, and carried on in a direction towards the tip of the left forefinger, which lies in the rectum.

"At the same time, by an upward and downward movement, the vertical incision may be carried in the median line to any extent that is considered desirable.

The lower extremity of the wound should come to within half an inch of the anus.

“The knife should never be withdrawn in its progress towards the apex of the prostate, but its onward course must be steadily maintained until its point can be felt in close proximity to the tip of the left forefinger. When the operator has fully assured himself as to the relative position of his finger, the apex of the prostate, and the point of his knife, the latter is to be advanced with a motion somewhat obliquely, either to the right or the left, and it can hardly fail to pierce the urethra. If, in this step of the operation, the anterior extremity of the prostate should be somewhat incised, it is a matter of no consequence.

“In this operation it is of the utmost importance that the knife be not removed from the wound, and that no deviation be made from its original direction until the object is accomplished. It will be seen that the wound, when completed, represents a triangle; the base being the external vertical incision through the perineum, while the apex, and consequently the point of the knife, impinges on the prostate.

“The knife is now withdrawn, but the left forefinger is still retained in the rectum. The probe-pointed director is carried through the wound and, guided by the left forefinger, enters the urethra and is passed into the bladder.”

Along the groove of the director the cannula or perineal tube is passed into the bladder.

## Part XH.

### *OPERATIONS UPON THE SCROTUM AND PENIS.*

---

#### CHAPTER I.

##### OPERATIVE TREATMENT OF VARICOCELE.

OF the many methods advised the best is that by excision. This operation was introduced by Mr. Howse and elaborated by Mr. Bennett.

**Operation.**—An assistant takes firm hold of the testicle and draws it horizontally downwards, so as to make the cord tense. He should not relax his hold until the operation is completed.

An incision, about one inch and a half in length, is made over the most prominent part of the varicocele. The coverings of the cord are carefully dissected from the varicocele, the vertical line of the original incision being followed. The veins composing the varicocele should be well and cleanly exposed over an extent equal to about one inch and a half. The vas deferens is identified and, together with the small column of veins attending it, very carefully avoided.

The dilated veins are then ligatured in two places, about one inch and a half apart. The lower ligature should be tied first. The vessels so isolated are divided with scissors close to the ligatures and removed.

The amount excised will be represented by about one inch—the scissors being applied about a quarter of an inch from the ligature. The cut ends of the stumps left by the division of the varicocele are brought

together, and retained in permanent apposition by knotting the ends of the upper ligature to those of the lower, thus at once raising the testis to about its natural level. The ligature ends are cut off quite short. The skin wound is then closed.

## CHAPTER II.

## CASTRATION.

**The instruments required.**—A median-sized scalpel; scissors; razor; dissecting forceps; artery forceps (several pairs); a clamp; two large blunt hooks; aneurysm needle; catgut ligatures; straight needle (two and a half inches); suture material; drainage-tube.

**Position.**—The patient lies upon the back, with the thighs extended and a little apart. The surgeon stands on the *right-hand* side of the patient. This position he may occupy both when operating upon the right and upon the left testicle.

**The operation.**—The pubes must be shaved, and the hair removed from the scrotum as far as possible.

A vertical incision is carried from a point about one inch below the external abdominal ring to the bottom of the scrotum.

In dividing the tissues between the skin and the tunica vaginalis, the soft parts should be gently moved to and fro. The mobility of the superficial layers is striking, but the tunica as it is approached is recognised by its perfect immobility.

In the majority of cases it is desirable that the tunica should be opened.

The testis is now shelled out of the scrotal tissues with the fingers. It is practically torn out, and at this step all cutting should be avoided, except when a point resists the fingers.

The tunica vaginalis can very usually be shelled out together with the testis, to which it clings.

The cord is now well isolated with the fingers and drawn down. It is then secured by a clamp. The best clamp for the purpose is a Spencer Wells's large pressure forceps. The assistant holds the clamp, and the surgeon, grasping the testicle, divides the cord with the knife about three-quarters of an inch below the clamp. The vessels of the cord can now be secured. Three arteries must be included in the ligatures—the artery to the vas deferens, the cremasteric, and the spermatic. The deferential artery is found close to the vas. The cremasteric artery lies towards the outer part of the cord and nearer its surface. The spermatic artery is in front of the vas, and is surrounded by the veins of the pampiniform plexus. It is impossible to identify the arteries from the veins. Both veins and arteries are picked up with artery forceps and secured with catgut. The two sets of veins may be tied each in a mass. Three or four ligatures may be required, but very seldom more.

Before removing the clamp a couple of bull-dog artery forceps should be temporarily fixed into the cord, in order that it may be readily drawn down again, should bleeding follow the removal of the clamp.

Finally, the wound in the scrotum is closed by sutures.

## CHAPTER III.

## AMPUTATION OF THE PENIS.

**The instruments required.**—An elastic band tourniquet; a gum-elastic catheter; a scalpel; a narrow straight bistoury; straight and curved scissors; a tenaculum; dissecting, toothed, and artery forceps; small curved needles and needle-holder for the urethra; straight needles; a periosteal elevator; sutures; ligatures.

**Amputation of the free portion of the penis.**—Hæmorrhage having been provided against, a rectangular flap of skin is cut from the dorsum and sides of the penis, and the dorsal arteries are secured. The flap may be compared, in miniature, to the anterior flap in an amputation of the thigh. A narrow-bladed knife is then made to transfix the penis at a point on a level with the base of the above flap, between the corpora cavernosa and the corpus spongiosum, and then is made to cut forwards, outwards, and downwards, for about three-quarters of an inch. From this smaller inferior flap the urethra is dissected out. The corpora cavernosa are then cut vertically upwards, on a level with the point of transfixion. The tourniquet is removed, all bleeding points are tied, and the upper or skin flap is punctured at a point opposite to the divided urethra. That tube is drawn through the punctured hole in the flap, is slit up and stitched *in situ*. The two flaps, upper and lower, are then joined by sutures.

It is claimed for this operation that a natural skin covering is secured for the severed corpora cavernosa, and thus the irritation and delay which the healing of these bodies by granulation entails are avoided.

**Amputation of the entire penis.**—The best procedure is that devised by Pearce Gould. It ensures a very complete removal of the diseased organ. The new opening of the urethra is well established. There is no risk of an infiltration of urine into the tissues of the scrotum, and the skin of the part is not irritated by the trickling of urine over it.

*The operation is performed as follows:—*

The patient having been placed in the lithotomy position, the skin of the scrotum is incised along the whole length of the raphe. With the finger and the handle of the scalpel the two halves of the scrotum are then separated, quite down to the corpus spongiosum. A full-sized metal catheter is now passed as far as the triangular ligament, and the knife is inserted transversely between the corpora cavernosa and the corpus spongiosum.

The catheter having been withdrawn, the urethra is cut across. The deep end of the urethra is then detached from the penis quite back to the triangular ligament. An incision is next made round the root of the penis, continuous with that in the median line; the suspensory ligament is divided and the penis separated, except at the attachment of the crura. The knife is now laid aside, and with a stout periosteal elevator, or rugine, each crus is detached from the pubic arch. This step of the operation involves some time, on account of the very firm union of the parts to be severed. Four arteries—the two arteries of the corpora cavernosa and the two dorsal arteries—require ligature.

The corpus spongiosum is slit up for about half an inch, and the edges of the cut are stitched to the back part of the incision in the scrotum.

The scrotal incision is closed by sutures, and a drainage-tube is so placed in the deep part of the wound that its ends can be brought out in front and behind. No catheter is retained in the urethra.



## Part XXX.

## OPERATIONS UPON THE RECTUM.

## CHAPTER I.

## OPERATIVE TREATMENT OF HÆMORRHOIDS.

THE following operative measures, applicable to internal piles, will be here described:—

1. Treatment by ligature.
2. Treatment by excision.
3. Treatment by crushing.
4. Treatment by the cauterly.

**The instruments required.** *Ligature operation.*—Clover's crutch; pile-holding forceps; scissors—sharp and blunt-pointed, straight, and curved on the flat—(special forms of hæmorrhoid scissors, such as the well-known scissors or shears introduced by Salmon, are not specially convenient); pressure and artery forceps; silk.

*Excision operation.*—The same instruments, with the addition of dissecting forceps, volsella, needles and needle-holders, catgut ligatures, sponges in holders. A rectal speculum may be of use.

*The operation by crushing.*—In addition to the chief instruments already mentioned, a special crushing clamp is required; and in the *treatment by the cauterly*, Smith's clamp and Paquelin's cauterly are needed.

1. **The operation by the ligature.**—Clover's crutch is applied, and the patient is placed in the

lithotomy position, the buttocks being brought close to the lower end of the table. The surgeon sits facing the perineum.

The first step consists in dilating the sphincters. Both index fingers are introduced and the anus is slowly and gradually stretched.

The parts are now in a convenient condition for operation.

Each pile is seized with the pile-holding forceps, held in the left hand, and is gently drawn away from the anus and towards the middle line. Its base is rendered tense, and the line of junction of the skin with the mucous membrane is brought well into view.

By a series of snips with the scissors the surgeon severs all the *lower* attachments of the pile, cutting along the line of junction of the skin and mucous membrane.

By a few light snips, aided with a little pressure from the blunt point of the scissors, the pile is dissected up from the submucous tissue until it is attached only by the healthy mucous membrane above it, and by the vessels that are descending to enter it. As the vessels come from above and run just beneath the mucous membrane, and enter the upper part of the hæmorrhoid, this detachment is readily and safely accomplished and the bleeding is very trivial.

The detachment should be sufficiently extensive to form a deep groove.

The forceps are now handed to an attendant, who maintains the traction upon the pile, while the surgeon places a silk ligature round its pedicle, which he at once proceeds to tie as tightly as possible.

The number of ligatures to be applied will of course vary. More than five will seldom be required.

The operation is completed by cutting the ligatures off, and by snipping away the strangulated hæmorrhoidal tissues that project beyond the knot. The

parts are lightly dried with wool, dusted with iodoform, and returned.

2. **The operation by excision.**—Of the various methods of treating piles by excision that have been from time to time employed, the most precise, and probably the most successful, is that introduced by Mr. Walter Whitehead.

The patient is secured in the lithotomy position by Clover's crutch, and the sphincters are fully dilated. "By the use of scissors and dissecting forceps the mucous membrane is divided at its junction with the skin round the entire circumference of the bowel, every irregularity of the skin being carefully followed. The external and the commencement of the internal sphincters are then exposed by a rapid dissection, and the mucous membrane and attached hæmorrhoids, thus separated from the submucous bed on which they rested, are pulled bodily down, any undivided points of resistance being nipped across, and the hæmorrhoids brought below the margin of the skin.

"The mucous membrane above the hæmorrhoids is now divided transversely in successive stages, and the free margin of the severed membrane above is attached as soon as divided to the free margin of the skin below by a suitable number of sutures."

In this way the complete ring of pile-bearing mucous membrane is removed. All bleeding vessels encountered throughout the operation are treated by torsion.

3. **The operation by crushing.**—Of the many pile-crushers devised, the most convenient is that known as Allingham's.

The patient having been placed in position, and the sphincter dilated, a pair of pile-holding forceps is passed through the open square of the crusher, a pile is seized with the forceps, and is then drawn into the crusher, the blade of which is at once screwed down. The instrument should be screwed up as tightly as

possible, and should be left in place for a minute or two. The portion of the pile projecting beyond the clamp is then either cut away or destroyed by the cautery. The clamp is now slowly unscrewed and removed, and it will usually be found that no bleeding follows. Any bleeding vessel may be secured by a ligature or be twisted.

**4. The operation by the cautery.**—The patient having been placed in position, and the sphincter having been dilated as above described, each pile is seized in turn and drawn between the blades of a Smith's clamp, which are then screwed tightly together. The part of the pile projecting beyond the clamp is then cut off, and the stump, which should be at least one-eighth of an inch in depth, is well charred with the Paquelin's cautery. The cautery point should be heated only to a dull-red heat; the clamp is slowly relaxed, and the surgeon follows with the cautery point the charred tissues as they slip out between the blades.

## CHAPTER II.

## OPERATIVE TREATMENT OF FISTULA.

**Operation.**—The patient is placed in lithotomy position and secured there by a Clover's crutch. It is assumed that an external opening exists. A Brodie's probe-pointed fistula director is introduced into the fistula, and is passed into the bowel through the internal opening. Not the very least force must be employed. The internal opening might have been already examined, and the passing of the probe may be carried out while a speculum keeps the inner opening in view. If the probe is found to present under the thinned mucous membrane in a case in which no internal opening exists, the point of the director should be thrust through the mucous membrane at the thinnest spot. In every case, when possible, the probe should be passed while the left forefinger occupies the rectum and acts as a guide.

In a simple case in which the inner orifice is low down, the point of the director may be engaged upon the top of the left forefinger (lying in the rectum), and may be cautiously brought outside the anus. Nothing then remains but to slit up the fistula with a sharp-pointed curved bistoury.

When the inner opening is high up, a plug of soft wood about the size of the forefinger may be introduced into the rectum, and the probe brought into contact with it. A sharp-pointed bistoury is passed along the fistula until it enters the bowel. Its point is then driven into the wooden plug, and as the two are brought out together, the tissues that separate the length of the sinus from the bowel cavity are divided.

After the division of the fistula comes the most delicate part of the operation—the search for secondary fistulæ, for burrowing tracts, and for diverticula from the primary sinus.

## CHAPTER III.

## EXCISION OF THE RECTUM.

EXCISION of the rectum, or proctectomy, is carried out in certain cases of malignant disease involving the anus or lower part of the rectum. The term is a little misleading, inasmuch as the rectum is never excised, but only a comparatively small part of it. The cases suited for this mode of treatment will be found to be few in number.

The best results follow—other things being equal—when the growth is upon the posterior wall of the gut.

The amount that may be safely excised cannot be estimated by anatomical data. Very rarely does the excised portion measure more than three inches in length.

**Instruments required.** — Clover's crutch; curved sharp-pointed bistoury; straight probe-pointed bistoury; scalpels; straight blunt-pointed scissors; scissors curved on the flat; two pairs of volsella forceps; dissecting forceps; a liberal supply of pressure forceps; artery forceps; sponges in holders; rectum speculum; syringe; Paquelin's cautery; ligatures.

Curved needles in holders may be required.

**The operation.**—The patient is placed in the lithotomy position, the lower limbs being secured by means of Clover's crutch.

The left forefinger is passed into the rectum, and the position of the coccyx is defined; a curved sharp-pointed bistoury is now introduced into the rectum by the side of the left finger, and is made to cut directly backwards and precisely in the median line. In this

way all the soft parts between the rectum and the coccyx are cleanly and evenly divided. The lateral incisions are now made. The position of each will depend upon the distance between the growth and the margin of the anus. Whenever possible, these lateral incisions should be made through the mucous membrane. When the growth actually reaches the anus, they must of necessity be made through the skin.

Each incision is commenced behind, at the posterior wound already made, and is carried boldly into the ischio-rectal fossa. The corresponding buttock is steadied and held aside as the cut is being made. All bleeding points are at once seized with pressure forceps.

The finger, thrust into the incision on each side, will readily separate the rectum, except at the insertion of the levator ani. The fibres of that muscle must be divided with scissors. The two lateral incisions are crescentic and so carried round the bowel as to meet in front. As each one is finished, and as the separation on each side and behind is completed, the deep wound outside the rectum thus left by the scalpel and the finger is plugged with a sponge.

The lateral and posterior parts of the rectum are thus freed.

The next step is the difficult one of separating the bowel from its anterior connections. In the case of a male subject, this is much facilitated by having a full-sized catheter passed into the urethra and held in the position of the staff in lithotomy. In the female, the finger introduced from time to time into the vagina will afford valuable guidance. The portion of the bowel already detached is held by an assistant, who draws it downwards. The surgeon proceeds to separate the gut from its anterior connections by means of blunt-pointed scissors, aided by the left forefinger.



When the rectum has been freed all round well above the upper limits of the disease, the gut is cut across transversely by scissors. The division should be made cautiously and in sections, and all bleeding vessels are secured at once with pressure forceps. These forceps serve also to maintain a hold upon the divided intestinal wall. The wound cavity is now syringed out and dried. The sponges in the ischio-rectal fossa are removed, and the vessels held by the pressure forceps are secured as required.

It is not necessary that the mucous membrane should be attached to the skin at the anal margin by sutures.

## Part XXX.

### OPERATIONS ON THE HEAD AND SPINE.

#### CHAPTER I

##### TREPHINING IN FRACTURE OF THE SKULL.

**Instruments required.**—Trepines of various sizes ; a quill ; a trephine brush ; a pair of Hey's saws ; a small pair of bone-cutting forceps ; slender chisel and mallet ; a pair of gouge forceps, such as Hopkins's rongeur ; an elevator ; periosteal rugine ; necrosis forceps ; scalpels ; dissecting, pressure, and artery forceps ; scissors ; dressing forceps ; fine-toothed forceps ; fine scissors for the dura mater ; small tenaculum or slender curved needle in a handle for bleeding vessels ; probe ; needles and sutures.

The head is shaved and is conveniently supported upon a sand-bag covered with thin macintosh sheeting.

**The operation.** — When any wound already exists, the fracture is exposed by enlarging it as required. When the scalp is sound, a semilunar flap may be raised, the free end of which points vertically downwards.

The incision should be carried at once down to the bone, and the pericranium having been detached with a curved rugine, the flap as it is turned up will be composed of all the soft parts covering the skull.

The fracture is now exposed and examined. It may be found to be possible at once to introduce an elevator beneath the depressed bone, and to elevate it.

In other cases a rim of projecting bone—belonging to the sound part of the skull—may be removed with a narrow chisel and mallet, or with Hey's saw, or with the gouge forceps, and a little space is thereby provided, which will allow of an elevator being introduced.

In a comparatively few cases the trephine will be needed. The centre-pin of the instrument is protruded about one-sixteenth or one-tenth of an inch and firmly fixed by the screw; the crown is then applied to the sound bone near to the fracture. As a rule, it is so applied that two-thirds or three-fourths of the circle will be upon the sound skull, and the remaining third or fourth over the fractured area.

The point is bored into the bone and then the trephine is made to cut into the skull by light, sharp movements from left to right, and from right to left.

At first the instrument may be steadied by the left forefinger, which rests upon the skull. As soon as the groove has been cut all round, the pin may be withdrawn, and the instrument will be found to maintain a steady hold of the part. The pressure must be evenly maintained throughout, and will be found to be chiefly exercised when the hand is turned from left to right (the supination movement).

The wound in the bone must be kept constantly clear of dust by frequent irrigation and the use of the trephine-brush or the quill. The trephine itself is rinsed in a warm carbolic solution from time to time, to free it from *débris*. The depth of the groove in the skull must be estimated very frequently with the quill. Inasmuch as the skull is spheroidal, it is exceedingly difficult to make the groove of equal depth all round.

When the groove is of sufficient depth, the disc of bone may be removed by gently rocking the trephine

to and fro while it is still in position, or by cautiously introducing an elevator at a spot where the bone is entirely divided. Not infrequently the disc bone can be grasped with forceps and lifted out.

Should any portions of the inner table be left behind, they can be removed by the elevator or the cutting gouge.

In removing large discs of bone it is important that the dura mater be carefully stripped from the inner table as the button is being cautiously lifted up with the elevator.

The trephine disc, as well as any fragments of bone afterwards removed, should be at once put in a china receptacle containing a warm solution of corrosive sublimate (1 in 2,000), and maintained at a temperature of 100° F. The trephine disc and any other fragments of bone that have been preserved are replaced as nearly as possible *in situ*.

The flap or flaps of scalp are now brought into place by silkworm-gut sutures, and drainage is secured by introducing a bunch of fine catgut threads here and there between the stitches.

#### TREPHINING FOR ABSCESS OF THE BRAIN.

The trephining is carried out in the manner already described. The dura mater is exposed, and will usually be found to be without pulsation, and to bulge into the trephine-hole. This change in the membrane is a certain sign, not necessarily of pus, but of increased intracranial tension.

The dura mater is incised with the scalpel, and is then opened by the aid of fine scissors and delicate-toothed forceps. The division should be so made as to render the subsequent closure of the rent with sutures possible. The aspirating needle having been introduced and pus discovered, the next step is to

insert a pair of slender sinus forceps by the side of the needle, and to enlarge thus the track along which the pus may escape.

Along the passage thus made a drainage-tube of indiarubber or of silver is introduced. The flap is now adjusted, but the sutures must be omitted at the apex of the flap, so that the trephine-hole may not be entirely covered up, but that there may be every opportunity offered for the escape of the matter.

#### TREPHING FOR CEREBRAL TUMOUR.

**Instruments required.**—In addition to the instruments already mentioned as used in trephining, the following are employed:—Very large trephines with a diameter of  $1\frac{1}{2}$  or 2 inches; a circular saw worked on a Bonwill's surgical engine; strong bone-cutting forceps; fine curved needles and a needle-holder for suturing the dura mater; wire serres-fines; scoop or enucleator; sharp spoon; Horsley's flexible knife.

The exposure of the brain is effected by the large trephines. An opening may be made at the two extremities of the area to be removed, and the intervening bridge of bone may then be divided by means of Hey's saw or the chisel and mallet. The dura mater during the process will be protected by a thin metal spatula. All the bone fragments removed are preserved in the manner already described (page 472).

The dura mater is now divided around about four-fifths of the margin of the aperture in the bone. The incision is made about one-eighth of an inch from the bone, so as to leave room for suturing.

Incisions into the brain must be clean cut, be vertical to the surface, and be directed into the corona radiata when necessary, so as to avoid damage to fibres coming from other portions of the cortex. The growth may be enucleated by means of Horsley's flexible

knife, or by a scoop or sharp spoon. In all cases, adherent or altered dura mater must be excised.

When a portion of brain has been cut away, the underlying cerebral tissue soon bulges up, and obliterates the hollow left by the loss of substance.

Hæmorrhage from the brain tissue is seldom troublesome.

The flap of dura mater is brought into place and secured to the unwounded part of the membrane by a few fine catgut sutures; space, however, must be left for drainage. The bone discs and portions of skull removed by the saw are now arranged and secured in the manner already described.

The scalp flap is brought into place and secured by sutures, room being allowed for drainage.

## CHAPTER II.

## EXCISION OF THE EYE-BALL.

**The instruments required.**—Eye speculum ; strabismus hook ; strabismus scissors ; toothed forceps ; blunt-ended scissors curved on the flat ; small sponges.

**The operation.**—The patient's head is a little raised and the surgeon stands in front, facing the patient.

The speculum is introduced between the lids and opened.

With the blunt-pointed scissors the surgeon snips through the conjunctiva just behind the corneal margin. The toothed forceps are used to pick up the membrane and to steady the globe. The division of the conjunctiva is complete all round.

By the further use of the scissors Tenon's capsule is freely opened, and each of the rectus tendons is then picked up in turn by the strabismus hook and divided close to the sclerotic with the strabismus scissors. It is convenient to begin with the external rectus, then to divide the superior and inferior recti, and to finish with the inner rectus. If the speculum be now pressed back into the cavity of the orbit, the eye-ball will start forwards. The blunt-ended scissors curved on the flat are then introduced into the orbit to the outer side of the globe, and are carried back until the optic nerve is reached. It is divided by one cut of the blades.

The eye-ball being drawn forwards with the fingers, the oblique muscles are divided, together with any soft parts that may still hold the globe in place.

A piece of Turkey sponge is then pressed into the

cavity of the orbit and allowed to remain there for a few minutes.

The first dressing consists merely of an aseptic sponge pressed into the cavity of the orbit and retained in position by a pad and bandage.



## CHAPTER III.

## OPERATIONS UPON THE SPINE AND SPINAL CORD.

THE usual operation consists in opening the spinal canal from behind for the purpose of relieving the cord from pressure, or for giving escape to inflammatory exudations or for removing tumour from the cord.

**The instruments required.**—Stout and fine scalpels ; trephine ; bone-cutting forceps ; rugine ; elevator ; necrosis forceps ; chisel and mallet ; retractors ; blunt hooks ; probe ; Volckmann's spoons ; fine tenaculum-pointed forceps ; fine scissors ; small curved needles and needle-holder ; straight needles ; ligatures ; sutures, etc.

**The operation.**—The patient lies in a prone or semi-prone position.

A long incision is made in the median line, exactly over the spines of the vertebræ, in the region it is desired to expose.

The incision is carried deep down, and the muscles are freely separated from the sides of the spinous processes and the posterior surfaces of the laminae by the knife, aided by the rugine. One side is cleared, and all the bleeding arrested, before the other side is exposed in like manner.

A considerable portion of the spine being now exposed, the periosteum is divided along the angle between the spinous processes and the laminae, and is then reflected from the surfaces of the vertebral arches by means of a curved rugine. Firm rectangular metal retractors are needed at this stage of the operation.

The spinous processes are now divided close to

their bases by means of large, strong bone-cutting forceps, with blades set at an obtuse angle. It is now necessary to divide the laminae on each side, in order to expose the vertebral canal. Some surgeons have used a trephine for the purpose—a not very convenient instrument; others have employed Hey's saw, or the chisel and mallet, or bone-cutting forceps. The method employed must depend upon the surgical habit of the individual.

The laminae should be divided as near to the transverse processes as possible. When the neural arch has been removed to a sufficient extent, the dura mater is well exposed. The operation may end here.

If it be determined to open the dura mater, it is seized in the middle line with fine tenaculum-pointed forceps and opened vertically—either by a small scalpel, or, better, by means of fine scissors. When the divided parts are retracted upon each side, the whole of the posterior surface of the cord is well exposed.

Any tumour detected is dealt with by simple excision. (*See* the section on Tumours of the brain, page 473.)

The opening in the dura mater is closed by many points of fine catgut, introduced by means of a curved needle in a needle-holder.

A drainage-tube is now placed along the whole length of the wound, in its deepest part. The muscles are brought together above it by means of catgut sutures; after which the superficial parts are united by sutures of silkworm gut.

#### THE AUTHOR'S OPERATION ON PSOAS ABSCESS.

The operation consists in reaching the psoas muscle and the anterior part of the vertebral column through the loin.

The patient's loin having been exposed, a vertical

incision some two and a half inches in length is made through the integuments. The centre of this cut should lie about midway between the crest of the ilium and the last rib, and the cut should be so placed as to correspond to a vertical line parallel with the vertebral side of the outer border of the erector spinæ.

After cutting through the superficial fascia the dense aponeurosis is exposed that covers the posterior surface of the erector spinæ. The part of this layer laid bare in the lower half of the incision is wholly tendinous, but from that seen in the upper half of the cut arise some of the fibres of the latissimus dorsi. The aponeurosis with its attached muscular fibres having been divided in the full length of the incision, the erector spinæ is exposed. The outer border of the muscle should now be sought for, and the whole mass drawn by means of retractors as far as possible towards the middle line of the back. In this way the anterior part of the sheath of the muscle is readily exposed.

Through this sheath the transverse processes of the lumbar vertebræ should be sought for. The longest and most conspicuous process is that belonging to the third vertebra. It is readily felt. The erector muscle having been drawn as far as possible towards the middle line, the anterior layer of its sheath must be divided vertically as near to the transverse processes as convenient. By this incision the quadratus lumborum muscle is exposed. The muscle should be divided close to the extremity of a transverse process, and the incision cautiously enlarged until the muscle is divided to the full extent of the skin wound. It is at this stage there is danger of wounding the abdominal branches of the lumbar arteries. The inner edge of the quadratus is overlapped by the psoas muscle, so that when the former is divided the latter is exposed. The psoas fibres, as now seen, take about the same

direction as the posterior fibres of the quadratus, *i.e.* run downwards and outwards. The interval between the two muscles is marked by a thin but distinct layer of fascia, known as the anterior lamella of the fascia lumborum. Some of the tendinous fibres of the psoas having been divided close to a transverse process, the finger is introduced beneath the muscle, and gently insinuated along the process until the anterior aspect of the bodies of the vertebræ is reached. The incision in the psoas can be enlarged to any extent.

As soon as the abscess cavity is well opened, the finger is introduced and the anterior surface of the vertebral column examined as far as is possible. Such examination is, of course, only called for in cases of disease of the lumbar or dorso-lumbar section of the column.

The abscess cavity is evacuated and well flushed out with an antiseptic solution. The caseous contents and lining membrane are entirely scraped away. The cavity is then dried with sponges and the wound closed.

## Part XIV.

### OPERATIONS ON THE THORAX AND BREAST.

#### CHAPTER I.

##### OPERATIONS ON THE THORAX.

The following **operations** will be described:—

1. Incision of the thorax, with or without resection of a portion of rib.—Thoracotomy.
2. Esthlander's operation.—Thoracoplasty.

##### 1. INCISION OF THE THORAX.—THORACOTOMY.

This operation is carried out in cases of empyema. It consists of opening the suppurating cavity and draining it.

The site of the incision must be influenced obviously by the physical signs afforded by the empyema.

**Simple incision.**—The patient is brought to the extreme edge of the table and allowed to lie as nearly as possible upon the back.

An incision, from one and a half to three inches in length, is made transversely, so as to correspond to the upper border of the lower rib bounding the space.

The intercostal muscles are divided close to the rib; a director is then gently thrust through into the pleural cavity; the opening made is afterwards enlarged with dressing forceps and the finger.

The pus, if considerable in quantity, should be allowed to escape slowly.

If for any reason the incision has not been quite

conveniently placed for drainage, a counter-opening lower down in the thorax should be made.

If during the operation an intercostal artery be cut, the surgeon's first care should be to see that the vessel is entirely severed, and not partly divided. Failing this, pressure may be kept up for a while with the finger or a plug of fine sponge.

**Incision, with removal of a portion of a rib.**—In some cases the simple incision described does not permit of a free enough opening being made into the pleural cavity, or does not permit of as extensive an examination being carried out as is necessary. In such instances a small portion of one, or even two, ribs may be excised. The rib is exposed through the incision already made and completely bared of periosteum by a curved rugine. By thus baring the rib the intercostal artery is avoided. The rib is then steadied with lion forceps or flat-bladed necrosis forceps, and is divided in two places with a fine saw. The section may be completed with cutting forceps, but any attempt—especially in adults—to divide the entire rib by forceps is to be deprecated. About one inch and a half of the rib should be removed.

After its excision the sac of periosteum left behind is cut away. It is at this step of the operation that the intercostal artery is probably divided. It can, however, be most readily secured. By first stripping off the periosteum, division of the intercostal artery at an inconvenient time is avoided. The vessel is turned back with the periosteum.

It is well to excise the periosteum thus left isolated, since it may produce, at a later period, an inconvenient mass of ill-formed bone.

## 2. ESTHLANDER'S OPERATION.—THORACOPLASTY.

This operation is carried out in certain cases of empyema of long standing—cases in which no healing

follows, in spite of long-continued and free drainage of the purulent cavity.

**The operation.**—The patient having been placed in position and anæsthetised, the cavity to be treated is thoroughly examined, its full extent is ascertained, and the condition of its interior is determined.

The cavity will be found in the upper or central parts of the pleural space, rather than in the lower.

A special operation must be planned for each case, and it is impossible beforehand to determine how many ribs will have to be resected, or how much of each one will have to be removed.

Success depends upon the removal of the whole of the unyielding bony wall of the cavity, and the limits of the excision are identical with those of the suppurating hollow that has to be closed.

The ribs usually removed are the second, third, fourth, fifth, sixth, and seventh. The amount excised will vary from an inch or so to nearly the whole length of the bony part of the rib.

Various plans are adopted for exposing the costal walls. Some surgeons recommend a flap composed of all the soft parts covering the ribs.

Esthlander makes a transverse cut over the centre of an intercostal space, and through this wound excises portions of the two ribs which bound the space. If, therefore, six ribs have to be removed, three of such incisions will be called for.

Gould recommends a vertical incision over the central part of the cavity, and this, probably, will be found as convenient a way of exposing the ribs as any.

Each rib is exposed in turn and bared of periosteum with the curved rugine. It is then excised in the manner already described. The periosteum is removed after each excision.

The whole of the thickened pleura exposed is cut away.

The hæmorrhage attending the operation is often considerable, but is readily controlled.

In dealing with the ordinary cavity, the skin is brought into place by silkworm-gut sutures and the wound thus closed. A large drainage-tube is introduced into the most dependent part of the cavity.



## CHAPTER II.

## REMOVAL OF THE BREAST.

**The instruments required.**—A large scalpel ; a small scalpel ; dissecting forceps ; six to ten pressure forceps ; artery forceps ; a tenaculum ; scissors ; long straight needles ; ligatures and sutures ; a kidney-shaped receiver ; drainage-tube.

**Position.**—The patient is brought to the edge of the table and lies with the head and shoulders raised. The arm of the affected side is raised and so placed that the hand lies behind the nape of the neck.

In dealing with the right breast the surgeon faces the patient. In dealing with the left gland he faces towards the hip of the opposite side.

An elliptical incision is made, the dimensions, and especially the width, of which will depend upon the size of the mass to be removed. The centre of the ellipse will be about the nipple. The long axis of the ellipse will be parallel with the anterior fold of the axilla in the position in which the limb is fixed. The upper end of the incision will be opposite to the centre of the axilla on the pectoral side ; the lower end of the incision will be just beyond the mamma (Fig. 94).

In dealing with the right side the surgeon commences the incision over the axilla and cuts towards the chest.

In dealing with the left breast it is convenient to commence the incision at its lower part and cut towards the axilla.

The whole of the incision should be completed at once.

The knife should at first involve the skin and superficial tissues only, and should just pass down into the subcutaneous fat.

The assistant, who stands upon the opposite side of the table, now draws the skin up on the sternal side of the mamma towards the median line, while the surgeon lightly presses the breast downwards with his

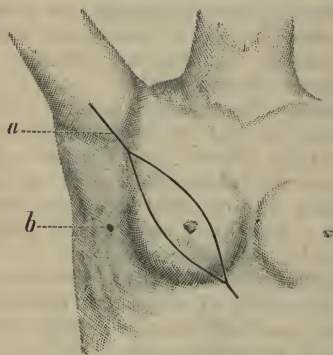


Fig. 94.—Excision of the Breast.  
*a*, Axillary incision; *b*, drainage opening.

left hand. While the parts are in this position the upper limb of the incision is carried down to the pectoral muscle.

The surgeon now grasps the mamma and drags it away from the thorax, while he severs its deep attachments in such a way as to lay bare the great pectoral muscle.

Nothing now remains but the attachments of the breast on the axillary side. The assistant should grasp the breast and draw it upwards and towards the middle line, while the surgeon retracts the skin in the

opposite direction. The inferior part of the incision is carried down to the thorax.

The breast is now only attached by the part just beyond the anterior fold of the axilla—*i.e.* on its axillary side. The surgeon, grasping the tumour in his left hand, drags it away from the thorax, while he rapidly severs the few remaining connections of the part. In this way the chief vessels going to the mamma are divided last.

The next step consists in the treatment of the axillary glands.

If any glands exist in the axilla, the incision should be continued upwards into the armpit, as shown in Fig. 94, *a*. But little cutting is required. The glands may be most conveniently removed with the fingers. Great care must be taken not to damage the axillary vein, and the nerves that cross the outlet of the axilla should also be preserved. The heroic evacuation of the axilla—which involves the laying bare of the whole of the axillary vein, the removal of the fatty tissue of the entire space, and the exposure of the upper ribs—has nothing to recommend it.

The great wound is now closed by sutures and dressed.

A special opening may be made for the drainage-tube. Its position is shown in Fig. 94, *b*.

[Faint paragraph of text]

[Faint paragraph of text]

[Faint paragraph of text]

[Faint paragraph of text]

[Faint paragraph of text]

[Faint paragraph of text]

[Faint paragraph of text]

[Faint paragraph of text]

[Faint paragraph of text]

[Faint paragraph of text]

[Faint paragraph of text]

# INDEX.

Abdomen, Operations on, 359  
Abdominal nephrectomy, 425  
— section, 359  
Abscess of brain, Trephining for,  
472  
—, psoas, Operation for, 478  
Allarton's operation (lithotomy),  
444  
Amputation, 84  
— *à la manchette*, 85  
—, Interscapulo-thoracic, 139  
—, Intracalcaneal, 172  
—, Methods of, 84  
—, Subastragaloid, 165  
—, Supracondyloid, of thigh,  
202  
—, Supramalleolar, 178  
— at ankle-joint, 169  
— at elbow-joint, 121  
— at hip-joint, 217  
— at knee-joint, 196  
— at metacarpo-phalangeal joint,  
97, 101  
— at metatarso-phalangeal joint,  
147  
— at metatarso-tarsal joint, 155  
— at shoulder-joint, 131  
— at wrist-joint, 110  
— by circular method, 84  
— by elliptical method, 86  
— by flap method, 87  
— by oval method, 86  
— by racket method, 86  
— by transfixion, 88  
— of arm, 126  
— of fingers, 93, 104

Amputation of foot, 155, 165, 169  
— of fore-arm, 116  
— of hand, 110  
— of leg, 178  
— of thigh, 202, 208  
— of thumb, 101, 104  
— of toes, 144, 155  
— of upper extremity with  
scapula and clavicle, 139  
Anastomosis of intestine, 387  
Anchylolysis of hip, osteotomy for,  
234  
Ankle, Excision of, 278  
— -joint, Amputation at, 169  
— —, Arthrectomy of, 293  
Anterior crural nerve, Operations  
on, 82  
Appendages, uterine, Removal of,  
369  
Appendix vermiformis, Removal of,  
385  
Arm, Amputation of, 126  
Arteries, Ligature of, 1  
Arthrectomy, 291  
Astragalus, Excision of, 275  
Axillary artery, Ligature of, 17

## B

Ball's operation for radical cure of  
hernia, 438  
Banks' operation for radical cure of  
hernia, 437  
Barker's excision of hip, 288  
— operation for radical cure of  
hernia, 438  
Battey's operation, 369

Bauden's amputation at knee-joint, 199  
 Berger's amputation of upper extremity, 139  
 Biceps, Tenotomy of, 312  
 Biliary calculus, Operations for, 412  
 Bladder, calculus of, Operations for, 440, 448  
 —, Operations upon, 440  
 —, tumours of, Operations for, 448  
 Boeckel's excision of wrist, 254  
 Bones, Operations on, 228  
 Bose's method of tracheotomy, 337  
 Bowels, Operations on, 379, 387, 392, 395  
 Brachial artery, Ligature of, 14  
 — plexus, Operations on, 76  
 Brain, abscess of, Trephining for, 472  
 —, tumour of, Trephining for, 473  
 Breast, Excision of, 485  
 Bronchocele, Excision of, 347

## C

Calcaneum, Excision of, 276  
 Calculus, biliary, Operations for, 412  
 — in bladder, Operations for, 440, 448  
 —, Renal, Operations for, 418  
 Carden's amputation of thigh, 202  
 Carotid, common, Ligature of, 26  
 —, external, Ligature of, 29  
 —, internal, Ligature of, 31  
 Castration, 457  
 Cerebral abscess, Trephining for, 472  
 — tumour, Trephining for, 473  
 Chest, Operations on, 481  
 —, Tapping, 481  
 Cholecystectomy, 413  
 Cholecystenterostomy, 414  
 Cholecystotomy, 412  
 Chopart's amputation of foot, 163

Circular method in amputation, 84  
 Clavicle, Excision of, 272  
 Cleft palate, Operations for, 322  
 Club-foot, Osteotomy for, 242  
 Coek's operation (urethrotomy), 453  
 Colotomy, Inguinal, 399  
 —, Lumbar, 395  
 Cranium, Operations on, 470  
 Crural nerve, Anterior, Operations on, 82  
 Crushing operation for piles, 463  
 Cuneiform osteotomy, 230  
 Cystotomy, Suprapubic, 445  
 Czerny's intestinal suture, 332

## D

Dental nerve, inferior, Operations on, 74  
 Dorsalis pedis artery, Ligature of, 38  
 Dubrueil's amputation at wrist-joint, 114  
 Dupuytren's intestinal suture, 379  
 Duval's supramalleolar amputation, 180

## E

Elbow, Excision of, 259  
 — joint, Amputation at, 121  
 Elliptical method in amputation, 86  
 Empyema, Operations for, 481  
 Enterectomy, 382  
 Enteroraphy, 379  
 Enterotomy, 392  
 Erasion of a joint, 291  
 Esmarch's amputation at hip-joint, 221  
 Estlander's operation, 432  
 Excision of ankle, 273  
 — of astragalus, 275  
 — of breast, 485  
 — of clavicle, 272  
 — of elbow, 259

Excision of eye-ball, 475  
 — of fingers, 248  
 — of hip, 286  
 — of jaw, lower, 299  
 — —, upper, 294  
 — of joints, 245  
 — of knee, 281  
 — of larynx, 343  
 — of metacarpus, 248  
 — of metatarsus, 275  
 — of nerves, 67  
 — of os calcis, 276  
 — of pylorus, 405  
 — of rectum, 467  
 — of ribs, 482  
 — of scapula, 273  
 — of shoulder, 267  
 — of spleen, 416  
 — of tarsus, 275  
 — of thumb, 248  
 — of thyroid body, 347  
 — of toes, 275  
 — of tongue, 350  
 — of varicocele, 455  
 — of wrist, 252  
 —, Subperiosteal method of, 247  
 Extensors of foot, Tenotomy of, 311  
 Eye-ball, Excision of, 475

## F

Facial artery, Ligature of, 36  
 — nerve, Operations on, 75  
 Farabeuf's amputation of leg, 188  
 Femoral artery, Ligature of, 51  
 — condyles, Amputation through, 202  
 — hernia, 435  
 Femur, Amputation through condyles of, 202  
 —, Osteotomy of, 234, 237  
 Finger-joints, Excision of, 248  
 Fingers, Amputation of, 91, 104  
 Fistula in ano, Operations for, 465  
 Flap method in amputation, 87  
 Foot, Amputation of, 169

Foot, Partial amputations of, 155, 165  
 Fore-arm, Amputation of, 116  
 Furneaux Jordan's amputation at hip-joint, 221

## G

Gall-bladder, Operations on, 412  
 Gastro-enterostomy, 391, 408  
 Gastrostomy, 401  
 Gastrotomy, 404  
 Genu valgum, Osteotomy for, 237  
 Giralès' operation for hare-lip, 319  
 Globe, Excision of, 475  
 Gluteal artery, Ligature of, 64  
 Great sciatic nerve, Operations on, 80  
 Gritti's amputation of thigh, 205  
 Gustatory nerve, Operations on, 75  
 Guyon's supramalleolar amputation, 179

## H

Hæmorrhoids, Operations on, 461  
 Hamstrings, Tenotomy of, 312  
 Hand, Amputation of, 110  
 Hare-lip, Operations for, 316  
 Hernia, Femoral, 435  
 —, Inguinal, 433  
 —, Radical cure of, 437  
 —, Strangulated, Operations for, 429  
 —, Umbilical, 435  
 Herniotomy, 429  
 Hey's amputation of foot, 162  
 — — of leg, 185  
 Hip, Excision of, 286  
 —-joint, Amputation at, 217  
 — —, Osteotomy for ankylosis of, 234  
 Hysterectomy, Supravaginal, 371  
 —, Vaginal, 375

## I

- Iliac artery, Ligature of common, 61  
 — — —, — of external, 57  
 — — —, — of internal, 63  
 — colotomy, 399  
 Inferior dental nerve, Operations on, 74  
 — maxillary nerve, Operations on, 72  
 Infraorbital nerve, Operations on, 70  
 Inguinal colotomy, 399  
 — hernia, 433  
 Internal saphenous nerve, Operations on, 82  
 Interscapulo-thoracic amputation, 139  
 Intestinal anastomosis, 387  
 Intestine, Operations on, 379, 387, 392, 395  
 —, Resection of, 382  
 —, Suture of, 379

## J

- Jaw, lower, Excision of, 299  
 —, upper, Excision of, 294  
 Joints, Excision of, 245

## K

- Kidney, movable, Suture of, 427  
 —, Operations on, 418  
 —, Removal of, 422  
 Knee, Excision of, 281  
 Knee-joint, Amputation at, 106  
 — — —, Arthrectomy of, 291  
 Kocher's method of excising tongue, 353

## L

- Langenbeck's excision of hip, 286  
 — — — of upper jaw, 298

- Langenbüch's incision in renal operations, 425  
 Laparotomy, 359  
 Larrey's amputation at the shoulder-joint, 135  
 Laryngotomy, 338  
 Larynx, Excision of, 343  
 Lateral lithotomy, 440  
 Leg, Amputation of, 178  
 Lembert's intestinal suture, 380  
 Ligature of anterior tibial artery, 38  
 — of arteries, 1  
 — of axillary artery, 17  
 — of brachial artery, 14  
 — of common carotid, 26  
 — of common iliac artery, 61  
 — of dorsalis pedis artery, 33  
 — of external carotid, 29  
 — of external iliac artery, 57  
 — of facial artery, 36  
 — of femoral artery, 51  
 — of gluteal artery, 64  
 — of inferior thyroid artery, 26  
 — of internal carotid, 31  
 — of internal iliac artery, 63  
 — of internal pudic artery, 65  
 — of lingual artery, 33  
 — of occipital artery, 37  
 — of peroneal artery, 57  
 — of popliteal artery, 47  
 — of posterior tibial artery, 43  
 — of radial artery, 7  
 — of sciatic artery, 65  
 — of subclavian artery, 21  
 — of superior thyroid artery, 32  
 — of temporal artery, 36  
 — of ulnar artery, 10  
 — of vertebral artery, 25  
 Lingual artery, Ligature of, 33  
 Lisfranc's amputation, 157  
 Lister's amputation of thigh, 204  
 — excision of wrist, 255  
 Lithotomy, Lateral, 440  
 —, Median, 444  
 —, Suprapubic, 448  
 Liver, Operations on, 412  
 Loreta's operation, 405



Lumbar colotomy, 395  
 — nephrectomy, 422

## M

Macewen's operation for radical cure of hernia, 439  
 — osteotomy for genu valgum, 239  
 Mamma, Excision of, 485  
 Maxilla, Excision of, 294  
 Meckel's ganglion, Removal of, 71  
 Median lithotomy, 444  
 — nerve, Operations on, 79  
 Metacarpus, Amputation of, 104  
 —, Excision of, 248  
 Mirault's operation for hare-lip, 318  
 Movable kidney, Suture of, 427  
 Musculo-spiral nerve, Operations on, 80

## N

Nephrectomy, 422  
 Nephro-lithotomy, 418  
 Nephroraphy, 427  
 Nephrotomy, 422  
 Nerves, Operations on, 67. (See under various Nerves.)  
 Neurectomy, 67  
 Neuroraphy, 67  
 Neurotomy, 67

## O

Occipital artery, Ligature of, 37  
 Oesophagotomy, 357  
 Ollier's excision of elbow, 264  
 — of wrist, 252  
 Oöphorectomy, 369  
 Os calcis, Excision of, 276  
 Osteotomy, 228  
 — for ankylosis of hip-joint, 234  
 — for club-foot, 242  
 — for genu valgum, 237

Oval method in amputation, 86  
 Ovariectomy, 365

## P

Palate, Operations for clefts of, 322  
 Pasquier's amputation of foot, 175  
 Penis, Amputation of, 459  
 Perineal section, 453  
 Perineum, Operations for rupture of, 328  
 Peroneal artery, Ligature of, 47  
 Peronei, Tenotomy of, 310  
 Perrin's subastragaloid amputation, 165  
 Phalanges, Excision of, 248, 275  
 — of foot, Amputation of, 144, 155  
 — of hand, Amputation of, 93, 104  
 Pharyngotomy, 340  
 Piles. (See Hæmorrhoids.)  
 Pirogoff's amputation of foot, 170  
 Plantar fascia, Division of, 307  
 Plexus, brachial, Operations on, 76  
 Pollock's amputation at knee-joint, 200  
 Popliteal artery, Ligature of, 47  
 — nerve, Operations on, 81, 82  
 Prostate, Operation on enlarged, 448  
 Prostatectomy, 448  
 Psoas abscess, Operation for, 478  
 Pudic artery, Ligature of, 65  
 Pylorectomy, 405  
 Pylorus, Dilatation of, 405  
 —, Resection of, 405

## R

Racket method in amputation, 86  
 Radial artery, Ligature of, 7  
 Radical cure of hernia, 437  
 Rectum, Excision of, 467  
 Regnoli's method of excising tongue, 355

Renal calculus, Operations for, 418  
 Resection. (*See* Excision.)  
 Ribs, Excision of, 482  
 Rupture, Operations for, 429  
 —, Radical cure of, 437  
 Ruptured perineum, Operations for, 328

## S

Saphenous nerve, Operations on, 82  
 Scapula, Excision of, 273  
 Schroeder's operation. (*See* Hysterectomy.)  
 Sciatic artery, Ligature of, 65  
 — nerve, Operations on, 80  
 Section, Abdominal, 359  
 Semi-membranosus, Tenotomy of, 313  
 Semi-tendinosus, Tenotomy of, 313  
 Senn's method of intestinal anastomosis, 387, 410  
 Shoulder, Excision of, 267  
 — joint, Amputation at, 131  
 Skull, Operations on, 470  
 Smith's, Stephen, amputation at knee-joint, 196  
 Spence's amputation at shoulder-joint, 132  
 Spinal abscess, Operation for, 478  
 — accessory nerve, Operations on, 77  
 — column, Operations on, 477  
 Spine, abscess of, Operation for, 478  
 —, Operations on, 477  
 Spleen, Extirpation of, 416  
 Splenectomy, 416  
 Staphyloraphy, 323  
 Stephen Smith's amputation at the knee-joint, 196  
 Sterno-mastoid, Tenotomy of, 313  
 Stomach, Operations on, 401  
 Stone in bladder, Operations for, 440, 448

Stone in kidney, Operations for, 418  
 Strangulated hernia, Operations for, 429  
 Subastragaloid amputation, 165  
 Subclavian artery, Ligature of, 21  
 Superior maxillary nerve, Operations on, 71  
 Supracondyloid amputation of thigh, 202  
 Supramalleolar amputation, 178  
 Supra-orbital nerve, Operations on, 70  
 Suprapubic cystotomy, 445  
 Suprathyroid laryngotomy, 340  
 Syme's amputation of foot, 169  
 — of thigh, 211  
 — operation (urethrotomy), 451  
 Syndesmotomy, 308

## T

Talipes, Osteotomy for, 242  
 Tarsectomy, 242  
 Tarsus, Amputation through, 163  
 —, Excision of, 275  
 Teale's amputation of leg, 182  
 Temporal artery, Ligature of, 36  
 Tendo Achillis, Tenotomy of, 309  
 Tenotomy, 304  
 Testicle, Excision of, 457  
 Thigh, Amputation of, 202, 208  
 Thoracoplasty, 482  
 Thoracotomy, 481  
 Thorax, Operations on, 481  
 Thumb, Amputation of, 101, 104  
 —, Excision of, 248  
 Thyroid arteries, Ligature of, 26, 32  
 — body, Excision of, 347  
 Thyrotomy, 341  
 Tibial arteries, Ligature of, 38, 43  
 Tibialis anticus, Tenotomy of, 305  
 — posticus, Tenotomy of, 305  
 Toes, Amputation of, 144, 155  
 —, Excision of, 275  
 Tongue, Excision of, 350

Tracheotomy, 334  
 Trephining, 470  
 Tri-facial nerve, Operations on,  
 70  
 Tripier's amputation of foot, 176

## U

Ulnar artery, Ligature of, 10  
 — nerve, Operations on, 79  
 Umbilical hernia, 435  
 Uppr extremity, Amputation of,  
 139  
 Uranoplasty, ~~225~~ 224  
 Urethrotony, 450  
 Uterine appendages, Removal of,  
 369  
 Uterus, Removal of, 371

## V

Varicocele, Operations on, 455  
 Velpeau's excision of upper jaw, 298  
 Vernale's amputation of thigh, 215  
 Vermiform appendix, Removal of,  
 385  
 Vertebral artery, Ligature of, 25

## W

Wheelhouse's operation (urethro-  
 tomy), 451  
 Whitehead's method of excising  
 tongue, 351  
 — operation for piles, 463  
 Wrist, Excision of, 252  
 — joint, Amputation at, 110

1. The first part of the document  
describes the general situation  
of the country at the time.

2. The second part of the document  
describes the specific details  
of the situation.

3. The third part of the document  
describes the results of the  
investigation.

4. The fourth part of the document  
describes the conclusions  
drawn from the investigation.

5. The fifth part of the document  
describes the recommendations  
made by the committee.

The first part of the document  
describes the general situation  
of the country at the time.

The second part of the document  
describes the specific details  
of the situation.

The third part of the document  
describes the results of the  
investigation.

The fourth part of the document  
describes the conclusions  
drawn from the investigation.

The fifth part of the document  
describes the recommendations  
made by the committee.

NOTICE.—"THE STUDENT'S HANDBOOK OF  
SURGICAL OPERATIONS," by FREDERICK TREVES,  
F.R.C.S. (price 7s. 6d.), is abridged from the large and  
exhaustive Work, entitled

# "A Manual of Operative Surgery,"

By FREDERICK TREVES, F.R.C.S.,

With 422 Illustrations by C. BERJEAU, produced under  
the superintendence of the Author.

*Two Volumes, each containing about 800 pages, Medium 8vo,*

**£2 2s.**

## CONTENTS.

GENERAL PRINCIPLES — ANÆSTHETICS — OPERATIONS UPON  
ARTERIES AND NERVES—AMPUTATIONS—EXCISIONS—  
OPERATIONS UPON BONES, JOINTS, AND TENDONS.

PLASTIC SURGERY—OPERATIONS UPON THE NECK AND ABDOMEN—  
OPERATIONS ON HERNIA—OPERATIONS UPON  
THE BLADDER, SCROTUM, PENIS, AND RECTUM  
—OPERATIONS UPON THE HEAD AND SPINE,  
THORAX AND BREAST.

"Only those who have attempted it are able fully to realise the  
difficulty of the task Mr. Treves set himself when he undertook to  
write a manual of operative surgery. The scope of such a work is  
Surgical Operations.]

very ill defined, and there are no rigid tests by which it can be limited. The literature of the subject is very extensive, the ways of accomplishing the same end are oftentimes very numerous, the small modifications introduced by individual surgeons are almost endless, and the force with which they appeal to others varies widely, while their true value often depends upon the peculiarities of a patient or even of the operator himself. What to choose from the mass of material is the writer's first great difficulty. . . . We must say that Mr. Treves' selection appears to us to have been very judicious. . . . The relative merits of different operations are sufficiently and aptly discussed. . . . The anatomy of organs and regions is given with all necessary detail, and, of course, with accuracy. . . . The majority of the illustrations are new and original, and they are admirable in design and execution—real helps to the reader. The feature of all others in this work which specially commends it, and in which it is in striking contrast to some manuals and text-books, is the pains Mr. Treves has taken to mention the work of other surgeons under their name. . . . 'This is a special and very praiseworthy feature of the book, and is the strongest evidence of the care taken in its preparation.'—*Lancet*.

"This is a practical manual dealing with the surgeon's work as a handicraft; it will therefore be welcomed all the more by the student. Had Mr. Treves entered into the various questions that surround operations he would not have been able to compress it into two volumes. The work is very well illustrated with original drawings, and the book is admirably printed."—*Provincial Medical Journal*.

"Mr. Treves is so well known as an able writer upon anatomical and surgical subjects that such a work as the present will be much sought after both by teachers and taught alike, and they will not be disappointed in expecting a clear and judicious exposition of the present position of operative surgery. The manual is not a mere text-book of operations on the dead body, but contains, in addition to the descriptions of the individual operations, a comment on the considerations which should weigh with the surgeon when deciding upon what procedure he will adopt. Further, a brief account of the details of the after-treatment is given, and each great division—as, for instance, "Amputation"—is introduced by a *résumé* of the general facts bearing upon the particular subject, such as the condition of the stump, the control of hæmorrhage, the general methods of amputating, etc. The regional arrangement adopted by some writers on the same subject is not followed by Mr. Treves, who has—wisely, we think—kept to the more usual plan of describing the various operations of a similar kind together; as, for example, ligature of arteries, excision of joints, osteotomy."—*Birmingham Medical Review*.

*Published by Cassell & Company.*

**Difficult Labour.** A Guide to its Management. For Students and Practitioners. By G. ERNEST HERMAN, M.B. Lond., F.R.C.P., Senior Obstetric Physician to the London Hospital; Physician to the General Lying-in Hospital, &c. &c. With 162 Illustrations. 12s. 6d.

**Tumours, Innocent and Malignant: Their Clinical Characters and Appropriate Treatment.** By J. BLAND SUTTON, F.R.C.S. With 250 Engravings, and 9 Plates. 21s.

**A Manual of Medical Treatment or Clinical Therapeutics.** By I. BURNEY YEO, M.D., F.R.C.P. With Illustrations. Two Vols. 21s.

**Operative Surgery, A Manual of.** By FREDERICK TREVES, F.R.C.S., Surgeon to, and Lecturer on Anatomy at, the London Hospital. With 422 Illustrations by C. BERJEAU. Two Volumes. £2 2s.

**A Manual of Surgery.** In Treatises by various Authors. Edited by FREDERICK TREVES, F.R.C.S. Fully Illustrated. Three Vols., 7s. 6d. each.  
"This Manual of Surgery is unique of its kind."  
*Medical Press and Circular.*

**Surgical Diseases of the Ovaries and Fallopian Tubes, including Tubal Pregnancy.** By J. BLAND SUTTON, F.R.C.S. With 118 Engravings and 5 Coloured Plates, 12s. 6d.

**The Student's Handbook of Surgical Operations.** By FREDERICK TREVES, F.R.C.S. With 94 Illustrations. (Abridged from the Author's "Manual of Operative Surgery.") 4th Thousand. 7s. 6d.

*Cassell & Company, Limited, Ludgate Hill, London.*

# MANUALS FOR Students of Medicine

Published by CASSELL & COMPANY.

Consisting of compact and authoritative Manuals embodying the most recent discoveries, and containing all the information required for the Medical Examinations of the various Colleges, Halls, and Universities in the United Kingdom and the Colonies.

The authors will be found to be either Examiners or the leading Teachers in well-known Medical Schools. This ensures the practical utility of the Series, while the introduction of the results of the latest scientific researches, British and Foreign, will recommend them also to Practitioners who desire to keep pace with the swift strides that are being made in Medicine and Surgery.

New and valuable Illustrations are freely introduced. The Manuals are printed in clear type, upon good paper. They are of a size convenient for the pocket, and bound in limp cloth.

---

**A Manual of Chemistry:** Inorganic and Organic, with an Introduction to the Study of Chemistry. For the Use of Students of Medicine. By ARTHUR P. LUFF, M.D., B.Sc. (Lond.), M.R.C.P.; Fellow of the Institute of Chemistry, &c. &c. With numerous Engravings, 7s. 6d.

"The author is evidently a master of his subject, and the work is one which may be confidently recommended to the student of chemistry."—*Hospital Gazette*.

**First Lines in Midwifery.** A Guide to Attendance on Natural Labour. By G. E. HERMAN, M.B. Lond., F.R.C.P., F.R.C.S., Obstetric Physician and Lecturer on Midwifery, London Hospital. 5s.

"This manual is of considerable merit, and is likely to prove highly popular in London schools and lying-in hospitals."—*British Medical Journal*.

**Hygiene and Public Health.** By B. ARTHUR WHITELEGGE, M.D., B.Sc. Lond., D.P.H. Camb., Medical Officer of Health to the West Riding County Council. With 23 Illustrations. 7s. 6d.

"It is in every way perfectly reliable and in accordance with the most recently acquired knowledge."—*British Medical Journal*.

**Elements of Histology.** By E. KLEIN, M.D., F.R.S., Lecturer on General Anatomy and Physiology in the Medical School of St. Bartholomew's Hospital, London. *New and Enlarged Edition*, 7s. 6d.

"A work which must of necessity command a universal success. It is just exactly what has long been a desideratum among students."—*Medical Press and Circular*.



## Manuals for Students of Medicine (*continued*).

**Surgical Pathology.** By A. J. PEPPER, M.S., M.B.,  
F.R.C.S., Surgeon and Teacher of Practical Surgery at St. Mary's  
Hospital. *7s. 6d.*

"A student engaged in surgical work will find Mr. Pepper's 'Surgical Pathology' to be an invaluable guide, leading him on to that correct comprehension of the duties of a practical and scientific surgeon which is the groundwork of the highest type of British surgery."—*British Medical Journal*.

**Surgical Applied Anatomy.** By FREDERICK TREVES,  
F.R.C.S., Surgeon to, and Lecturer on Anatomy at, the London  
Hospital. *New and Extended Edition. 7s. 6d.*

"The author of 'Surgical Applied Anatomy' is an able writer, and is also an authority on purely anatomical questions. There are excellent paragraphs on the anatomy of certain well-known surgical affections, such as hip-joint diseases, constituting a feature quite original in a work of this class, yet in no way beyond its proper scope."—*London Medical Recorder*.

**Clinical Chemistry.** By CHARLES H. RALFE, M.D.,  
F.R.C.P., Physician at the London Hospital. *5s.*

"The volume deals with a subject of great and increasing importance, which does not generally receive so much attention from students as it deserves. The text is concise and lucid, the chemical processes are stated in chemical formulae, and wherever they could aid the reader suitable illustrations have been introduced."—*The Lancet*.

**Human Physiology.** By HENRY POWER, M.B.,  
F.R.C.S., late Examiner in Physiology, Royal College of Surgeons  
of England. *New and Enlarged Edition. 7s. 6d.*

"The author has brought to the elucidation of his subject the knowledge gained by many years of teaching and examining, and has communicated his thoughts in easy, clear, and forcible language, so that the work is entirely brought within the compass of every student. It supplies a want that has long been felt."—*The Lancet*.

**Materia Medica and Therapeutics.** By J.  
MITCHELL BRUCE, M.D., F.R.C.P., Lecturer on Materia Medica at  
Charing Cross Medical School, and Physician to the Hospital.  
A full account of the many important drugs contained in the  
Addendum to the British Pharmacopœia, recently issued, will be  
found in the New Edition. *7s. 6d.*

"We welcome its appearance with much pleasure, and feel sure that it will be received on all sides with that favour which it richly deserves."—*British Medical Journal*.

**Physiological Physics.** By J. MCGREGOR-ROBERTSON,  
M.A., M.B., Muirhead Demonstrator of Physiology, University of  
Glasgow. *7s. 6d.*

"Mr. McGregor-Robertson has done the student the greatest service in collecting together in a handy volume descriptions of the experiments usually performed, and of the apparatus concerned in performing them."—*The Lancet*.

**Surgical Diagnosis: A Manual for the Wards.**  
By A. PEARCE GOULD, M.S., M.B., F.R.C.S., Assistant Surgeon to  
Middlesex Hospital. *7s. 6d.*

"We do not hesitate to say that Mr. Gould's work is unique in its excellence."—*The Lancet*.

**Comparative Anatomy and Physiology.** By F.  
JEFFREY BELL, M.A., Professor of Comparative Anatomy at King's  
College. *7s. 6d.*

"The book has evidently been prepared with very great care and accuracy, and is well up to date. The woodcuts are abundant and good."—*Athenæum*.

*Cassell & Company, Limited, Ludgate Hill, London.*

# CLINICAL MANUALS

FOR

*Practitioners and Students of Medicine.*

Complete Monographs on Special Subjects.

"A valuable series, which is likely to form, when completed, perhaps the most important Encyclopædia of Medicine and Surgery in the English language."—*British Medical Journal*.

***Diseases of the Skin.*** An Outline of the Principles and Practice of Dermatology. By MALCOLM MORRIS, F.R.C.S., Ed., Surgeon to the Skin Department, St. Mary's Hospital, London. With Coloured Plates. 10s. 6d.

***On Gall-Stones and Their Treatment.*** By A. W. MAYO ROBSON, F.R.C.S., Professor of Surgery in the Yorkshire College of the Victoria University, &c. &c. Illustrated. 8s. 6d.

"There can be no question that this book well repays perusal, and will be the work to which all practitioners and students will turn for information on the surgery of the gall bladder."—*Provincial Medical Journal*.

***Food in Health and Disease.*** By I. BURNEY YEO, M.D., F.R.C.P., Physician to King's College Hospital, and Professor of Clinical Therapeutics, King's College. 9s.

"We think that Dr. Yeo is to be congratulated on having accomplished his desire; we became more and more favourably impressed with the work as we went through the various chapters, and we have no doubt that it will attain, as it deserves, a great success."—*The Lancet*.

***The Pulse.*** By W. H. BROADBENT, M.D., F.R.C.P., Senior Physician to, and Lecturer on Clinical Medicine at, St. Mary's Hospital. 9s.

"There is so much that is interesting and well done, that it is hard to emphasise any."—*Hospital*.

***Ophthalmic Surgery.*** By R. BRUDENELL CARTER, F.R.C.S., Ophthalmic Surgeon to and Lecturer on Ophthalmic Surgery at, St. George's Hospital; and W. ADAMS FROST, F.R.C.S., Assistant Ophthalmic Surgeon to, and Joint-Lecturer on Ophthalmic Surgery at, St. George's Hospital. With Chromo Frontispiece. 9s.

"Its clearness and conciseness will cause it to be welcomed by students and young practitioners as an agreeable and useful guide to the modern practice of eye diseases."—*British Medical Journal*.

***Diseases of the Joints.*** By HOWARD MARSH, F.R.C.S., Senior Assistant Surgeon to, and Lecturer on Anatomy at, St. Bartholomew's Hospital, and Surgeon to the Children's Hospital, Great Ormond Street. 9s.

"This volume is excellently planned. Mr. Marsh brings to bear upon it keen critical acumen."—*Liverpool Medico-Chirurgical Journal*.

***Diseases of the Rectum and Anus.*** By CHARLES B. BALL, M.Ch. (Dublin), F.R.C.S.I., Surgeon and Clinical Teacher at Sir P. Dun's Hospital. With Chromo Plates. *New Edition*. 9s.

"As a full, clear, and trustworthy description of the diseases which it deals with, it is certainly second to none in the language. The author is evidently well read in the literature of the subject, and has nowhere failed to describe what is best up to date. The model of what such a work should be."—*Bristol Medico-Chirurgical Journal*.

List of Clinical Manuals (*continued*).

**Diseases of the Breast.** By THOMAS BRYANT, F.R.C.S., Surgeon to, and Lecturer on Surgery at, Guy's Hospital. With 8 Chromo Plates. 9s.

"Mr. Bryant is so well known, both as an author and a surgeon, that we are absolved from the necessity of speaking fully or critically of his work."—*The Lancet*.

**Syphilis.** By JONATHAN HUTCHINSON, F.R.S., F.R.C.S., Consulting Surgeon to the London Hospital and to the Royal London Ophthalmic Hospital. With 8 Chromo Plates. 9s.

"The student, no matter what may be his age, will find in this compact treatise a valuable presentation of a vastly important subject. We know of no better or more comprehensive treatise on syphilis."—*Medical News, Philadelphia*.

**Fractures and Dislocations.** By T. PICKERING PICK, F.R.C.S., Surgeon to, and Lecturer on Surgery at, St. George's Hospital. 8s. 6d.

"We must express the pleasure with which we have perused the book, and our especial admiration for the lucidity of the author's style, and the simplicity of his directions for the application of apparatus; in the latter respect it is always difficult to combine clearness with brevity, but herein Mr. Pick has been most successful."—*Glasgow Medical Journal*.

**Surgical Diseases of the Kidney.** By HENRY MORRIS, M.B., F.R.C.S., Surgeon to, and Lecturer on Surgery at, Middlesex Hospital. With 6 Chromo Plates. 9s.

"It would be difficult to find these subjects treated more carefully and thoroughly."—*British Medical Journal*.

**Insanity and Allied Neuroses.** By GEORGE H. SAVAGE, M.D., Medical Superintendent and Resident Physician to Bethlem Royal Hospital, and Lecturer on Mental Diseases at Guy's Hospital. 8s. 6d.

"Dr. Savage's grouping of insanity is practical and convenient, and the observations in each group are acute, extensive, and well arranged."—*The Lancet*.

**Intestinal Obstruction.** By FREDERICK TREVES, F.R.C.S., Surgeon to, and Lecturer on Anatomy at, the London Hospital. 8s. 6d.

"Throughout the work there is abundant evidence of patient labour, acute observation, and sound reasoning, and we believe Mr. Treves's book will do much to advance our knowledge of a very difficult subject."—*The Lancet*.

**Diseases of the Tongue.** By H. T. BUTLIN, F.R.C.S., Assistant Surgeon to St. Bartholomew's Hospital. With 8 Chromo Plates. 9s.

"Mr. Butlin may be congratulated upon having written an excellent manual, scientific in tone, practical in aim, and elegant in literary form. The coloured plates rival, if not excel, some of the most careful specimens of art to be found in the pages of European medical publications."—*British Medical Journal*.

**Surgical Diseases of Children.** By EDMUND OWEN, M.B., F.R.C.S., Senior Surgeon to the Children's Hospital, Great Ormond Street, and Surgeon to, and Co-Lecturer on Surgery at, St. Mary's Hospital. With 4 Chromo Plates. 9s.

"Mr. Owen's volume will rank as an invaluable *résumé* of the subject on which he treats, and should readily take its place as a reliable and compact guide to the surgery of children."—*Medical Press and Circular*.

Cassell & Company, Limited, Ludgate Hill, London.

**The Treatment of Typhoid Fever, Especially by "Antiseptic" Remedies.** By I. BURNEY YEO, M.D., F.R.C.P., Professor of Clinical Therapeutics in King's College, London, and Physician to the Hospital. 1s. 6d.

**Medical Handbook of Life Assurance.** For the use of Medical and other Officers of Companies. By JAMES EDWARD POLLOCK, M.D., F.R.C.P. (Consulting Physician to the Hospital for Consumption and Diseases of the Chest, Brompton); and JAMES CHISHOLM (Fellow of the Institute of Actuaries, London, and of the Faculty of Actuaries, Scotland). 7s. 6d.

**An Address in School Hygiene.** By CLEMENT DUKES, M.D. Lond., M.R.C.P. Lond. Demy 8vo. 1s.

**Vaccination Vindicated:** Being an Answer to the Leading Anti-Vaccinators. By JOHN C. McVAIL, M.D., D.P.H. Camb.; Physician to the Kilmarnock Infirmary; Medical Officer of Health, Kilmarnock; President of the Sanitary Association of Scotland, &c. 5s.

**The Natural History of Cow-Pox and Vaccinal Syphilis.** By CHARLES CREIGHTON, M.D. 3s.

**Advice to Women on the Care of their Health, Before, During, and After Confinement** By FLORENCE STACPOOLE, Diplômée of the London Obstetrical Society, &c. &c. Paper covers, 1s. ; or cloth, 1s. 6d.

**Our Sick, and How to Take Care of Them; or, Plain Teaching on Sick Nursing at Home.** By FLORENCE STACPOOLE. Paper covers, 1s. ; or cloth, 1s. 6d.

**A Handbook of Nursing** for the Home and for the Hospital. By CATHERINE J. WOOD, Lady Superintendent of the Hospital for Sick Children, Great Ormond Street. Tenth and Cheap Edition. 1s. 6d. ; cloth, 2s.

**A Handbook for the Nursing of Sick Children.** With a few Hints on their Management. By CATHERINE J. WOOD. 2s. 6d.

*Cassell & Company, Limited, Ludgate Hill, London.*

*Authoritative Work on Health by Eminent Physicians  
and Surgeons.*

# The Book of Health.

A Systematic Treatise for the Professional and General Reader  
upon the Science and the Preservation of Health . **21s.**

Roxburgh . . . . . **25s.**

## CONTENTS.

- |  |  |
|--|--|
| By SIR W. S. SAVORY, BART.,<br>F.R.S.—INTRODUCTORY.  | By SHIRLEY MURPHY,<br>M.R.C.S.—HEALTH AT HOME.                                       |
| By SIR RISDON BENNETT,<br>M.D., F.R.S.—FOOD AND ITS<br>USE IN HEALTH.                            | By W. B. CHEADLE, M.D.—<br>HEALTH IN INFANCY AND<br>CHILDHOOD.                       |
| By T. LAUDER BRUNTON,<br>M.D., F.R.S.—THE INFLUENCE<br>OF STIMULANTS AND NARCOTICS<br>ON HEALTH. | By CLEMENT DUKES, M.D.—<br>HEALTH AT SCHOOL.   |
| By SIR J. CRICHTON-BROWNE,<br>LL.D., M.D.—EDUCATION AND<br>THE NERVOUS SYSTEM.                   | By HENRY POWER, F.R.C.S.—<br>—THE EYE AND SIGHT.                                     |
| By JAMES CANTLIE, F.R.C.S.—<br>—THE INFLUENCE OF EXER-<br>CISE ON HEALTH.                        | By G. P. FIELD, M.R.C.S.—THE<br>EAR AND HEARING.                                     |
| By FREDERICK TREVES,<br>F.R.C.S.—THE INFLUENCE OF<br>DRESS ON HEALTH.                            | By J. S. BRISTOWE, M.D., F.R.S.—<br>—THE THROAT AND VOICE.                           |
| By J. E. POLLOCK, M.D.—THE<br>INFLUENCE OF OUR SURROUND-<br>INGS ON HEALTH.                      | By CHARLES S. TOMES, F.R.S.—<br>—THE TEETH.  |
| By J. RUSSELL REYNOLDS,<br>M.D., F.R.S.—THE INFLUENCE<br>OF TRAVELLING ON HEALTH.                | By MALCOLM MORRIS.—THE<br>SKIN AND HAIR.   |
|  | By SIR JOSEPH FAYRER,<br>K.C.S.I., F.R.S., and J.<br>EWART, M.D.—HEALTH IN<br>INDIA. |
|  | By HERMANN WEBER, M.D.—<br>—CLIMATE AND HEALTH RE-<br>SORTS.                         |

Edited by MALCOLM MORRIS, F.R.C.S. Ed.

“The Book of Health,” says the *Lancet*, “is what it aims to be—authoritative, and must become a *standard work of reference* not only with those who are responsible for the health of schools, workshops, and other establishments where there is a large concourse of individuals, but to *every member of the community* who is anxious to secure the highest possible degree of healthy living for himself and for his family.”

---

CASELL & COMPANY'S COMPLETE CATALOGUE, containing  
*particulars of upwards of One Thousand Volumes, including  
Bibles and Religious Works, Illustrated and Fine-Art Volumes,  
Children's Books, Dictionaries, Educational Works, History,  
Natural History, Household and Domestic Treatises, Science,  
Travels, &c., together with a Synopsis of their numerous  
Illustrated Serial Publications, sent post free on application.*

CASELL & COMPANY, LIMITED, Ludgate Hill, London;  
Paris & Melbourne.

ENLARGED SERIES, in MONTHLY PARTS,  
price 2s., of the

# ANNALS OF SURGERY:

A Monthly Review of Surgical Science and Practice.

EDITED BY

Frederick Treves, F.R.C.S.  
(Of London);

William MacEwen, M.D.  
(Of Glasgow);

L. S. Pilcher, A.M., M.D.  
(Of Brooklyn, U.S.A.);

J. William White, M.D.  
(Of Philadelphia, U.S.A.).

---

No introduction is needed to commend the ENLARGED SERIES of this well-known Journal to British practitioners of surgery.

It is already highly esteemed in this country on account of the invaluable contributions which appear in its pages, and the fact that the Journal will be considerably enlarged will secure for it an enhanced appreciation amongst medical men.

“Annals of Surgery” is the only high-class Journal published in the English language, devoted exclusively to presenting current work in the science and art of surgery.


The names of its Editors are a sufficient guarantee for the sterling character of its contents. The high standard which has been attained in the past will be fully maintained in the future, and the Journal in its new form should command the support of all those to whom it appeals.


The several departments of *Original Memoirs*, *Editorial Articles*, *Index of Surgical Progress*, and *Reviews of Books* will be retained, and each will be developed and extended as may be required to keep the Journal abreast with current surgical work.

A subscription of One Guinea, paid in advance, will secure the Journal being sent post free for one year.

\* \* \* Also issued in half-yearly volumes, price 15s.

Cassell & Company, Limited, Ludgate Hill, London.







MS  
T

353911

Treves, (Sir) Frederick

The student's handbook of surgical operations.

**University of Toronto  
Library**

**DO NOT  
REMOVE  
THE  
CARD  
FROM  
THIS  
POCKET**

Acme Library Card Pocket  
LOWE-MARTIN CO. LIMITED

